


MICOD -02/09/2023

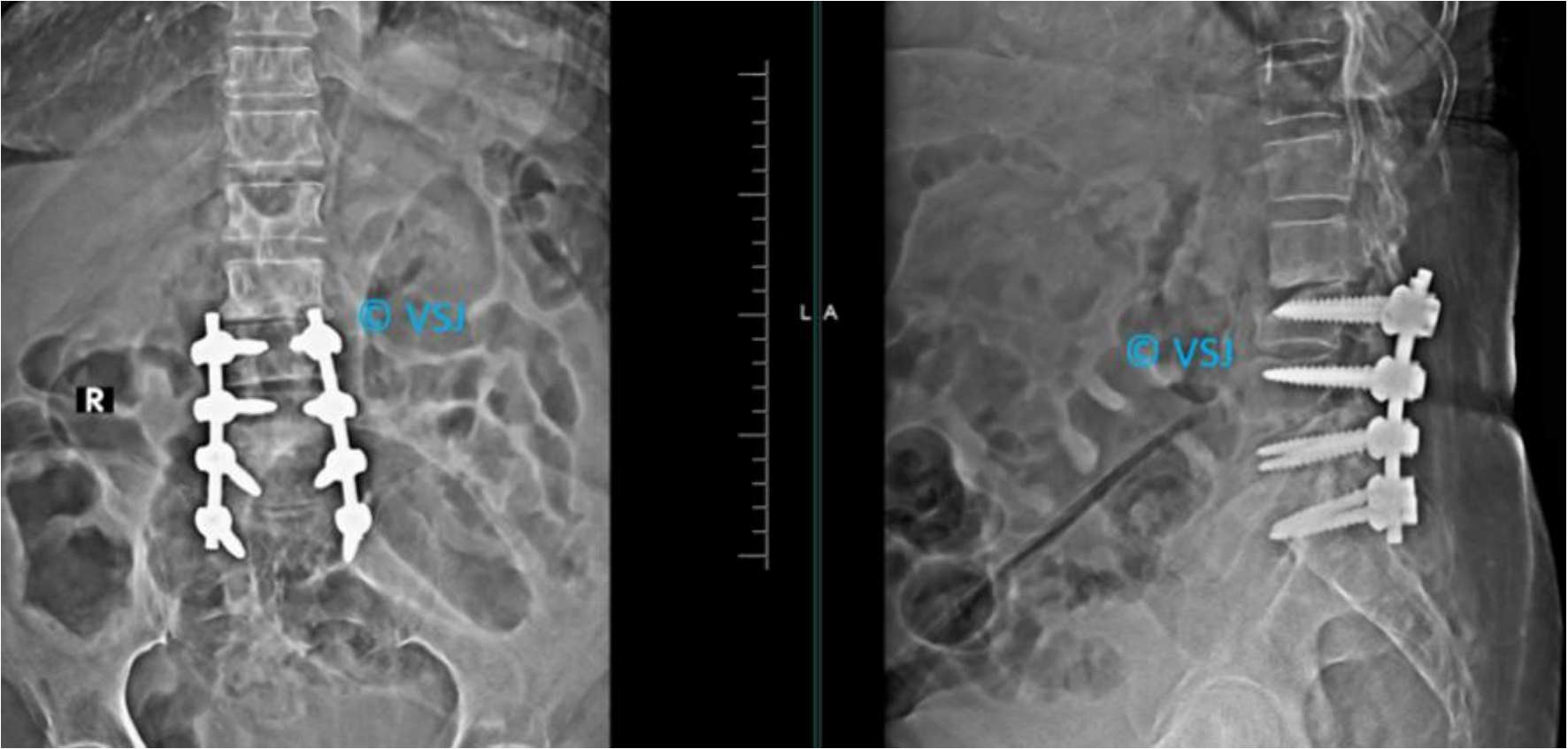
Case contributor – Dr.Vardhan Joshi

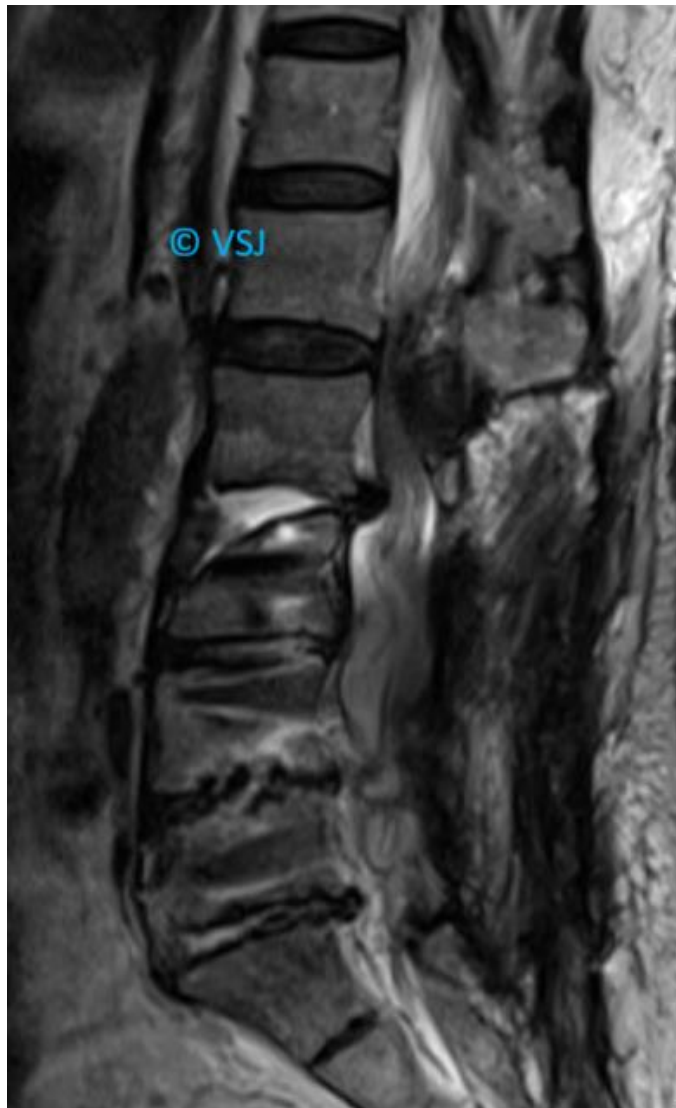
MI-COD

MSS INDIA- Case Of the Day

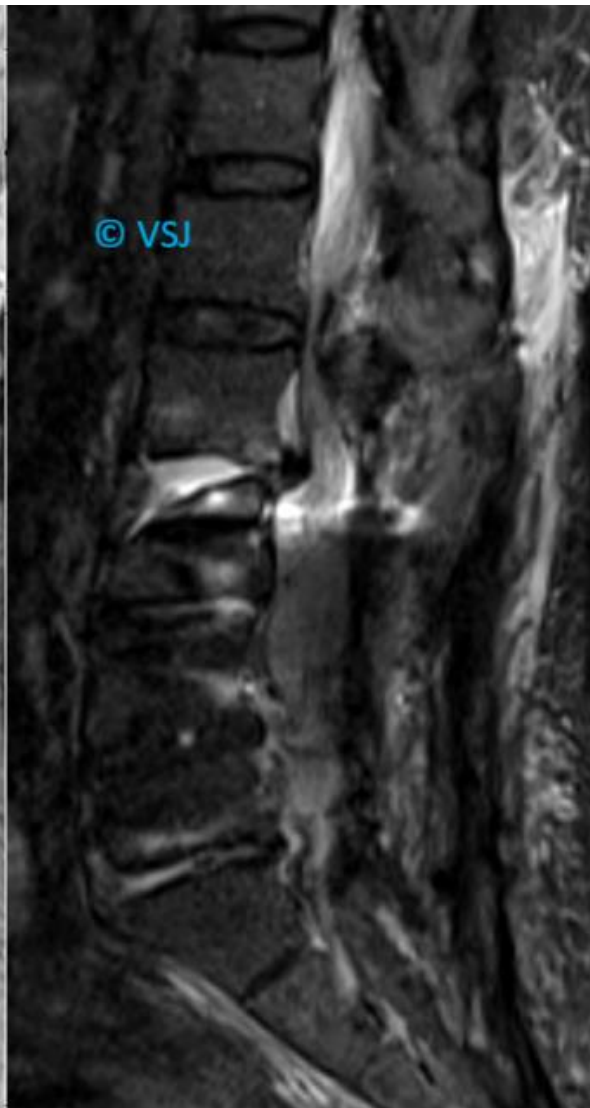


79-year-old lady, Operated 1yrs ago, presented with gradual worsening of pain with lower limb weakness no fever.

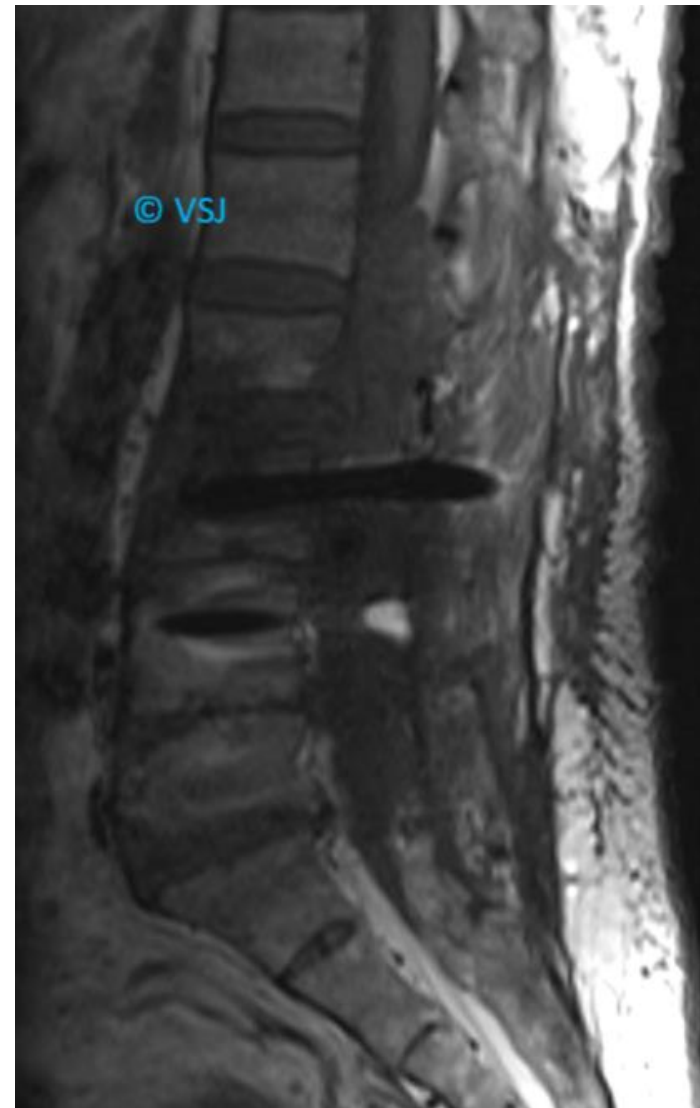




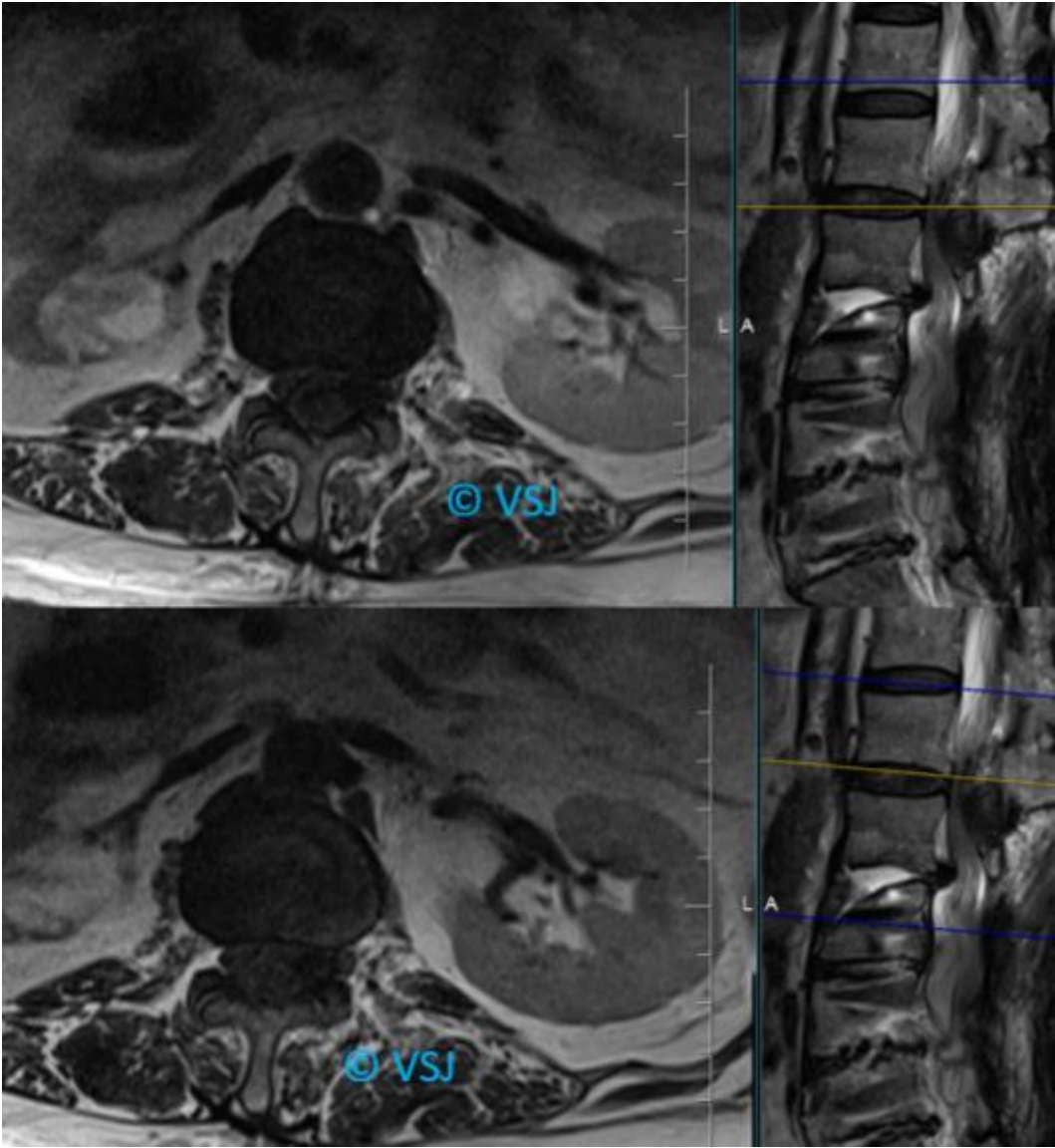
T2W



STIR



T1W



The treating team of surgeons and physicians was not comfortable with the contrast study due to deranged creatinine and comorbidities

