

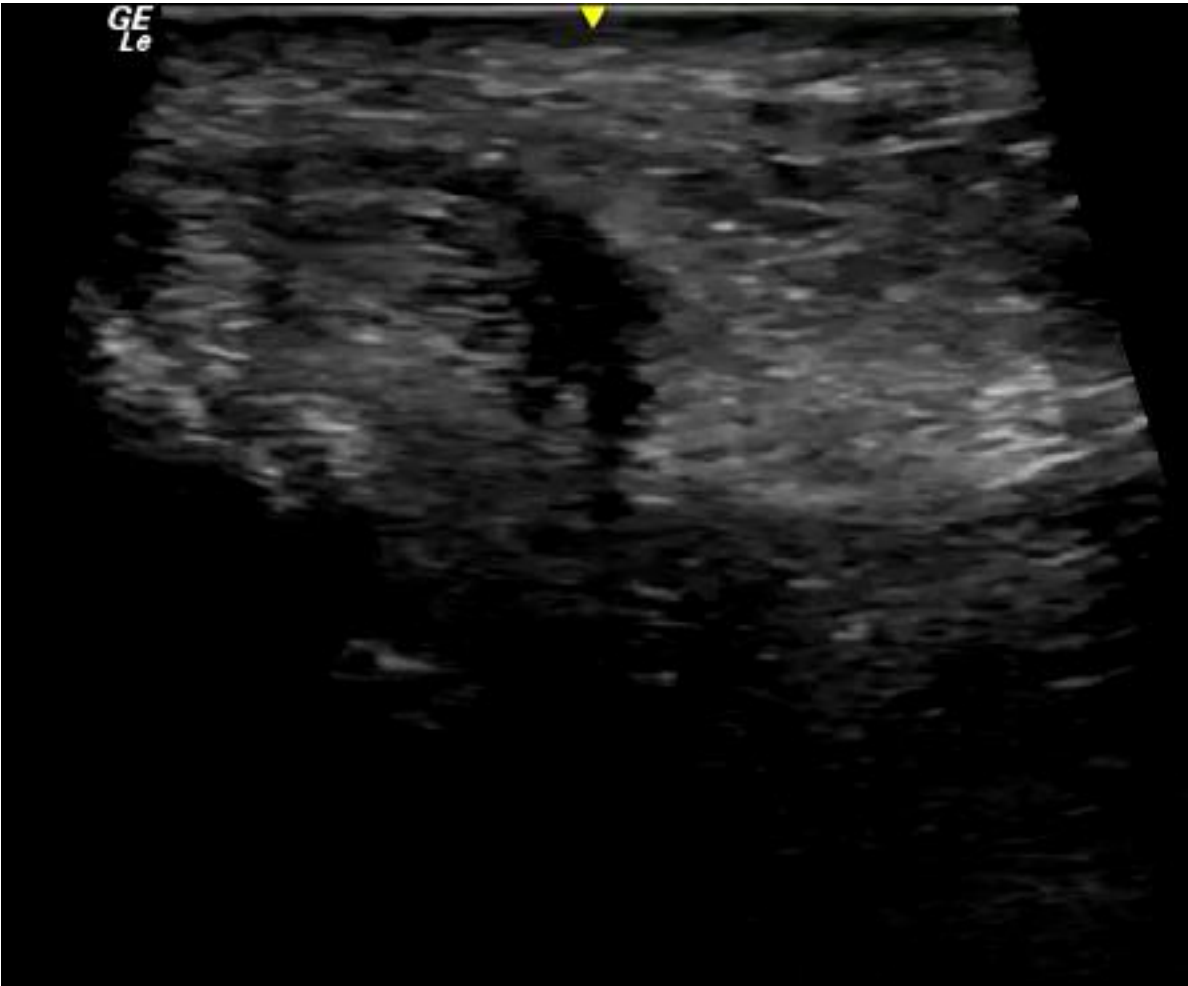
**MICOD 30/09/2023**  
**Case Courtesy: Dr. Joban Babhulkar**



30 y/o man, football injury 3  
months ago.

Persistent lateral ankle pain

# Short axis scan thru retromalleolar groove



# Questions

- What is the type of injury to peroneal tendons ?
- Is it the superior or inferior peroneal retinaculum ?
- What is the movement performed at the ankle to elicit this diagnosis?