

MICOD -01/09/2023

Case contributor – **Dr.Raj Chari**

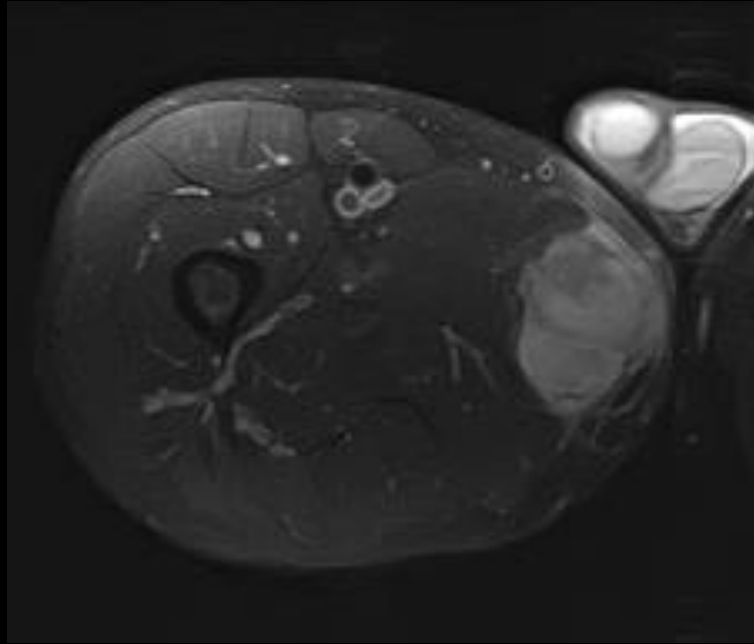
MI-COD

MSS INDIA- Case Of the Day

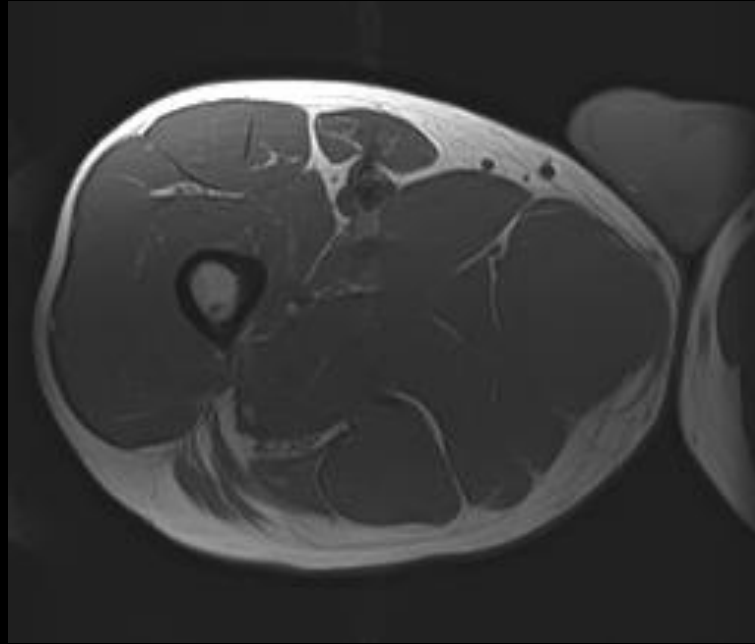


Clinical details

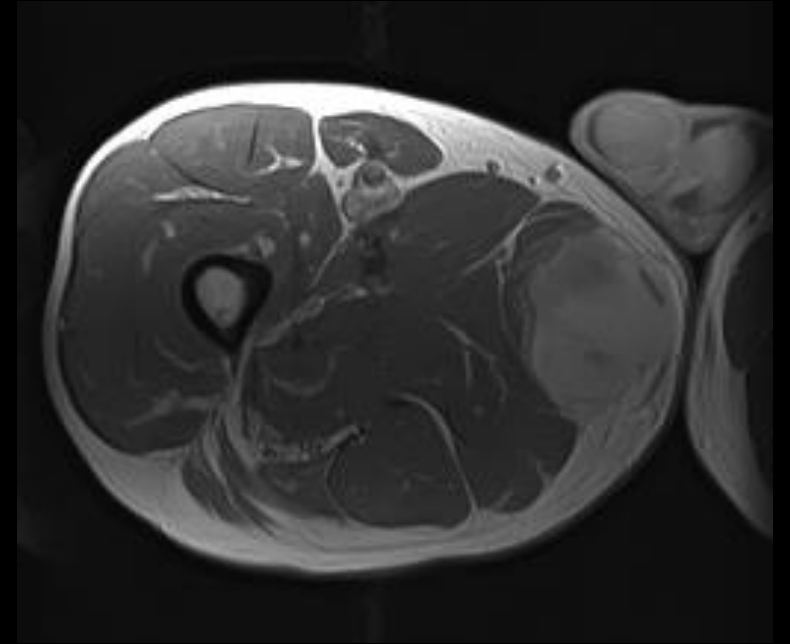
- 40 year old gentleman
- Right medial thigh swelling
- Underwent appropriate investigations



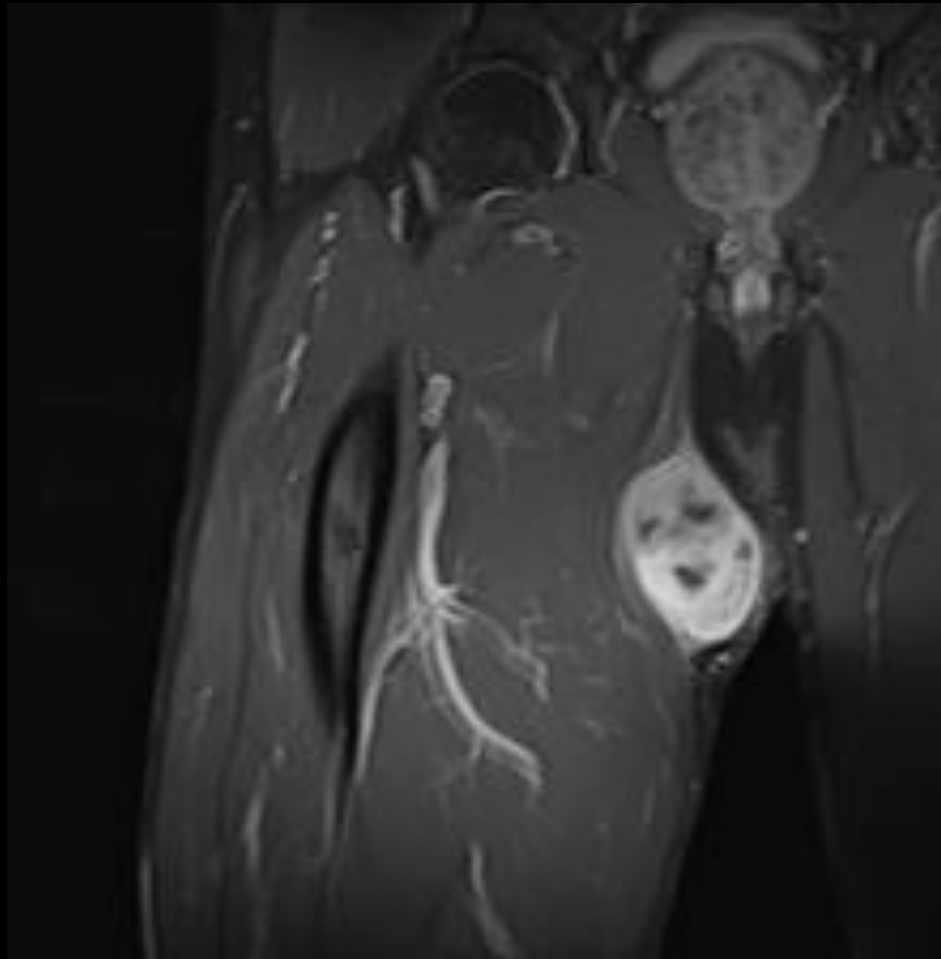
T2FS



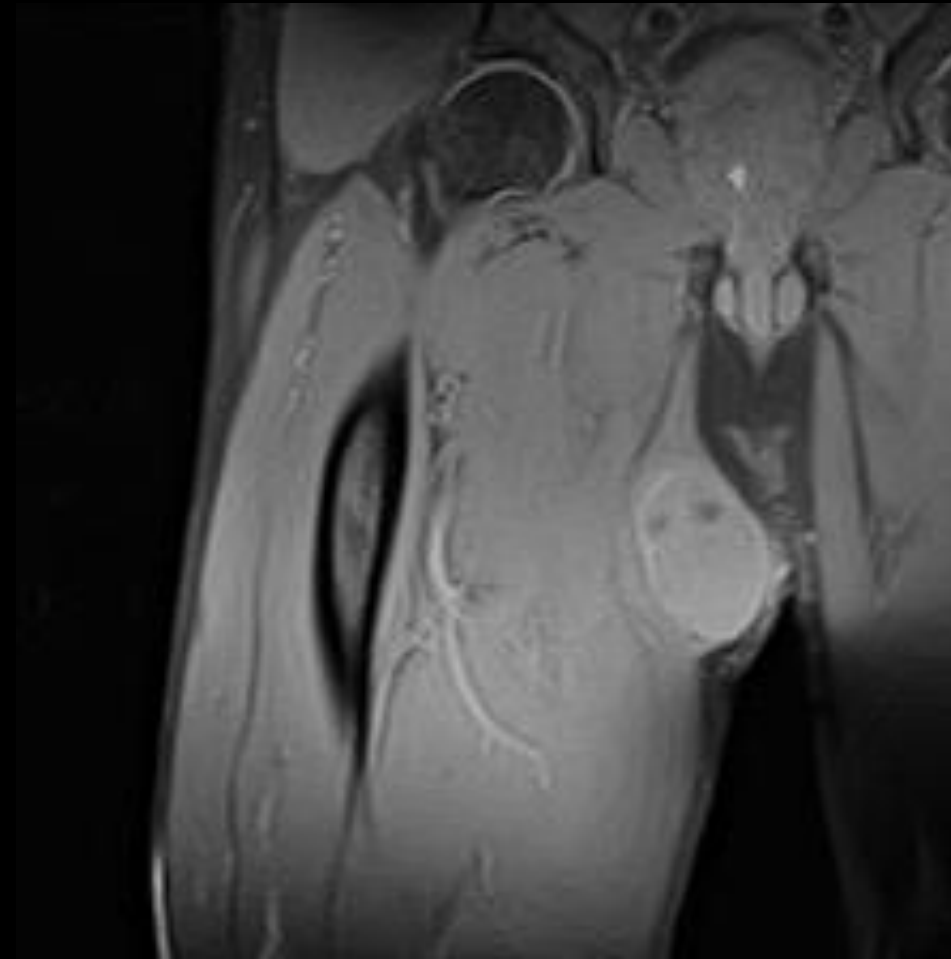
T1



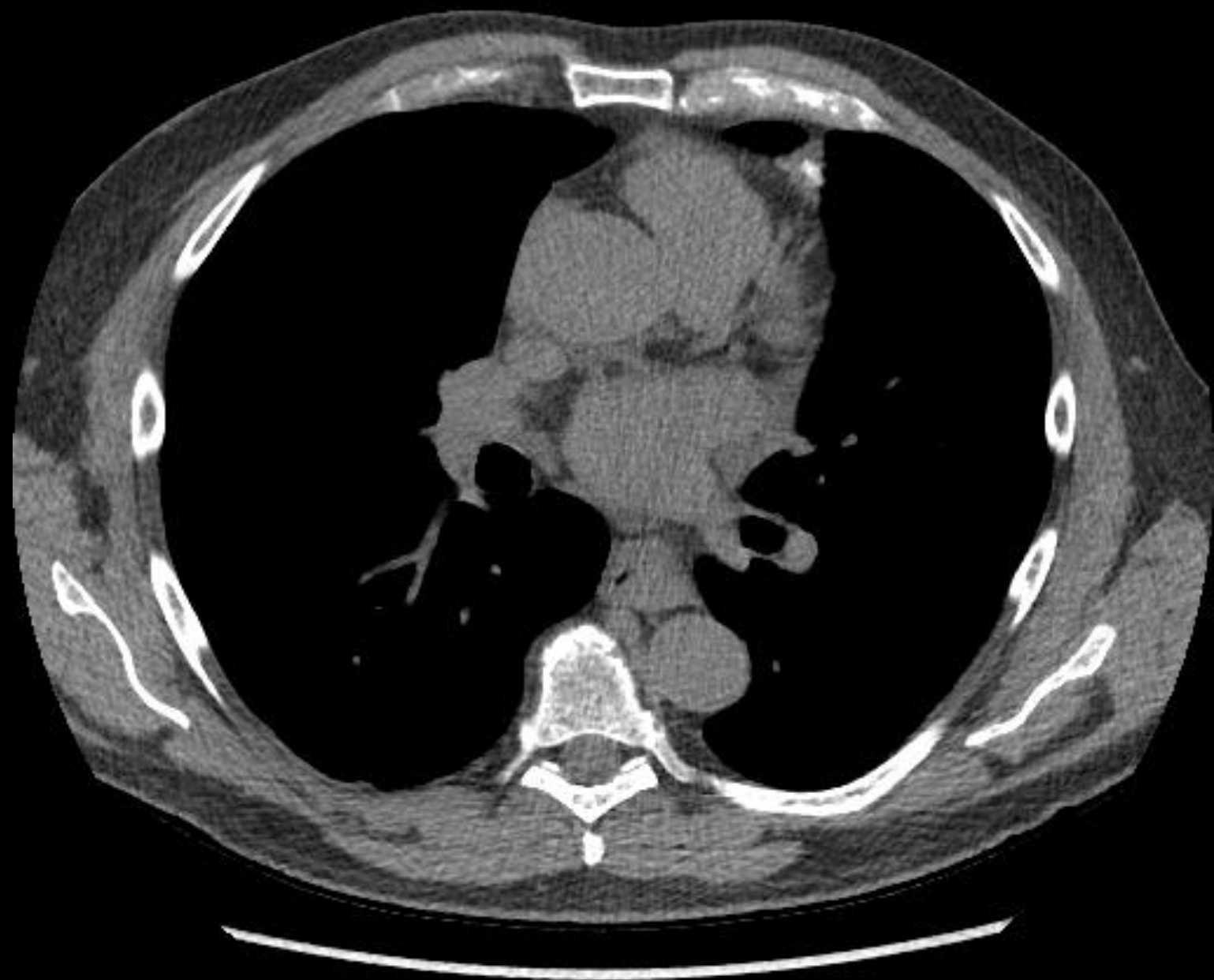
T1 post contrast



T2FS



T1 post contrast



Question

- What is the diagnosis?
- What is the management?

PS: I am having an extramarital affair with gracilis and I keep the matter close to my heart!