

MI-COD

MSS INDIA- Case Of the Day



05/11/2024

Case contributor – Dr. Sagar Tomar

Musculoskeletal Society of India (MSS) &
Indian Journal of Musculoskeletal Radiology
(IJMSR), the official publication of MSS India

For MICOD case archives visit <https://www.indianmss.org/>

Check out our latest publication at <https://mss-ijmsr.com/>

Authentic source of MSK Radiology

For daily MSK radiology updates & great educational
contents, follow us on



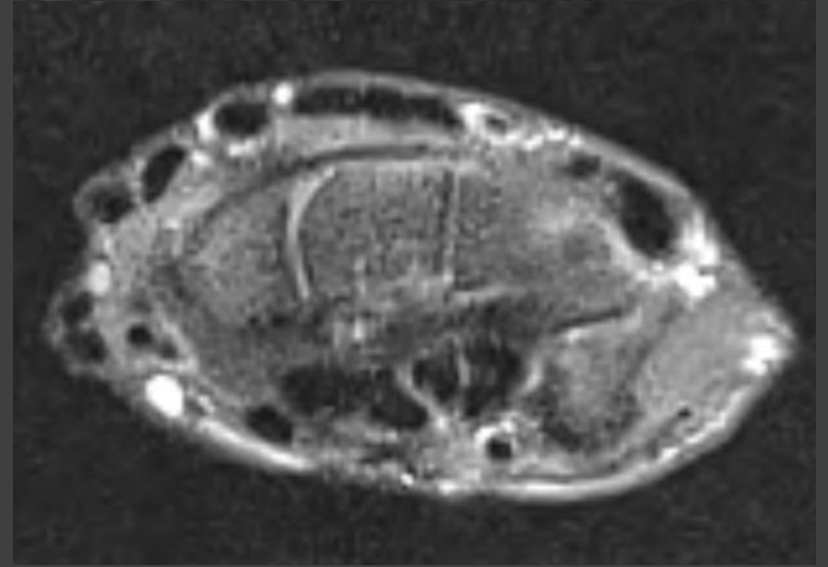
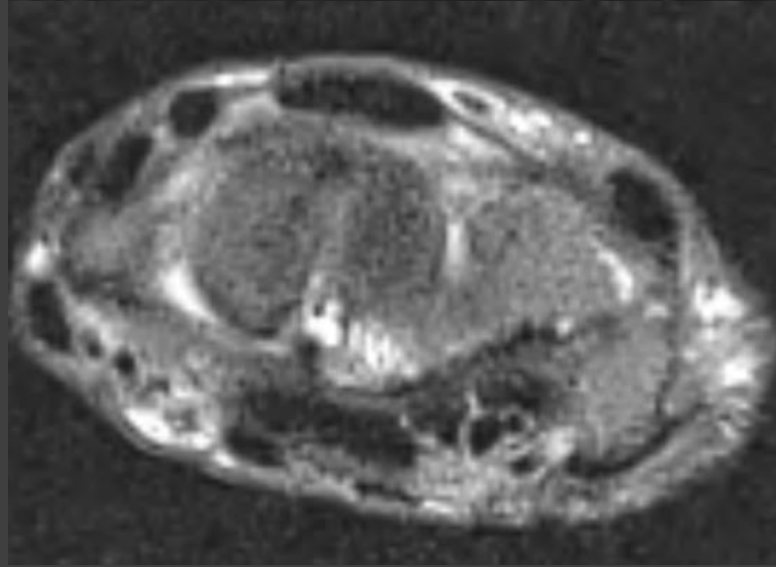
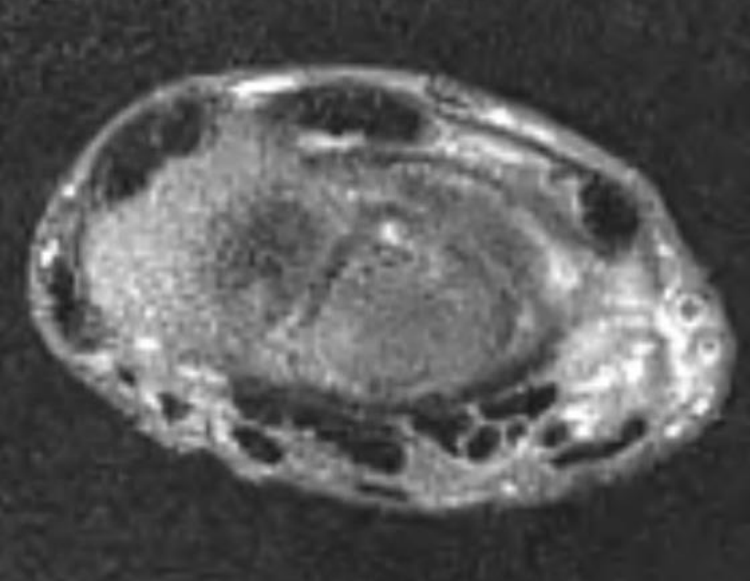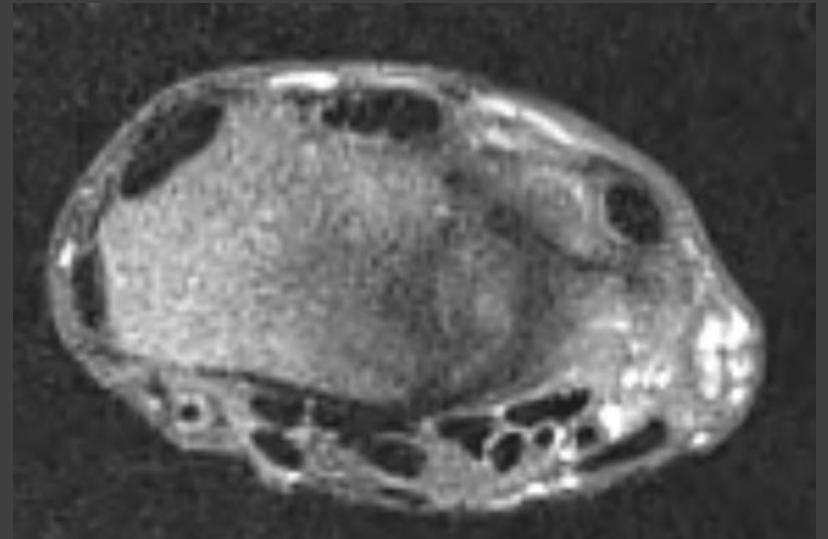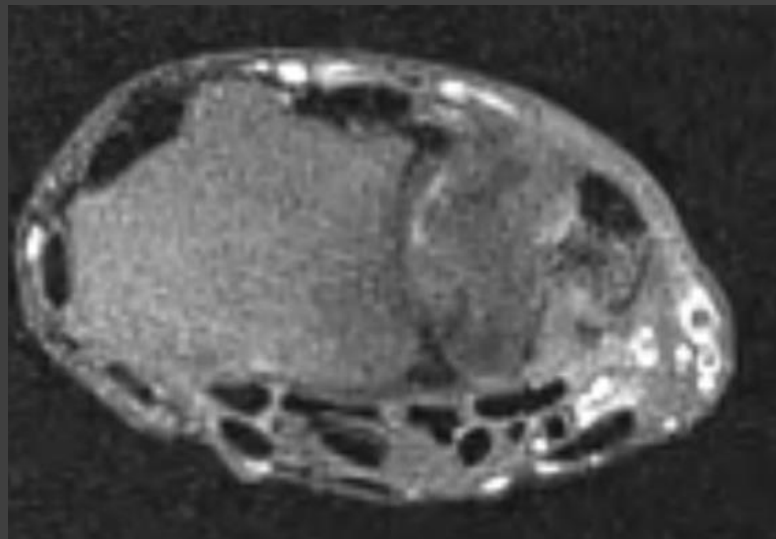
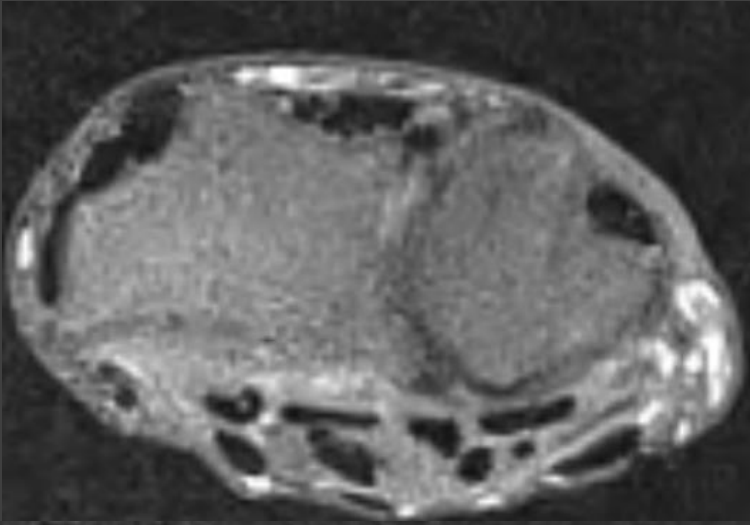
[@indiamsk](https://www.instagram.com/indiamsk)
[@IJMSR](https://www.instagram.com/ijmsr)



[@MSKSocietyIndia](https://twitter.com/MSKSocietyIndia)
[@IJMSR MSSIndia](https://twitter.com/IJMSR_MSSIndia)

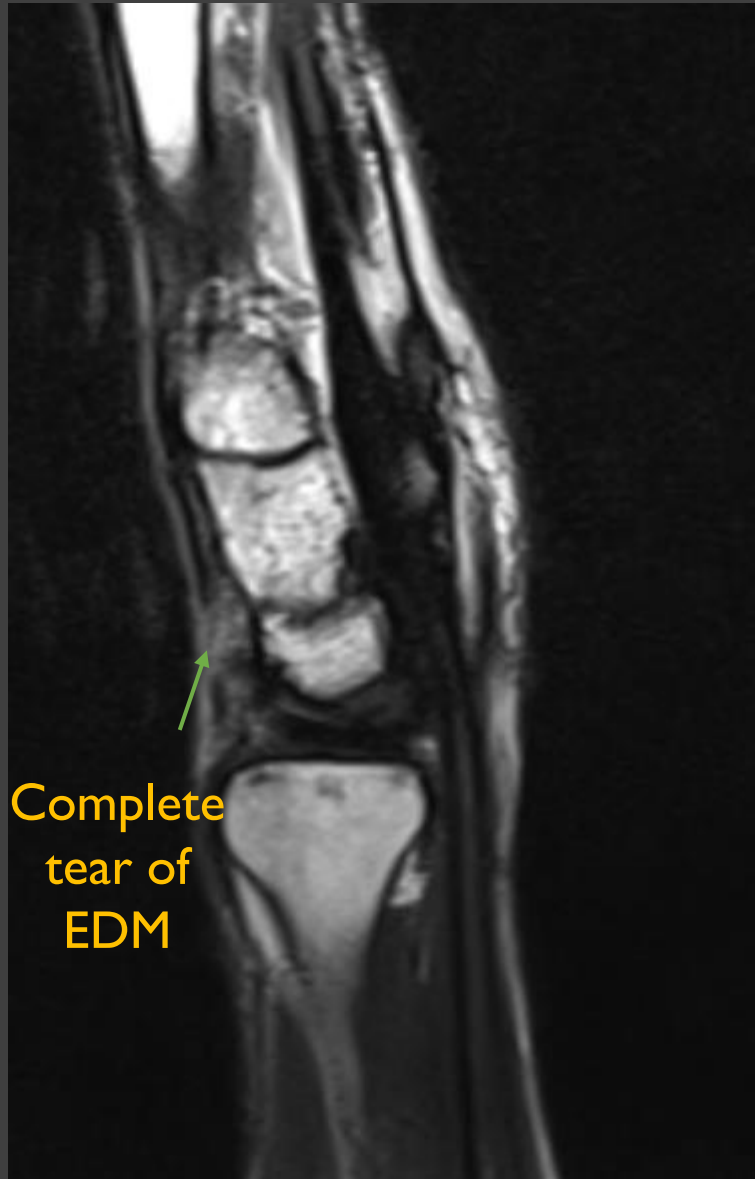


Images

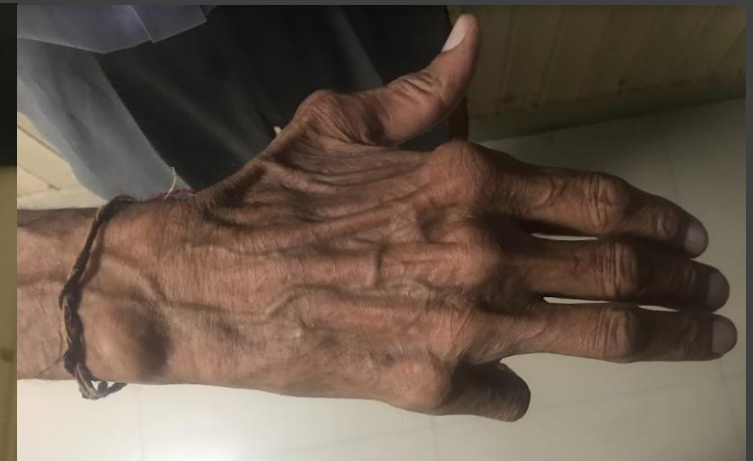
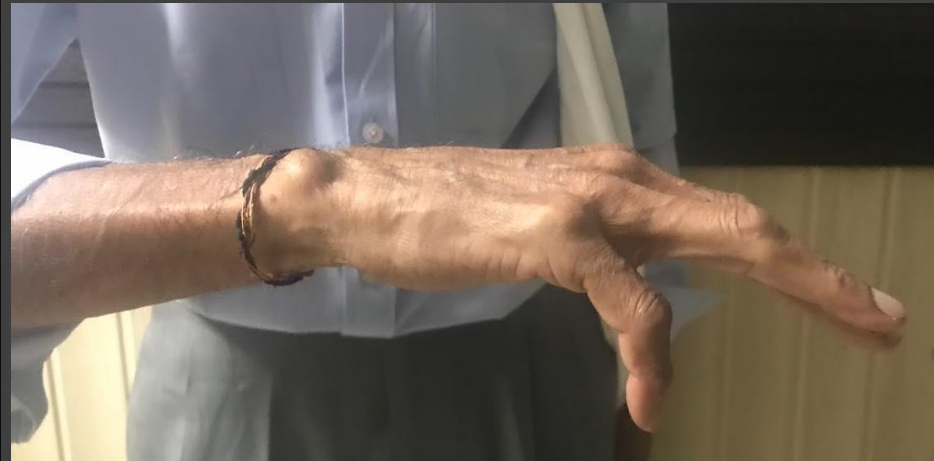
What is the diagnosis ?
Can this be seen in non traumatic setting ?

Complete tear of Extensor Digiti Minimi

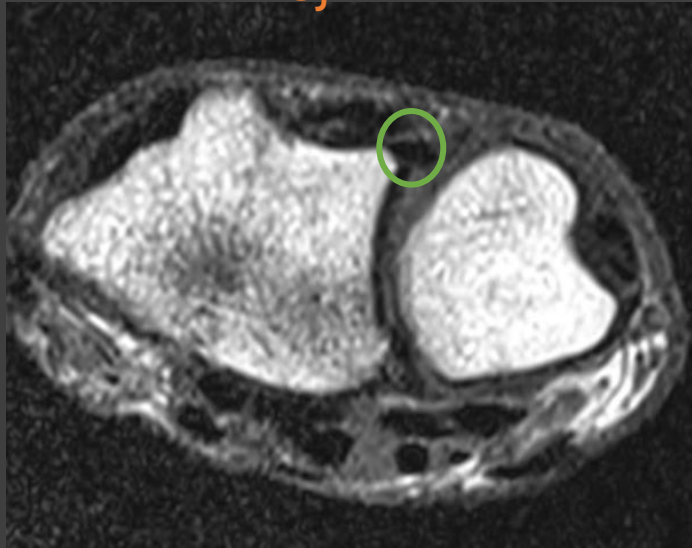


80-year-old, history of drooping of 5th digit
Was trying to start the generator

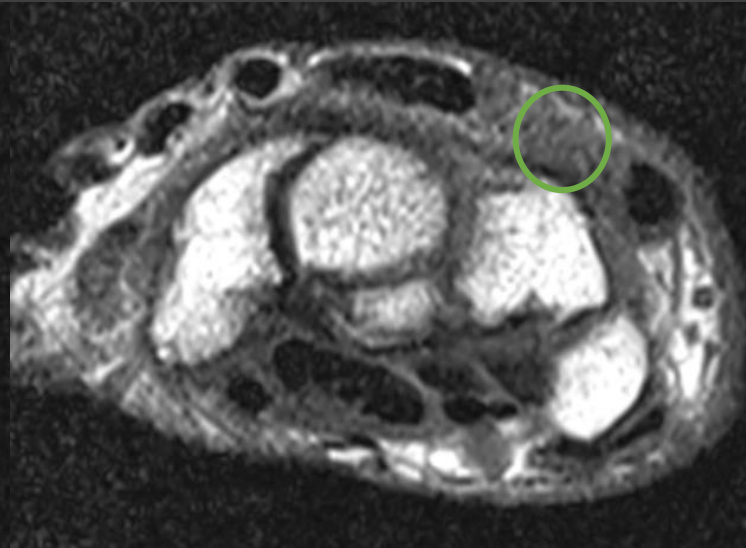


Complete tear of Extensor Digiti Minimi

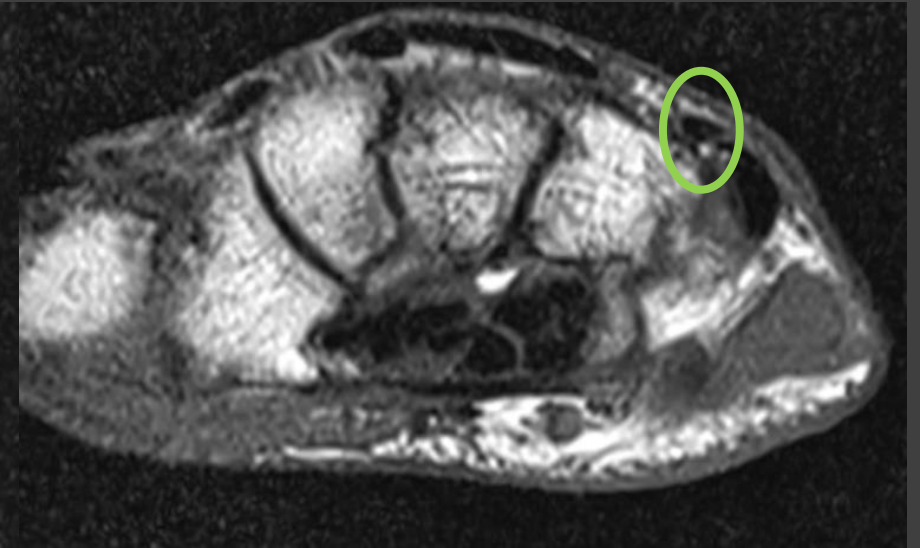
EDM TENDON
DRUJ



NO EDM TENDON
PROXIMAL CARPAL



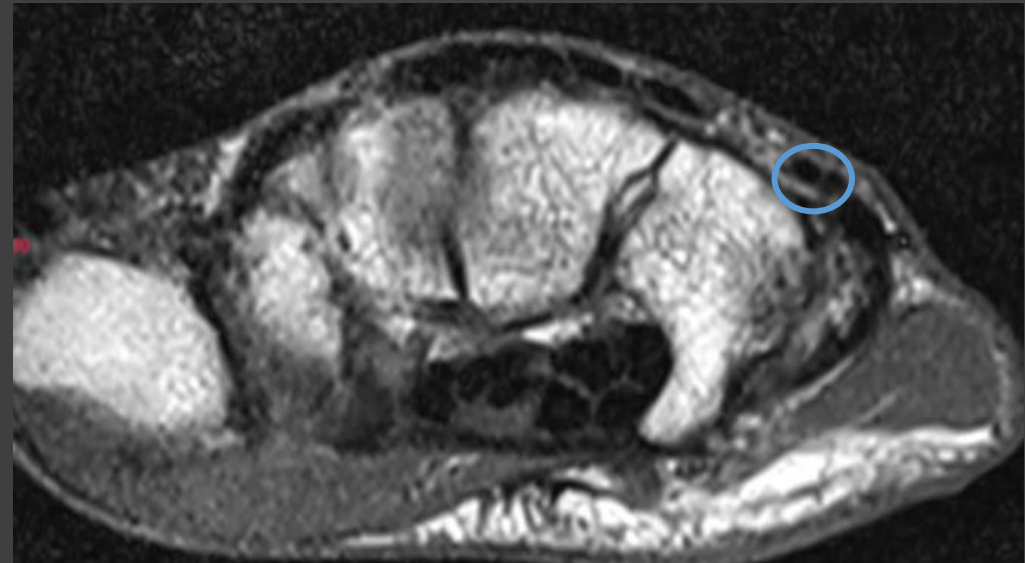
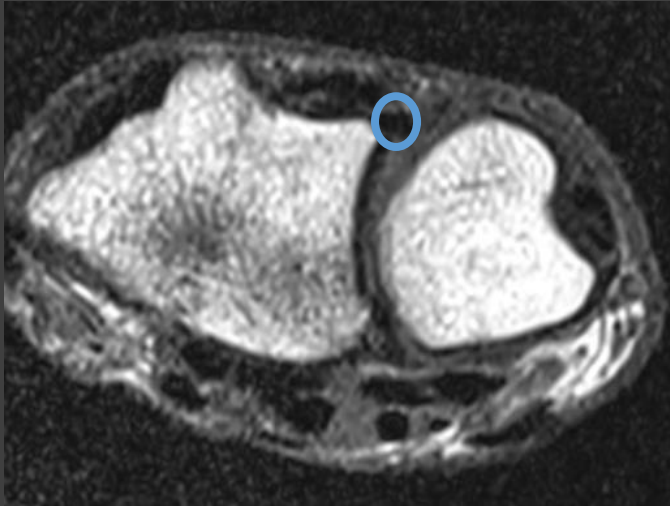
EDM TENDON AGAIN
DISTAL CARPAL



Complete tear of Extensor Digiti Minimi

Take home points

- I. EDM tendon overlies the DRUJ. Proximally it consist of a single slip and distally it appears to split into two slips which is normal and should not be mistaken for longitudinal split tear.



Complete tear of Extensor Digiti Minimi

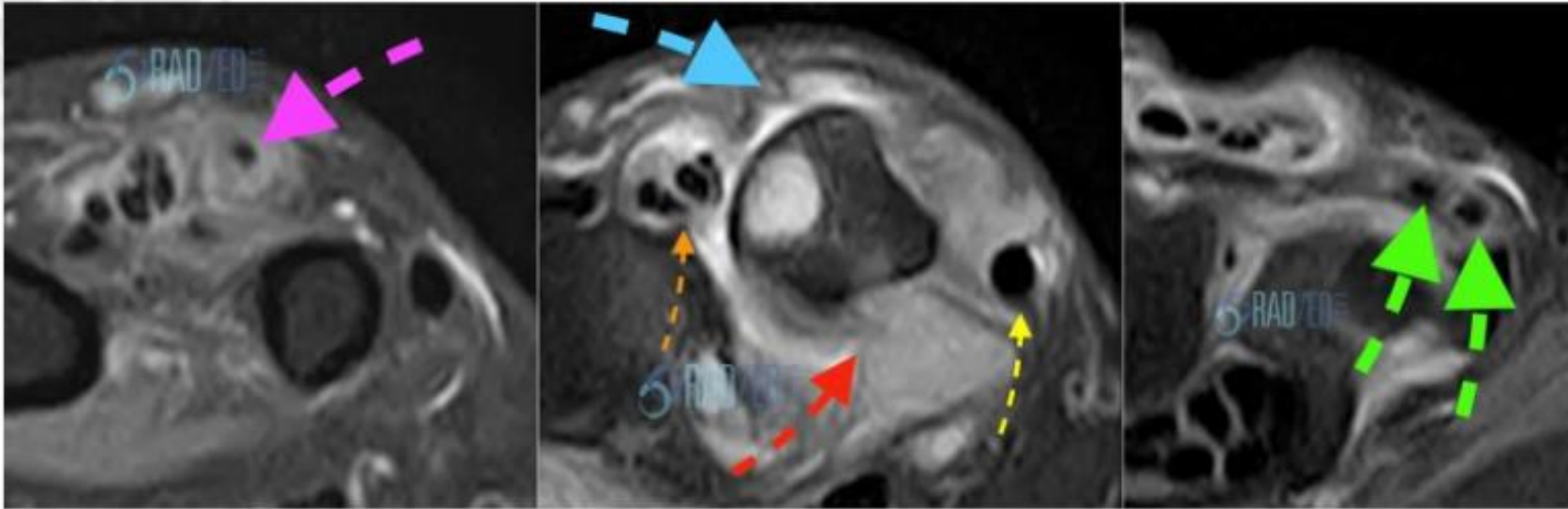


Image above: Ruptured EDM (Blue arrow no tendon). EDM proximally appears as a single tendon (Pink arrow) and more distally consists of two tendon slips (Green arrows). Extensor digitorum communis (Orange arrow) displaced medially and Extensor Carpi Ulnaris (Yellow arrow) dislocated. Severe synovitis and erosions DRUJ (Red Arrow).

2. Tear of the extensor digit minimi can also occur in atraumatic setting secondary to attrition particularly in cases of rheumatoid arthritis. Combination of the two is referred to as 'Vaughan Jackson syndrome'. Below companion case from the web.