

# MI-COD

MSS INDIA- Case Of the Day



27/09/2024

Case contributor  
Dr. Praveen Kumar Chinniah

Musculoskeletal Society of India (MSS) &  
Indian Journal of Musculoskeletal Radiology  
(IJMSR), the official publication of MSS India

For MICOD case archives visit <https://www.indianmss.org/>  
Check out our latest publication at <https://mss-ijmsr.com/>

*Authentic source of MSK Radiology*

For daily MSK radiology updates & great educational  
contents, follow us on



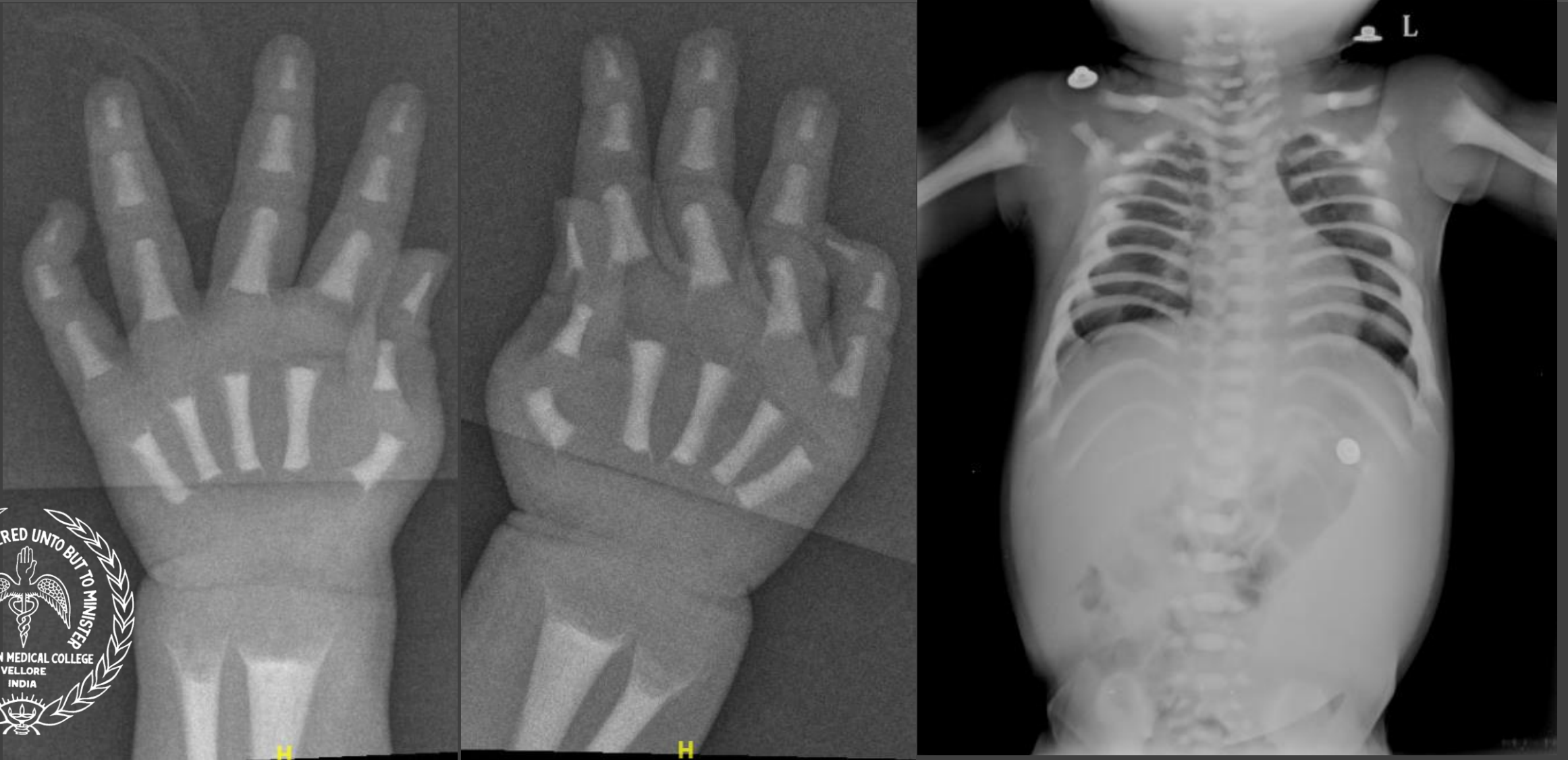
[@indiamsk](https://www.instagram.com/indiamsk)  
[@IJMSR](https://www.instagram.com/ijmsr)



[@MSKSocietyIndia](https://twitter.com/MSKSocietyIndia)  
[@IJMSR MSSIndia](https://twitter.com/IJMSR_MSSIndia)



# Osteopetrorickets



*Extensive medullary sclerosis with bone within bone appearance, metaphyseal cupping, fraying, splaying and hepatosplenomegaly*

Osteopetrorickets

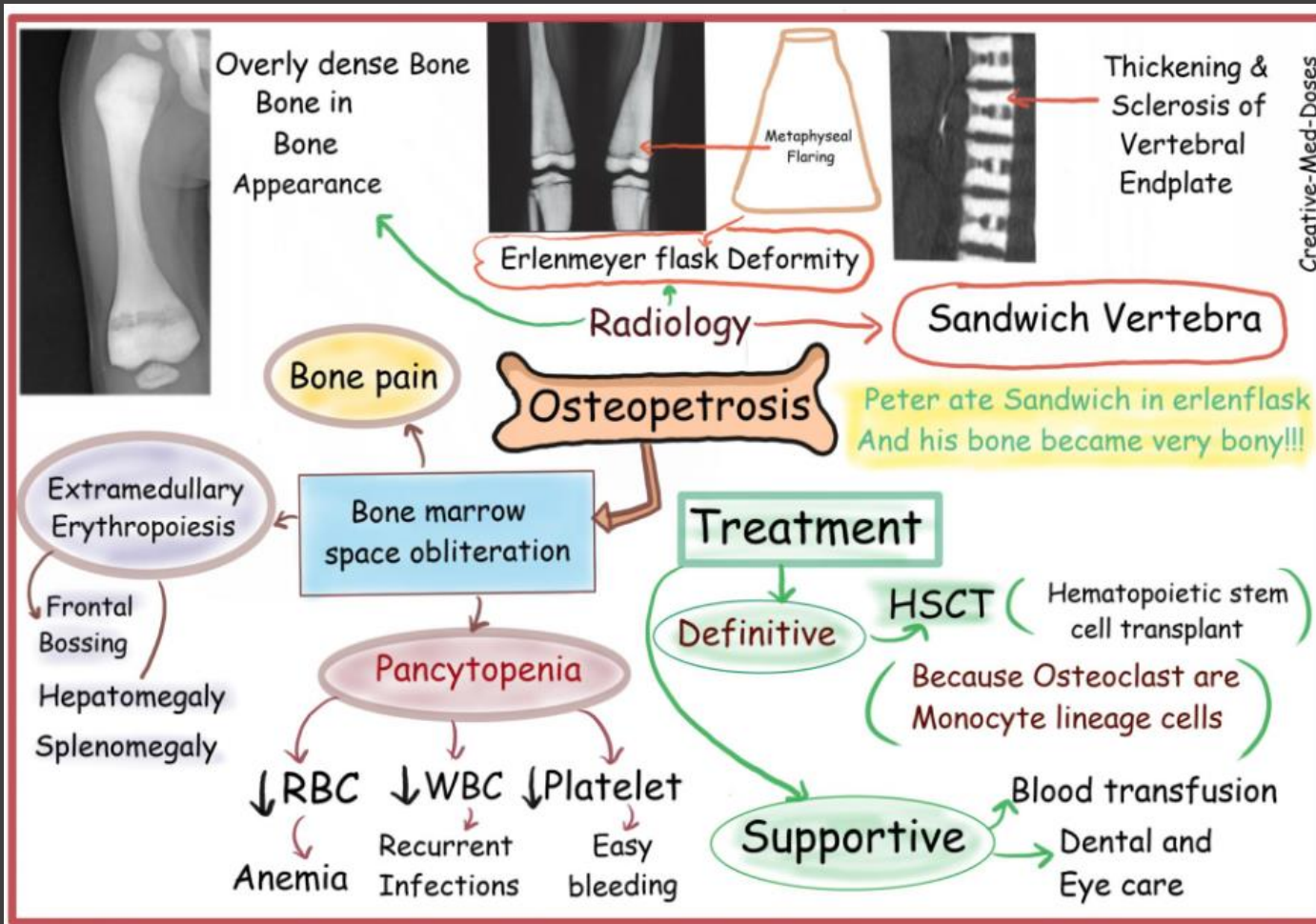
# THE PARADOX OF PLENTY



*Scarcity despite wealth!*

<https://themoneyengineers.com/2024/05/27/the-paradox-of-plenty/>

# Osteopetrorickets



- *Rickets is a common and paradoxical feature of infantile malignant osteopetrosis and results from the inability of osteoclasts to maintain a normal calcium-phosphorus balance in the extracellular fluid.*
- *Despite a markedly positive total body calcium balance, rickets arises when the serum calcium x phosphorus product is insufficient to mineralize newly formed chondroid and osteoid.*
- *Skeletal survey & serial monitoring important in infants with hypophosphatemia & failure to thrive*
- *Important to diagnose and manage rickets & sequelae of secondary hyperparathyroidism, even in cases where the bones are dense.*