


MICOD –12/09/2024

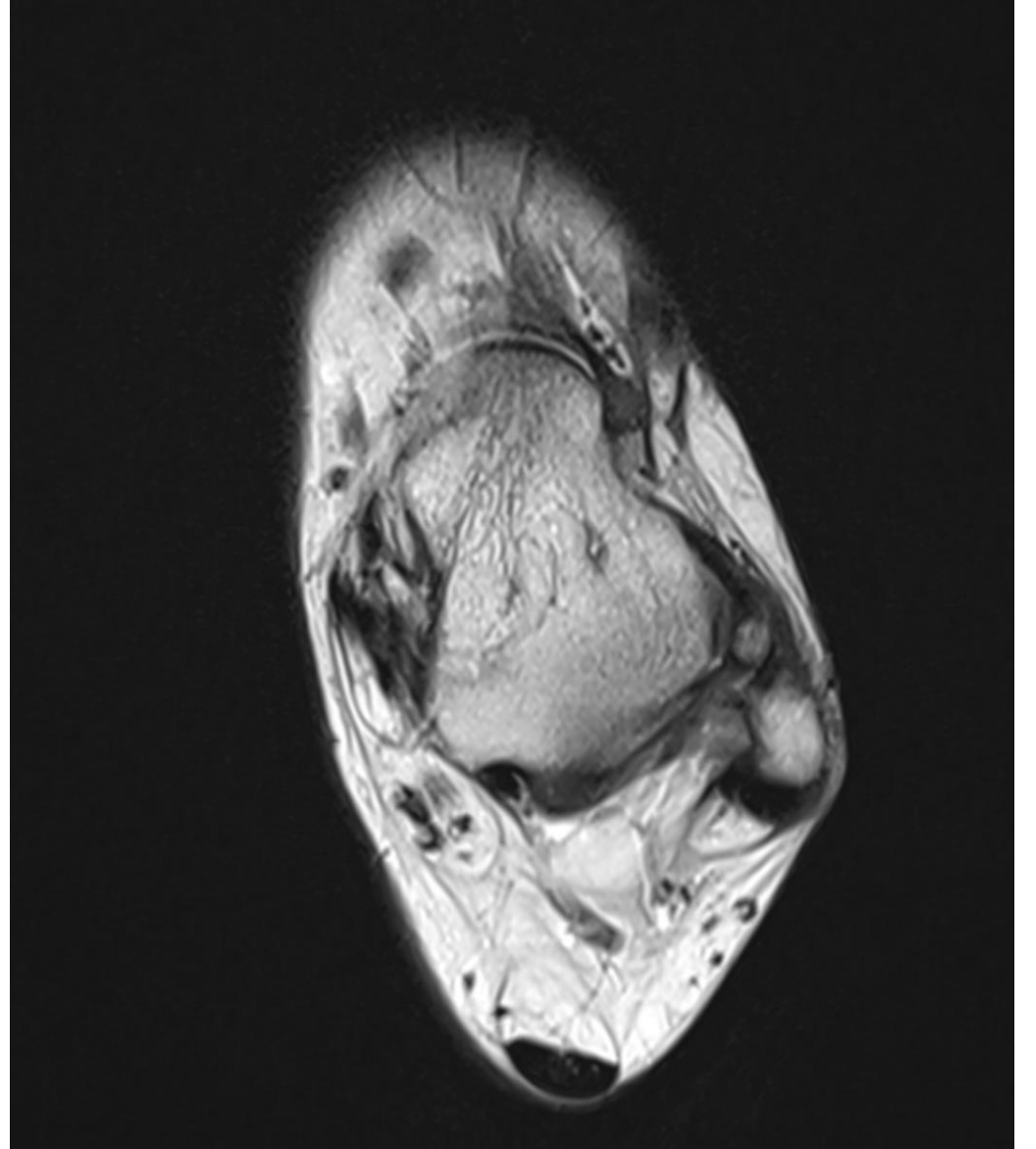
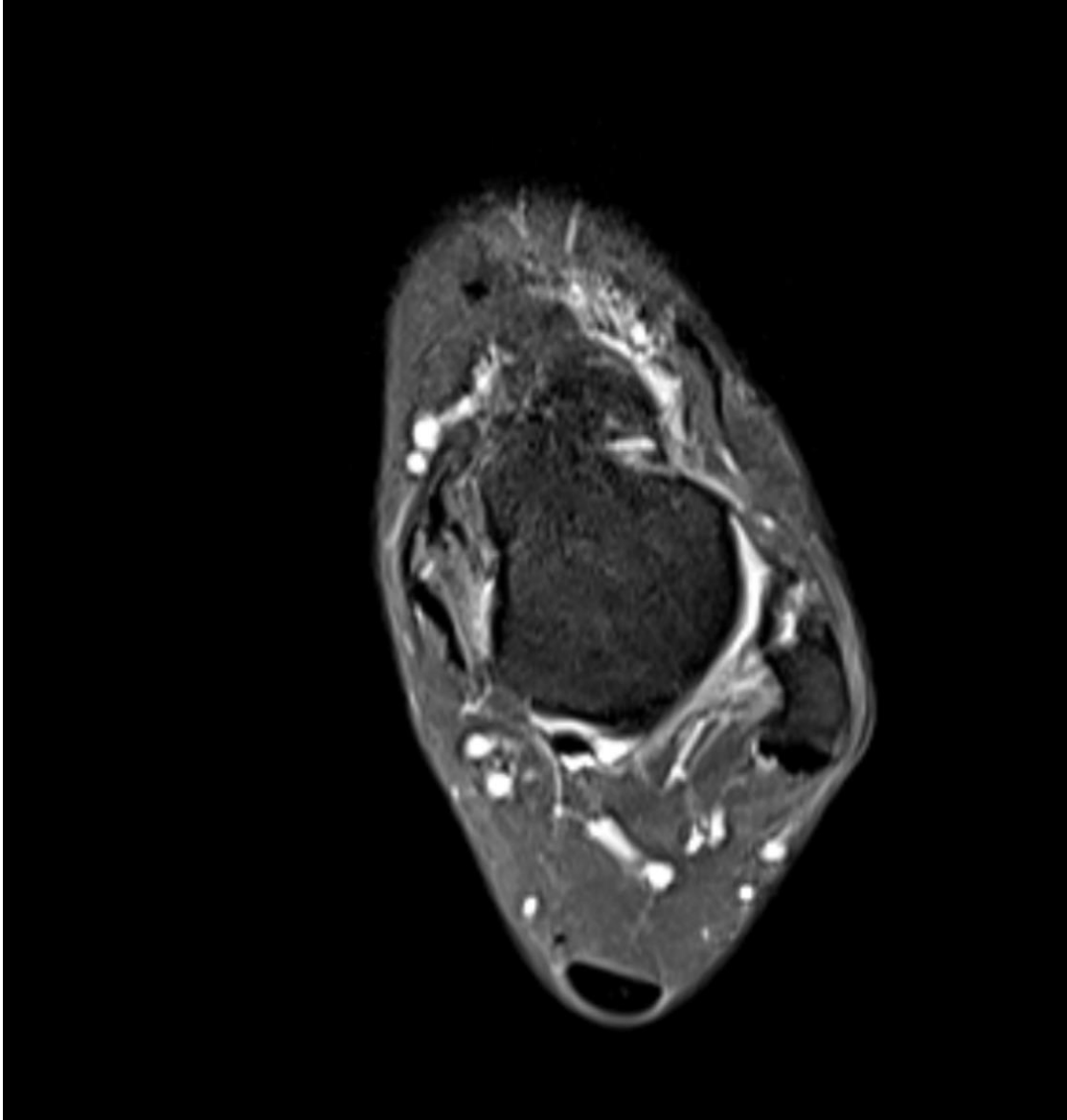
Case contributor – Dr. Karan Asthana

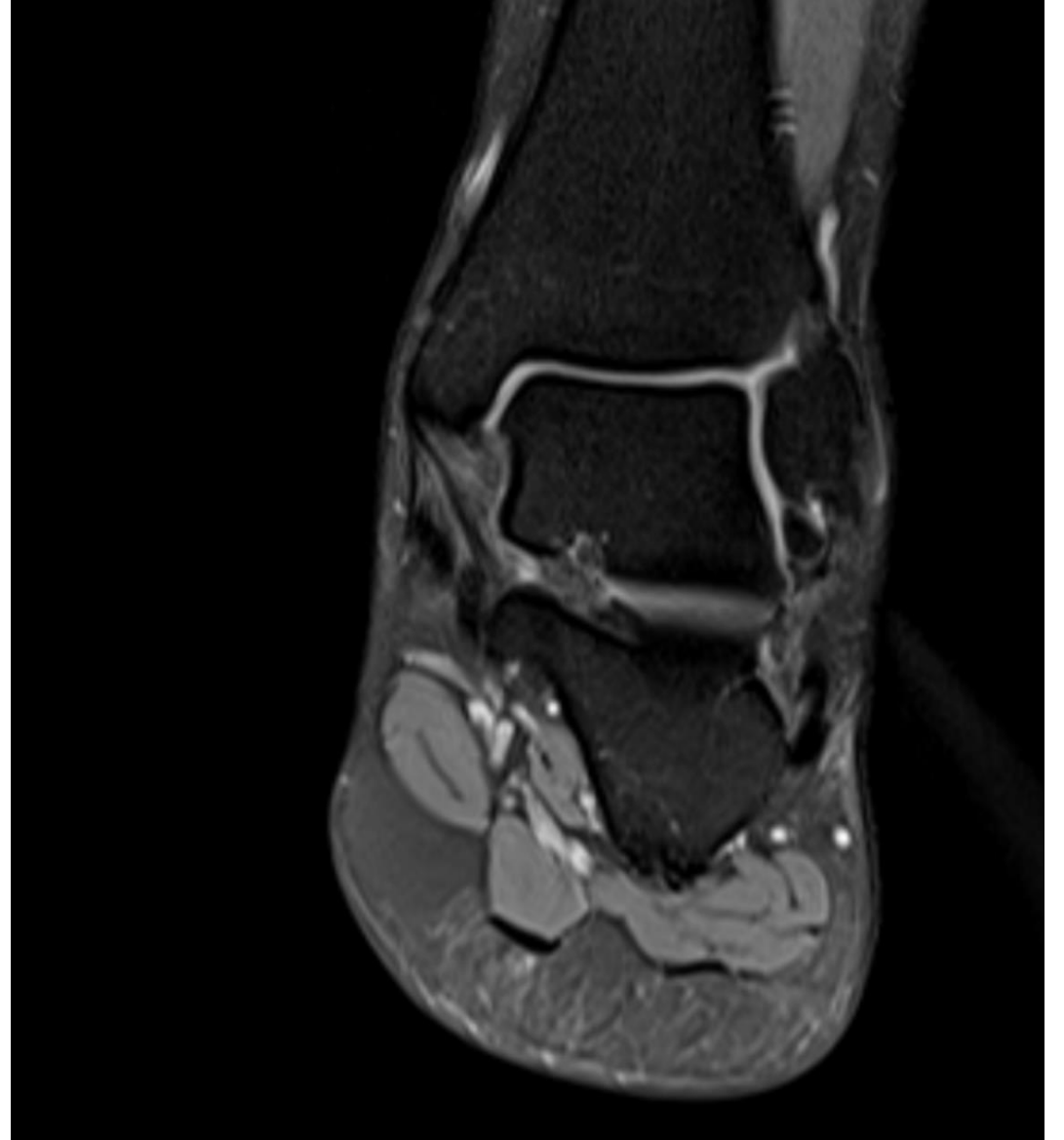
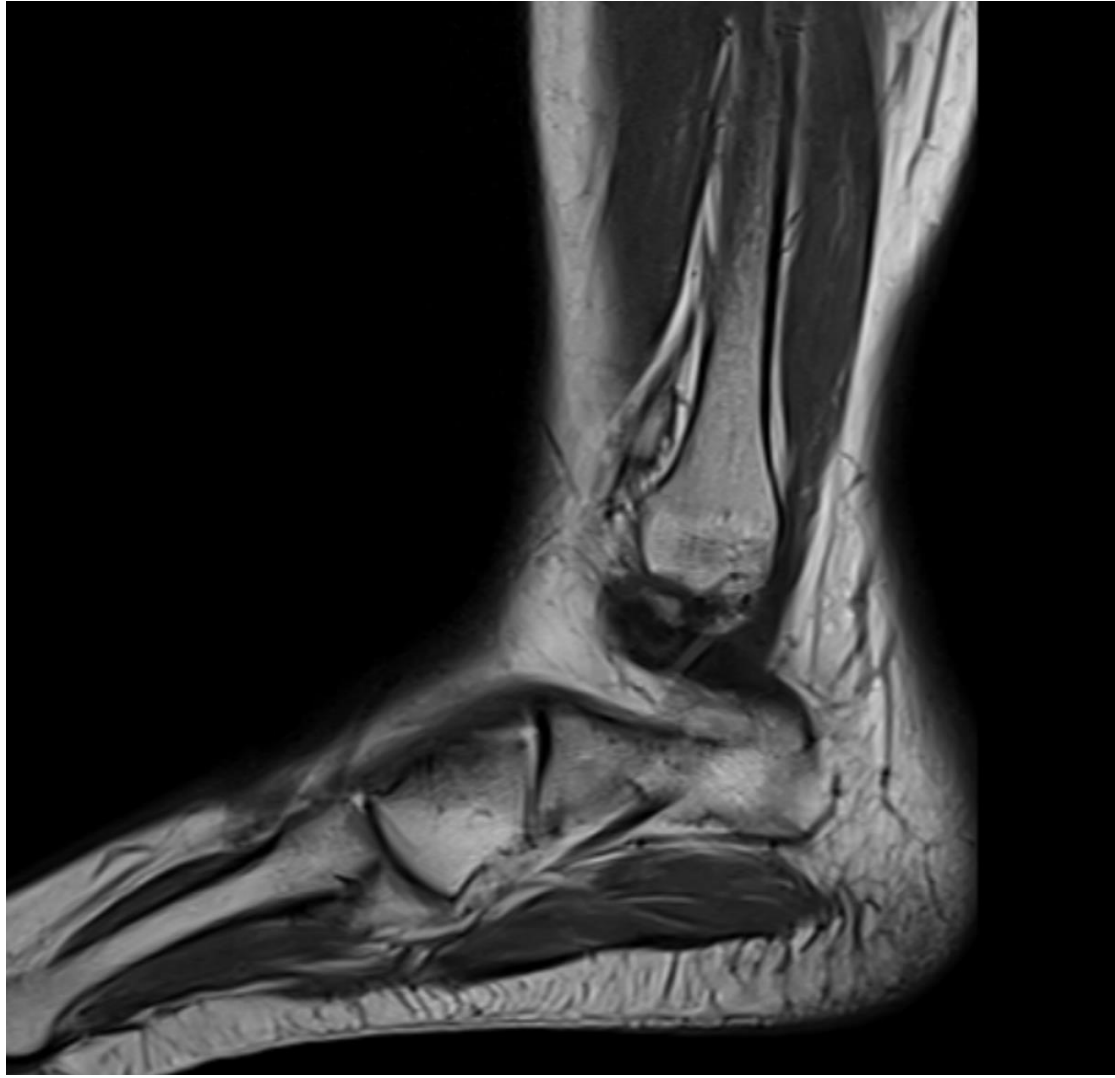MI-COD

MSS INDIA- Case Of the Day



- 20 yrs female patient with history of sports injury 1 month back.





- 
- **ANSWER-** AVULSION FRACTURE INVOLVING FIBULAR ATTACHMENT OF ANTERIOR TALOFIBULAR LIGAMENT.

To be
noted...

- There are two theories regarding the origin of os subfibulare:
 1. An avulsion fracture attributable to pull of the anterior talofibular ligament.
 2. An unfused accessory ossification center. Typically, the secondary center of ossification of the lateral malleolus appears during the first year of life and fuses with the shaft at 15 years.
- The majority are thought to be post-traumatic rather than congenital in etiology.



THANK YOU