

MICOD - 22/05/24

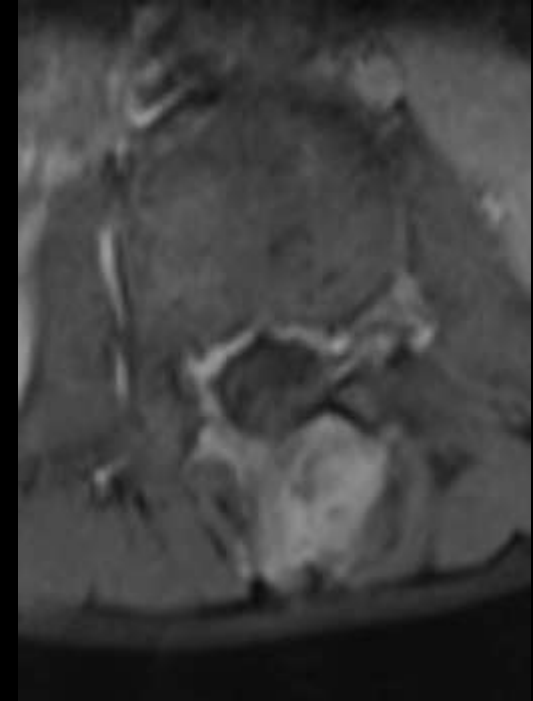
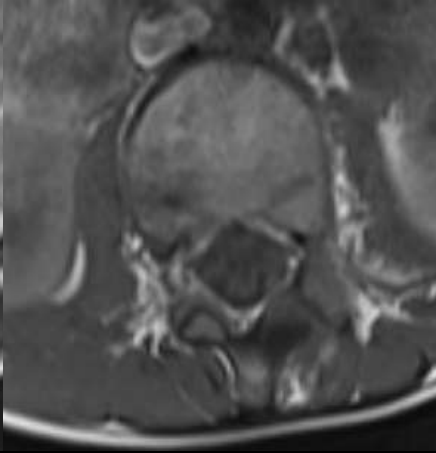
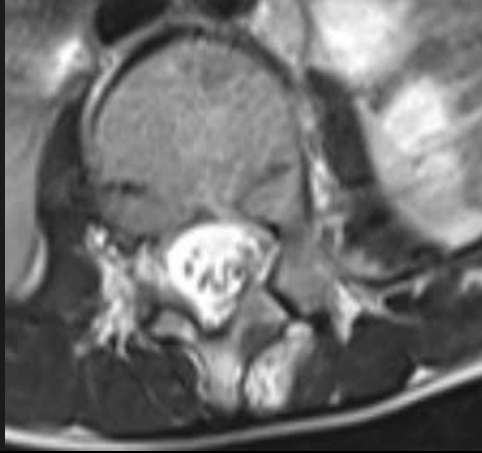
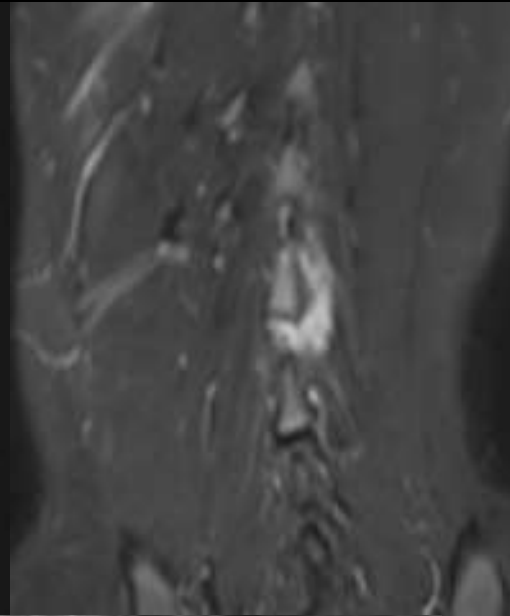
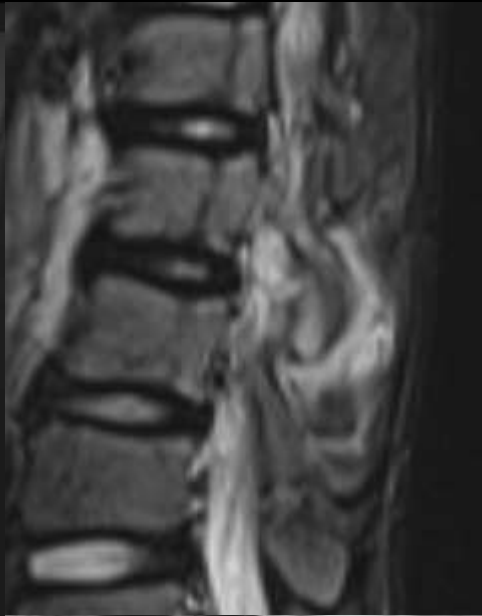
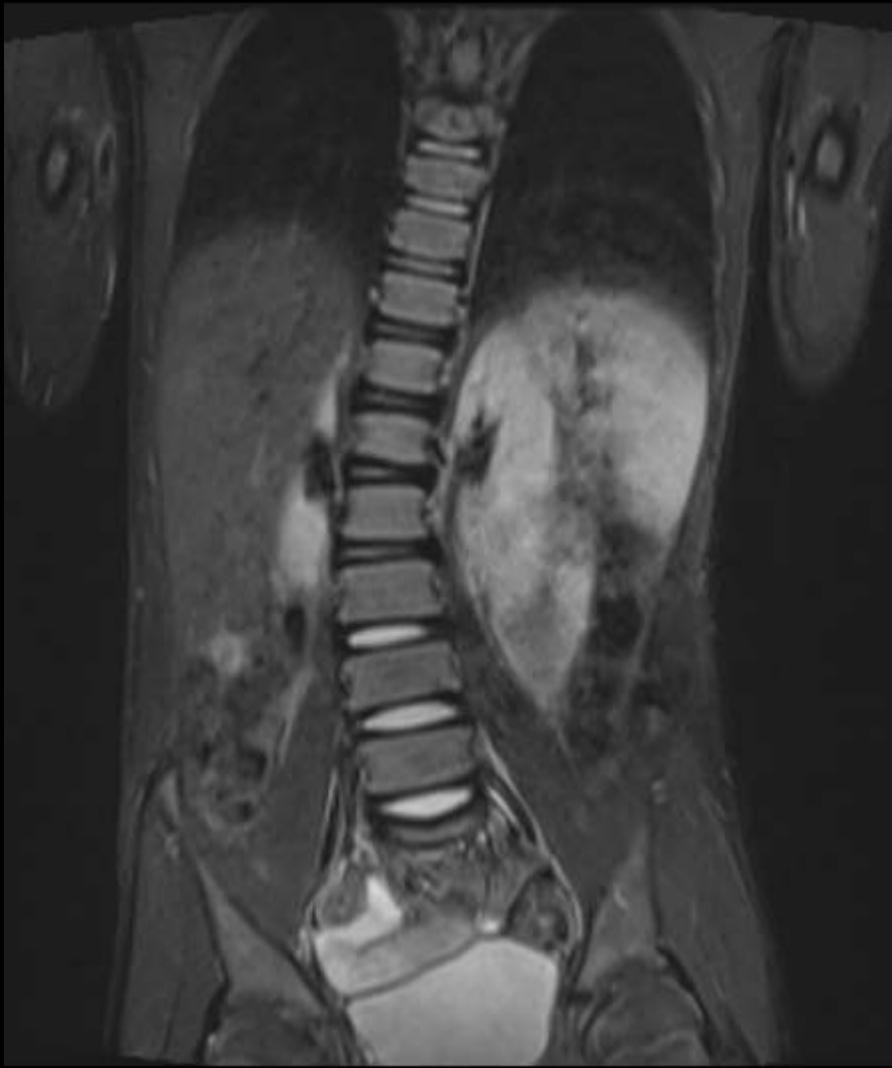
Case contributor – Dr. Sonal Saran

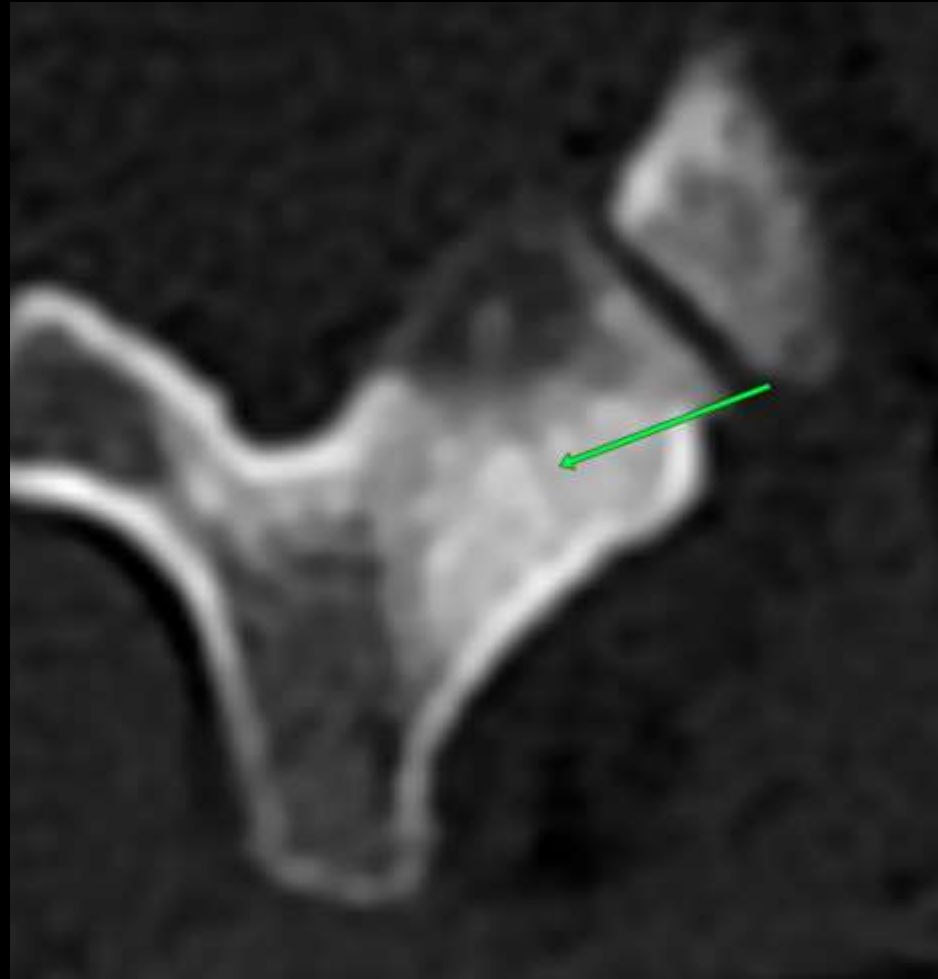
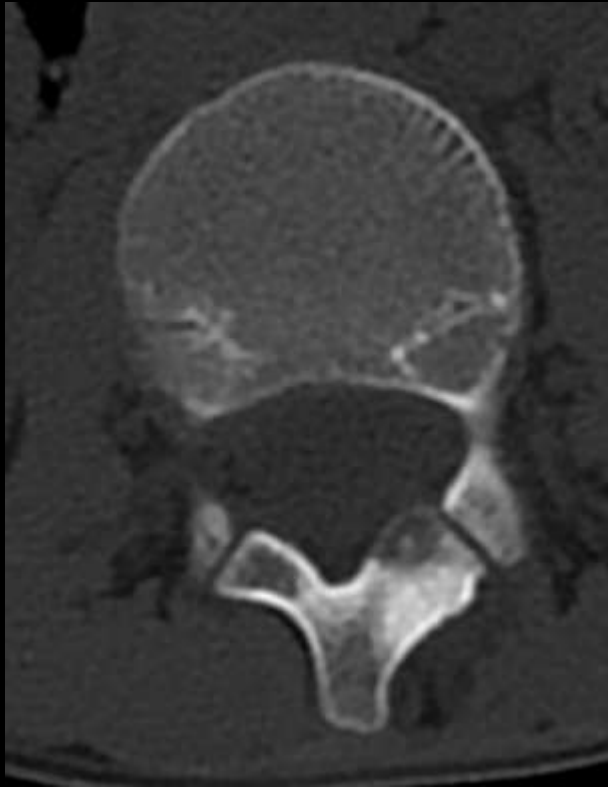
# MI-COD

MSS INDIA- Case Of the Day



9 year old boy with pain in lower back





**The Vascular Groove Sign: A CT Finding Associated With Osteoid Osteoma**