

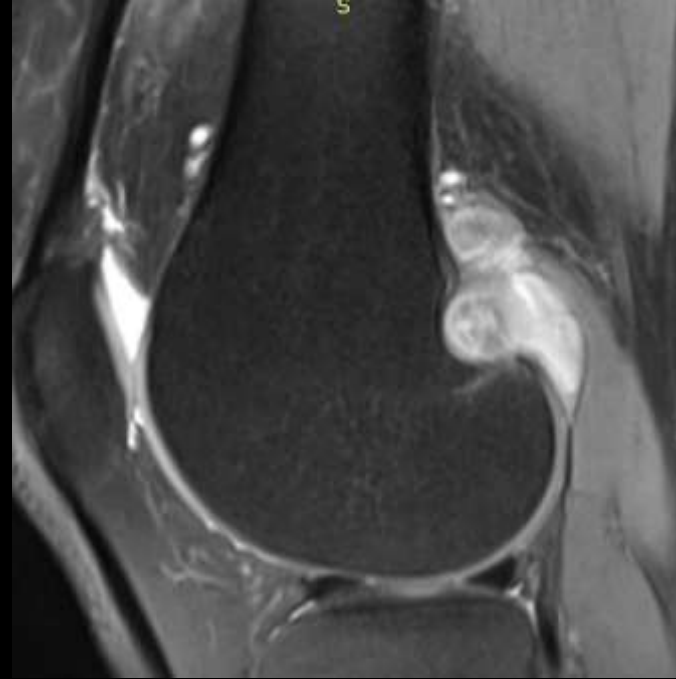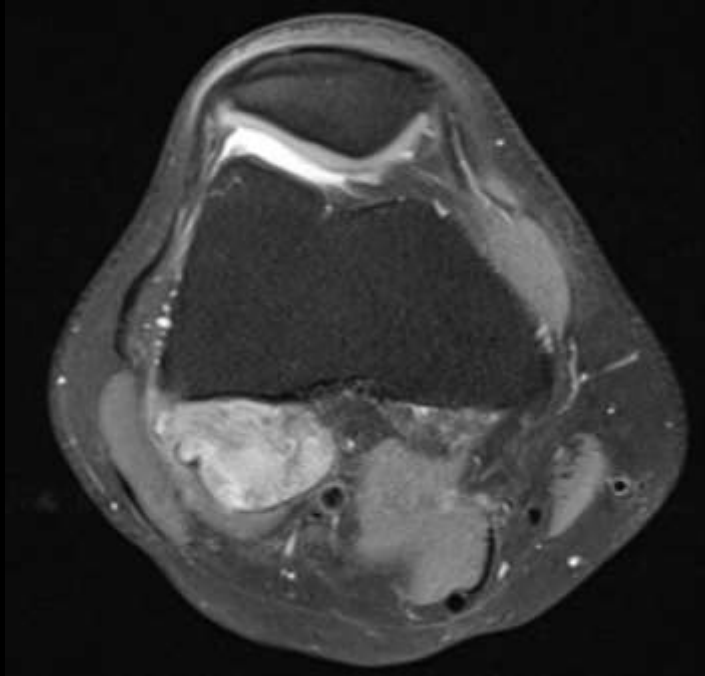
MICOD - 20/05/24

Case contributor – Dr. Sonal Saran

# MI-COD

MSS INDIA- Case Of the Day





32 year old male with knee pain

USG guided biopsy revealed fibromatosis