

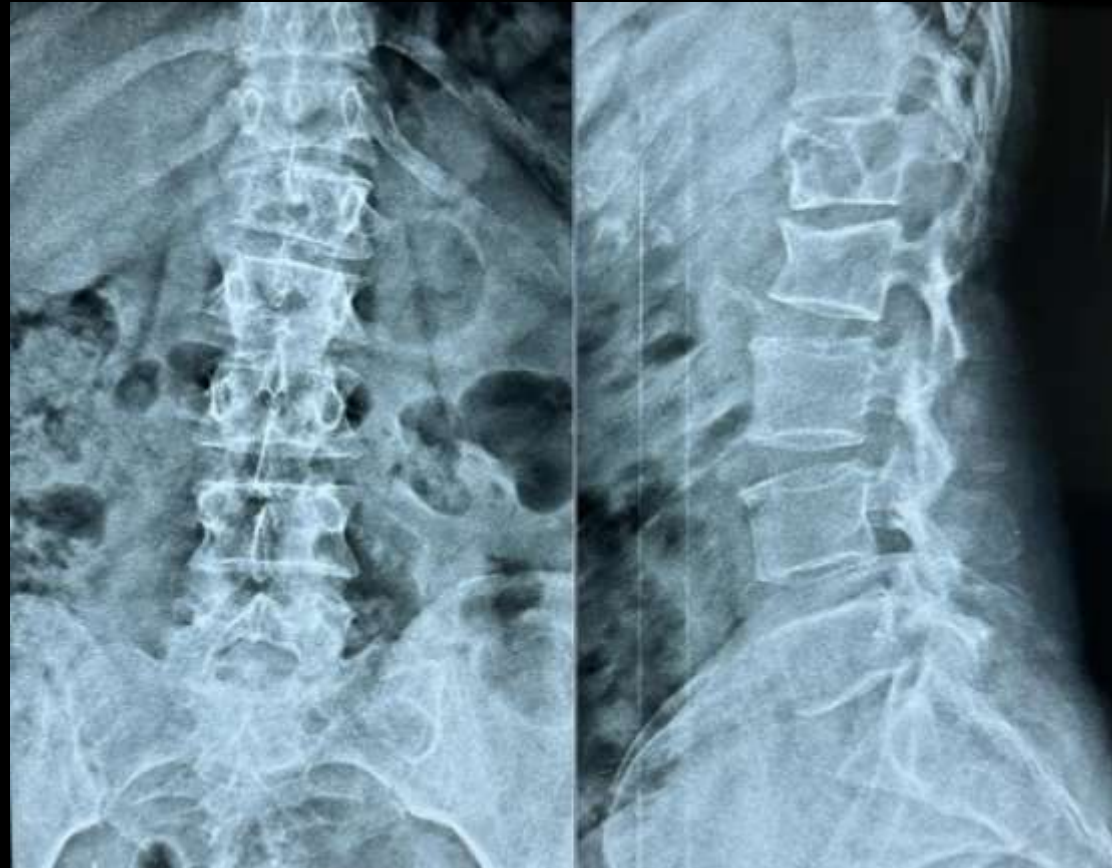
MICOD - 18/05/24

Case contributor – Dr. Sonal Saran

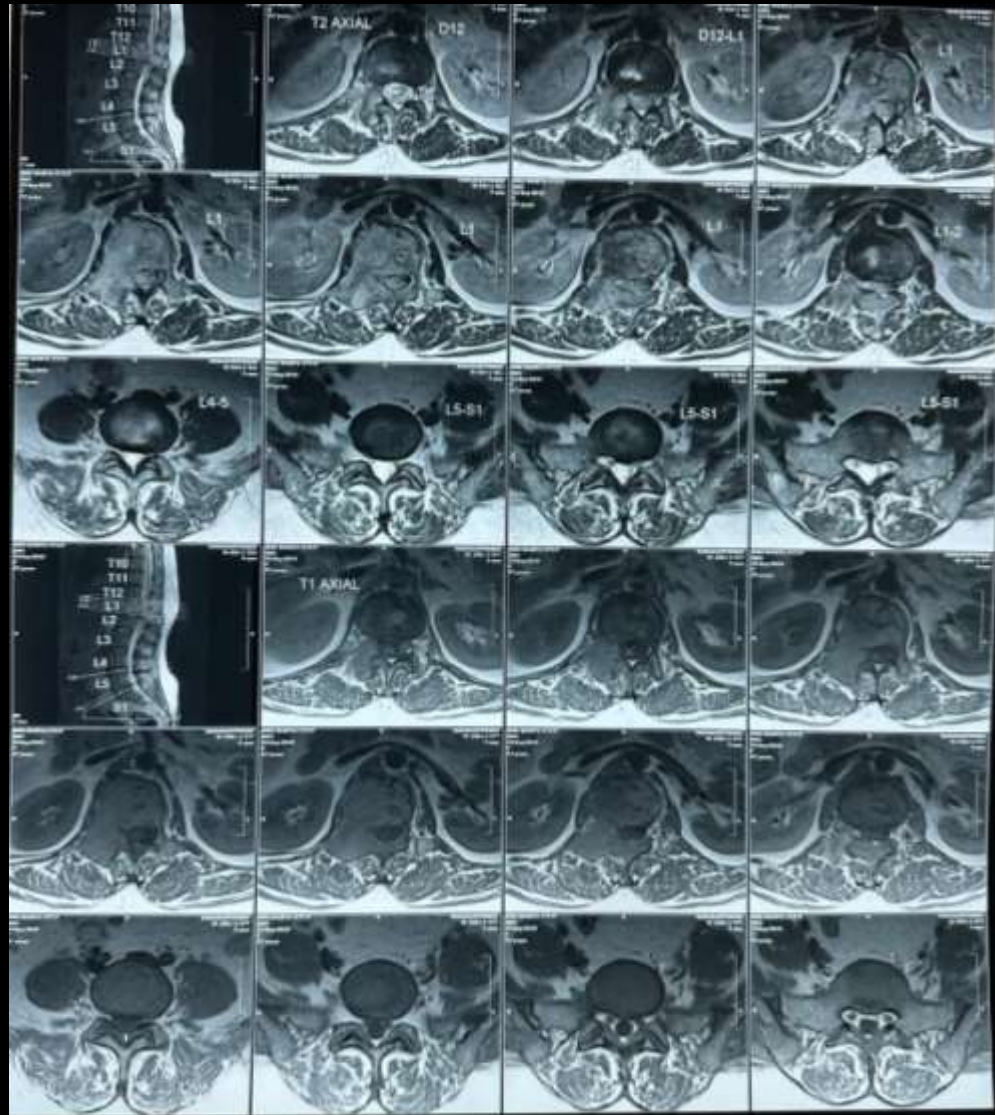
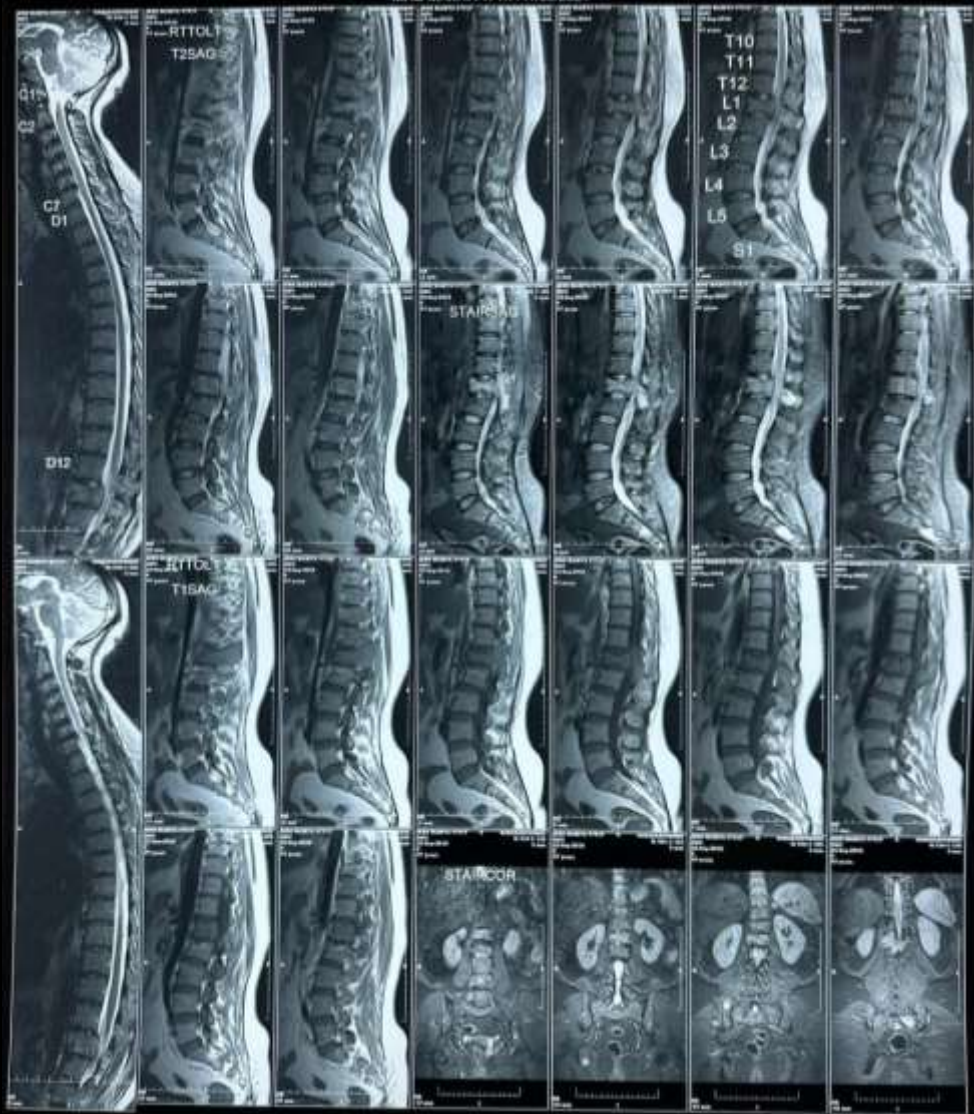
MI-COD

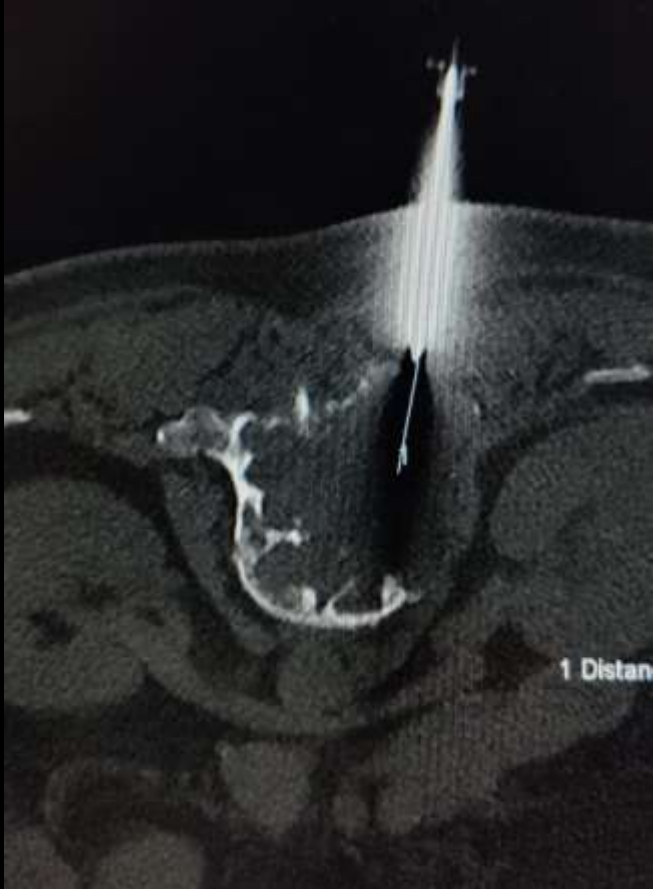MSS INDIA- Case Of the Day





47 year old female with pain in back





HPE revealed plasmacytoma