

MICOD – 25/08/2024

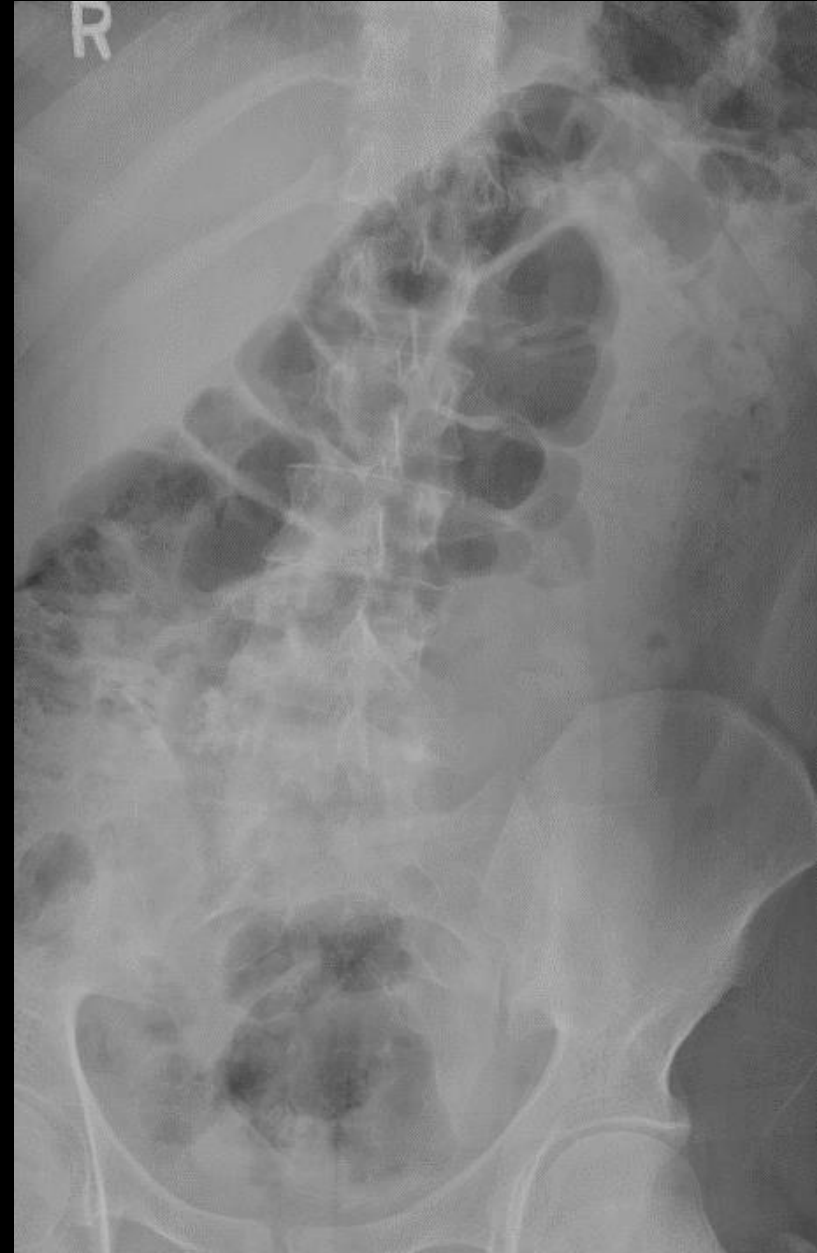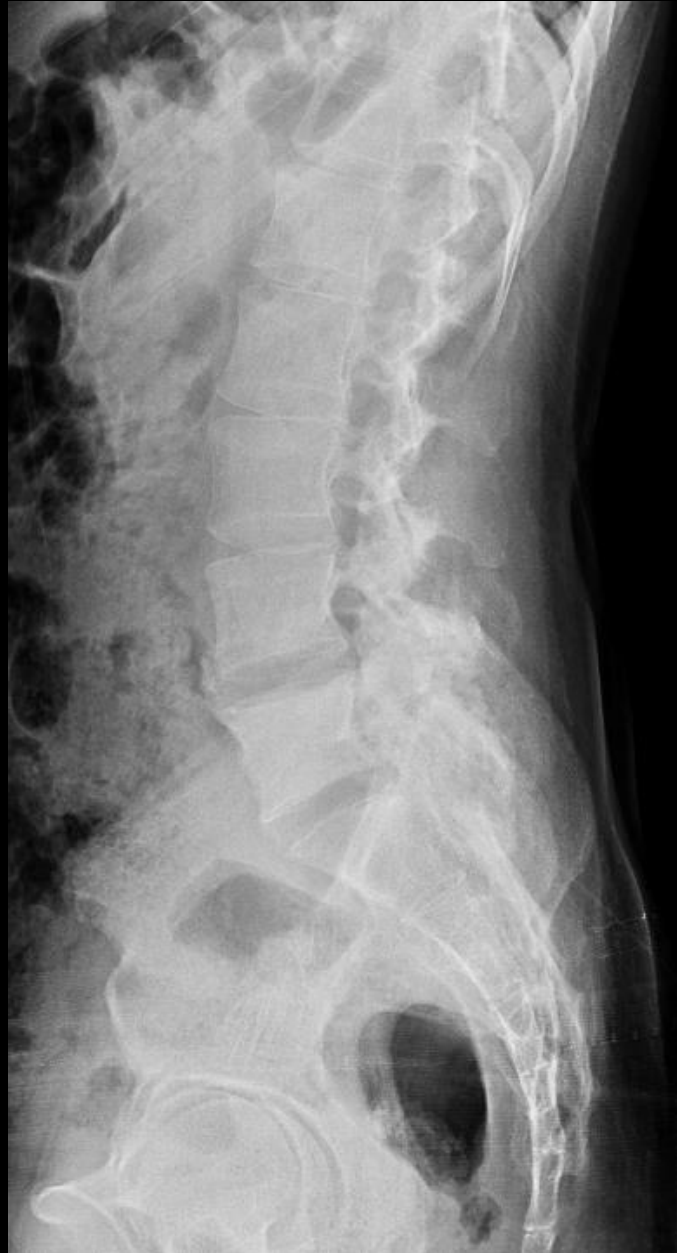Case contributor – Dr. Vikas Batra

# MI-COD

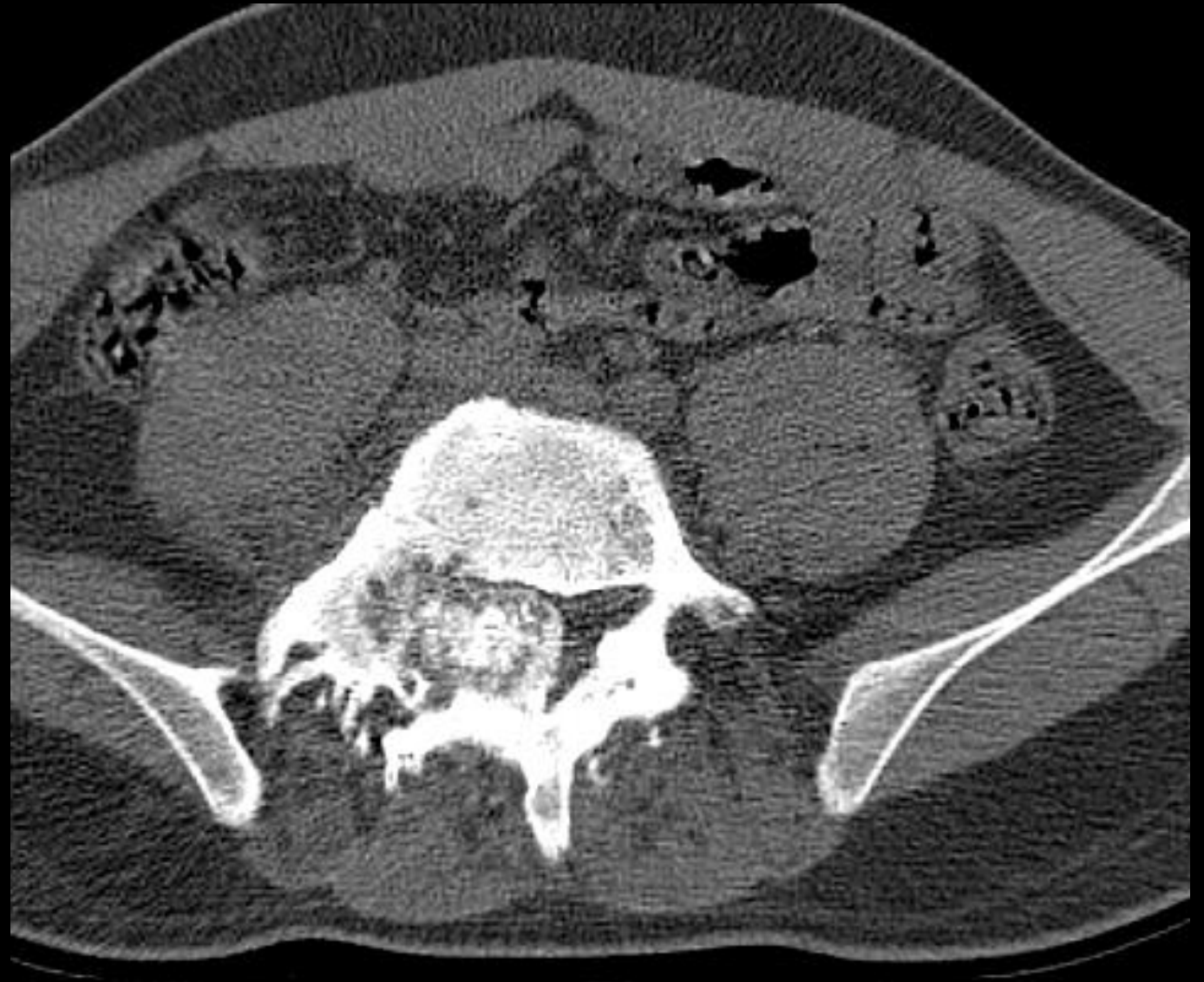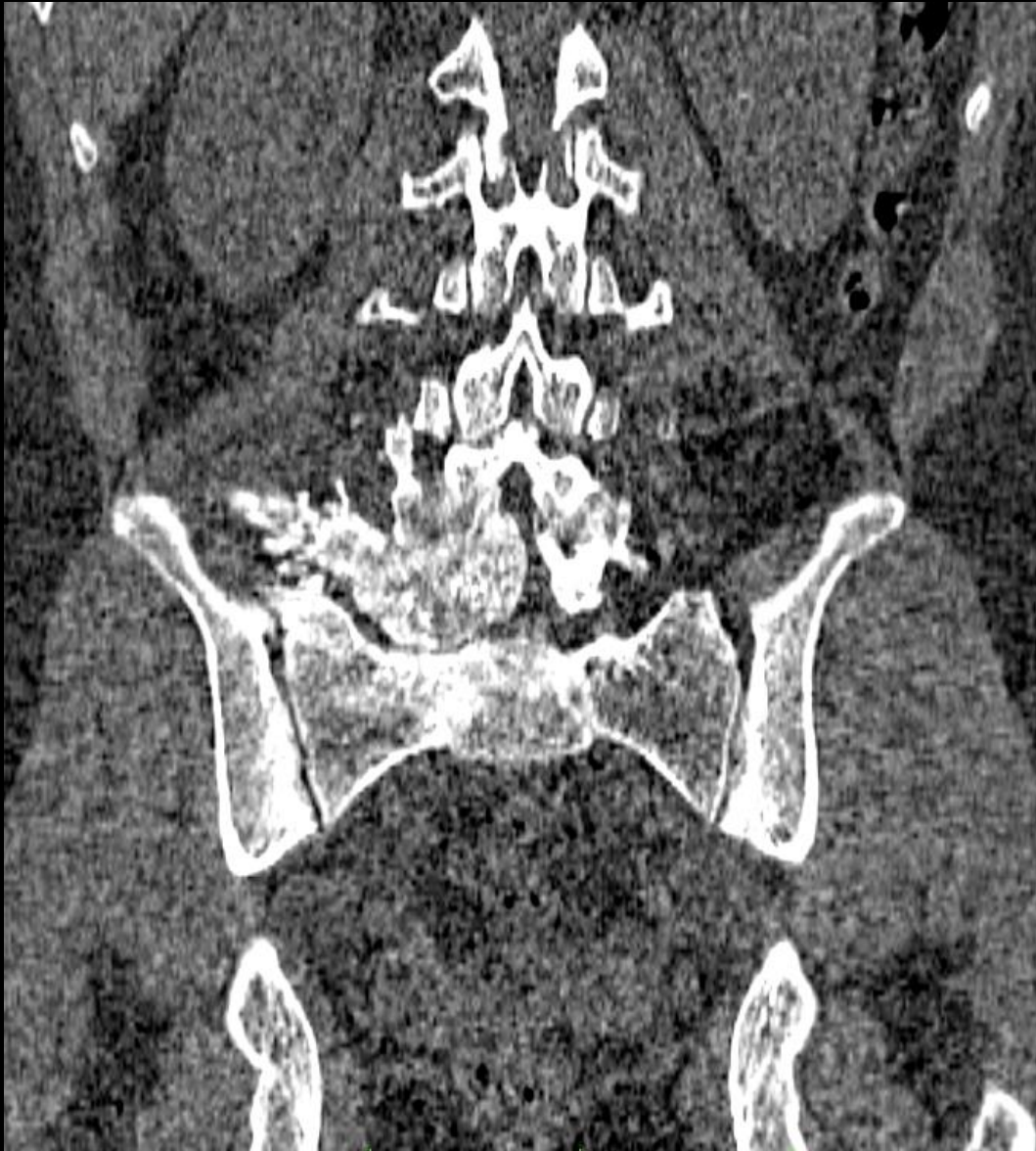MSS INDIA- Case Of the Day



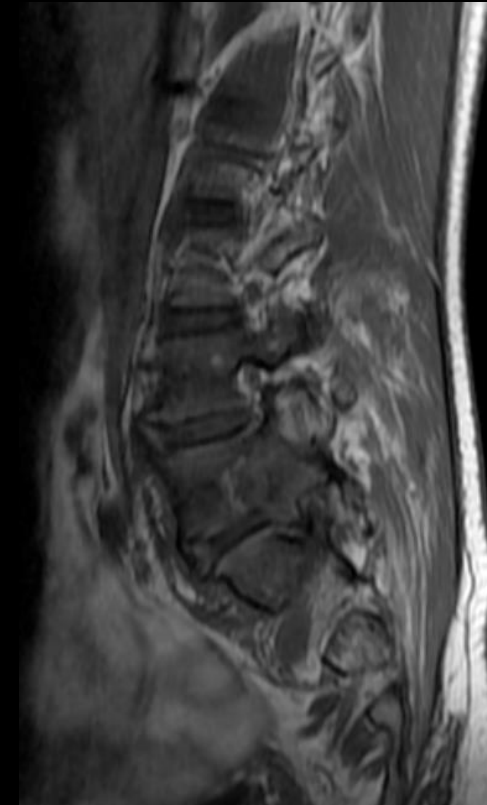
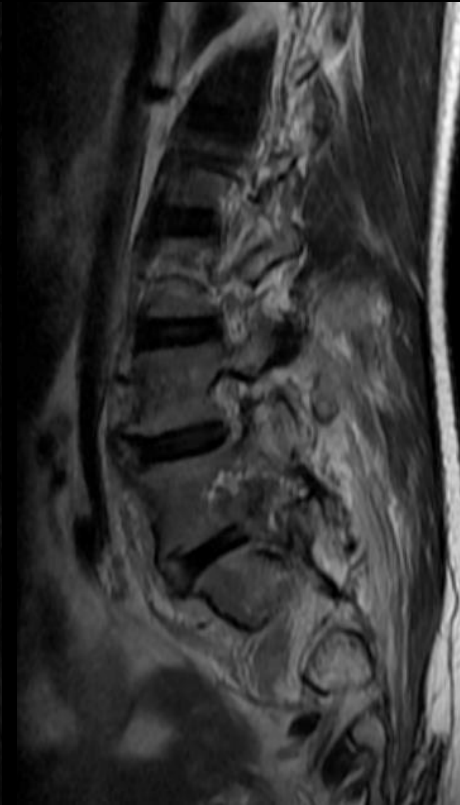
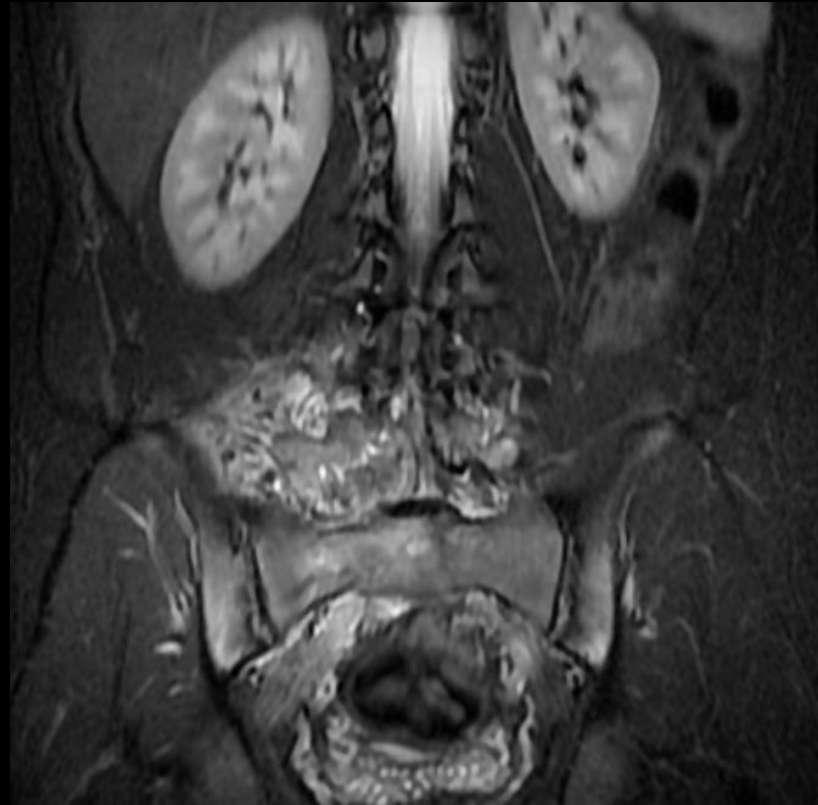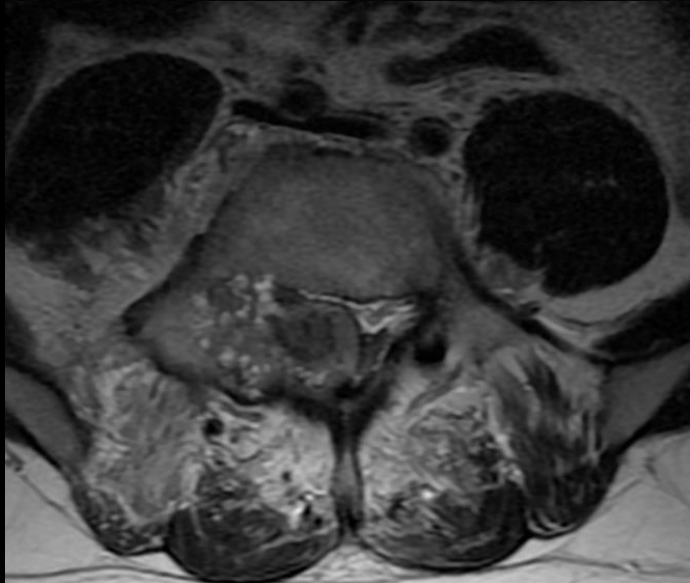
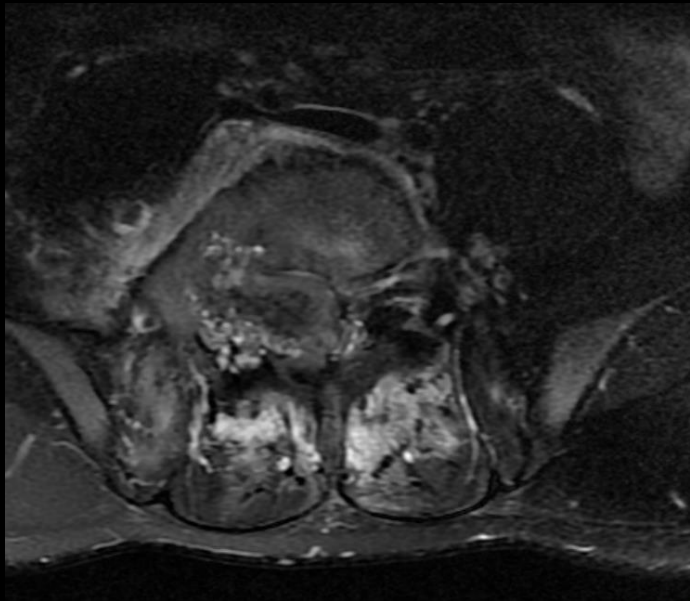
23-year-old gentleman with low backache, stiffness, and intermittent fever for past 1 year



23-year-old gentleman with low backache, stiffness, and intermittent fever for past 1 year

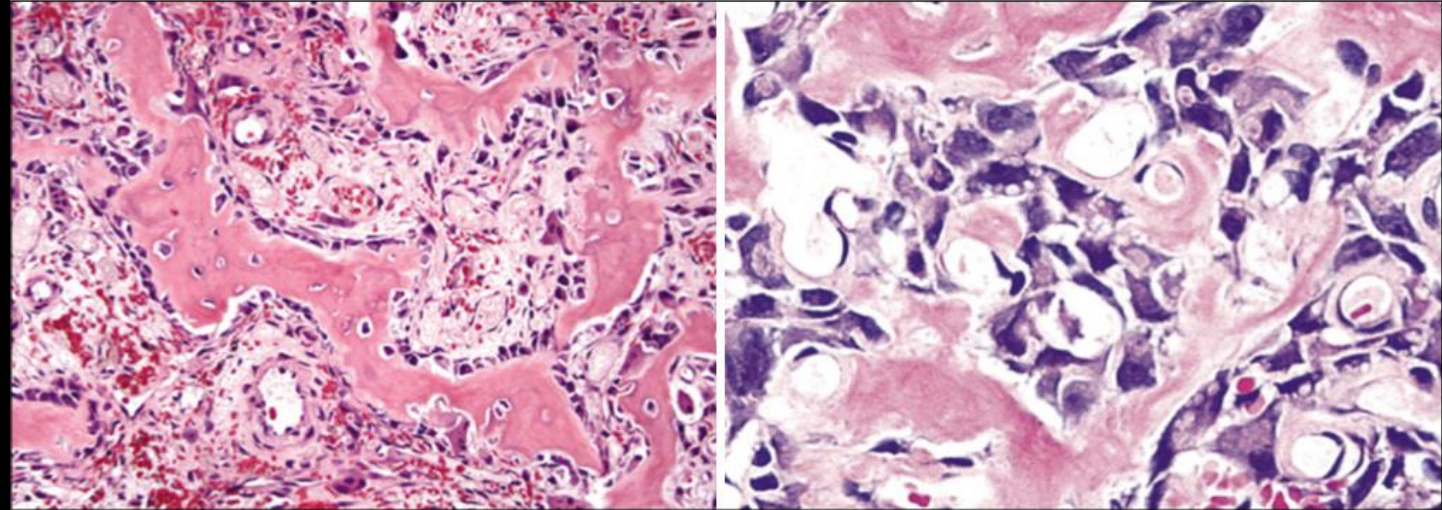


23-year-old gentleman with low backache, stiffness, and intermittent fever for past 1 year



## Toxic flare phenomenon of osteoblastoma

CT & MRI showed show heterogeneous expansile predominantly blastic/sclerotic lesion with internal speckled mineralization centered at the junction of right pedicle and transverse process of L5 vertebra with extensive periostitis/periosteal reaction mimicking an aggressive neoplasm and associated bilateral symmetrical sacroiliitis.



*Histopathological examination showed anastomosing trabeculae of woven bone lined by a single layer of plump osteoblasts within a loosely textured fibrovascular stroma suggesting osteoblastoma.*

*There was co-existing HLA B27 related acute sacroiliitis and local toxic flare phenomenon of osteoblastoma in the form of reactive periostitis.*