


MICOD –14/08/2024

Case contributor – Dr. Harun Gupta

MI-COD

MSS INDIA- Case Of the Day

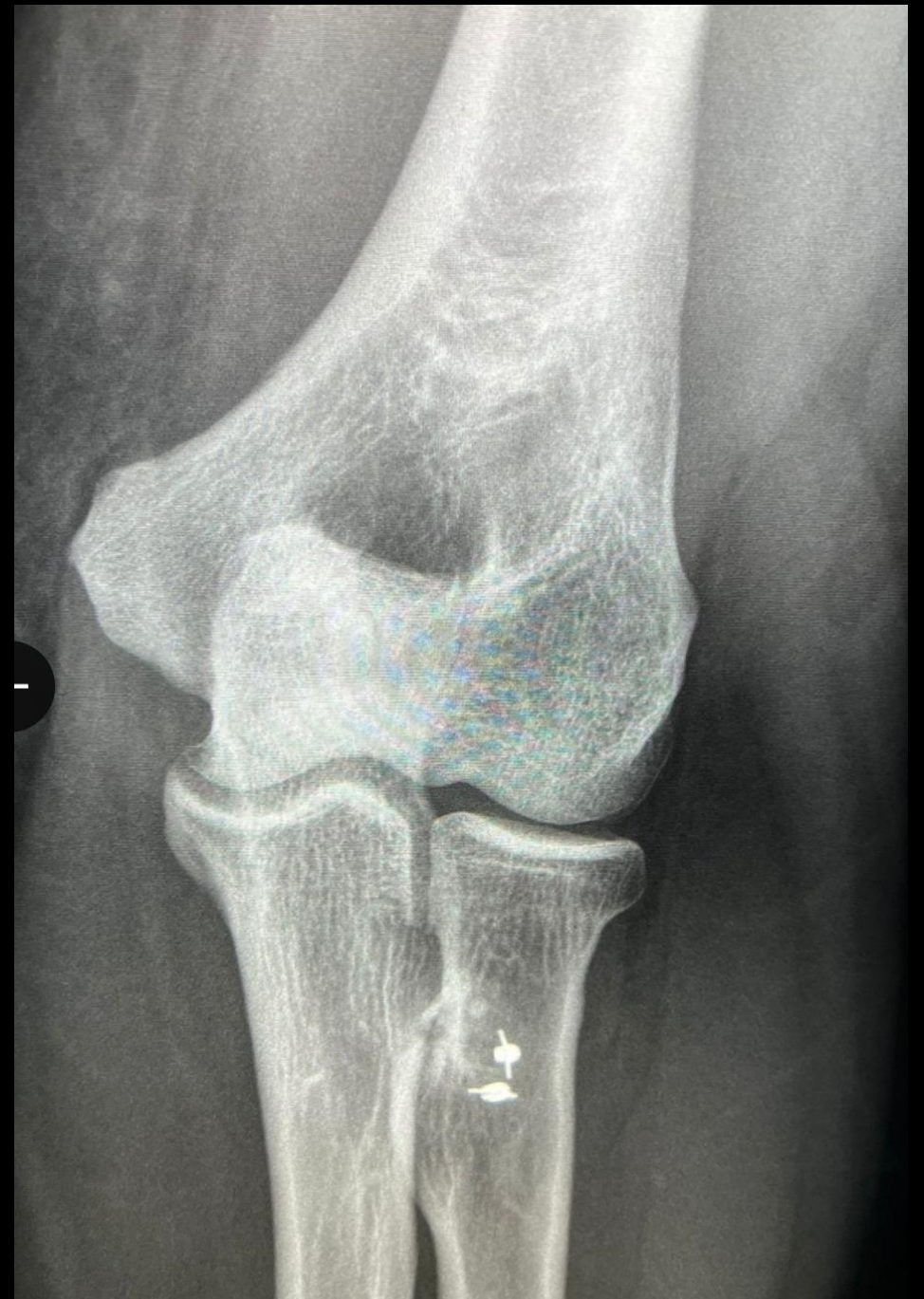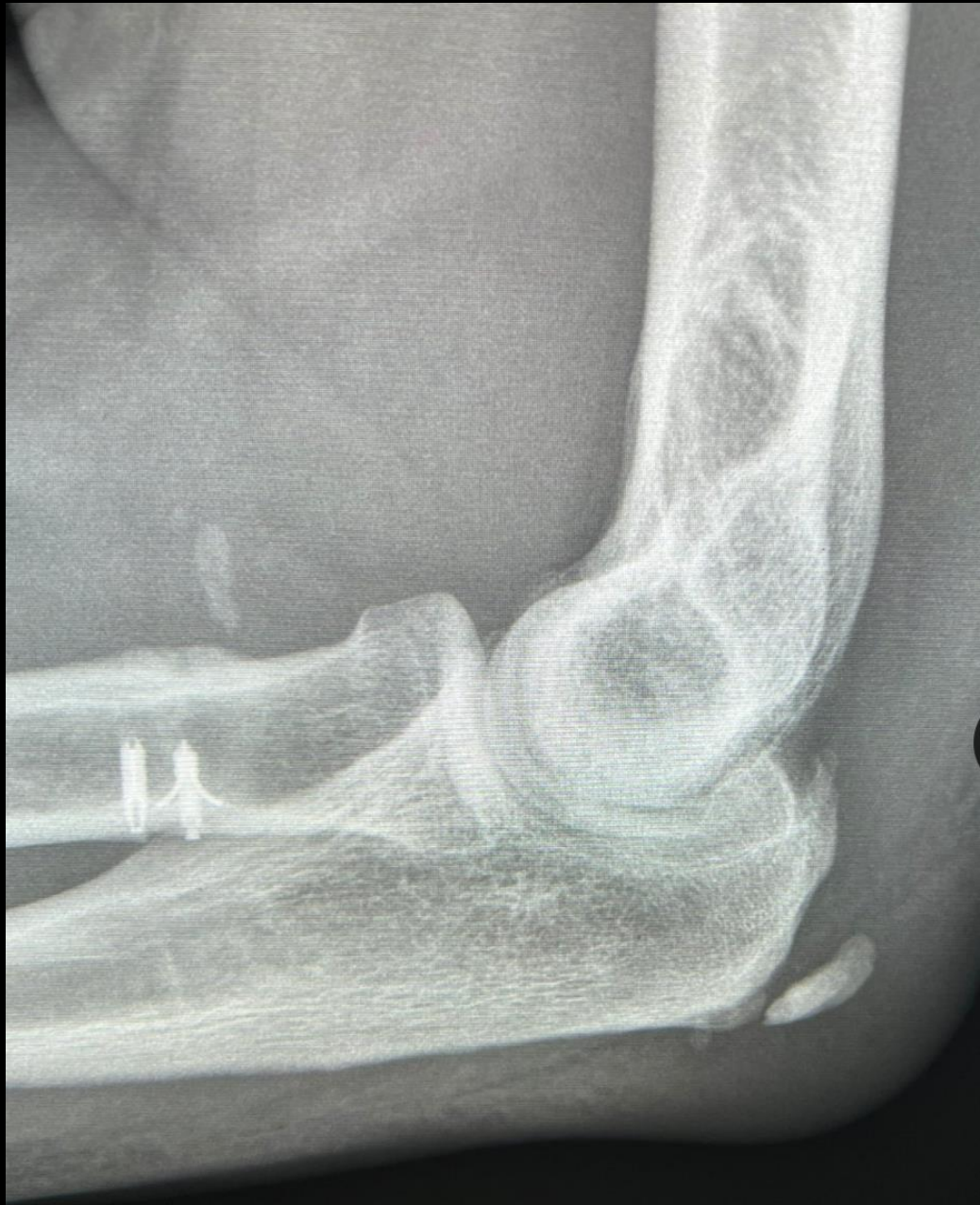


35 yr M

Power lifter

Previous elbow surgery

Now has acute posterior elbow pain !





What surgery was
done??

What is the cause
of present
symptoms??

1. Previous repair of distal biceps with metal suture anchors are seen in radius.

2. This is a case of olecranon spur fracture with bursitis.

There is associated olecranon bursitis.

---Spurs arise at regions of tendon and ligament insertion.

---Osteophytes at joints, mainly margins.

THANKYOU

