

MICOD – 09.08.2024

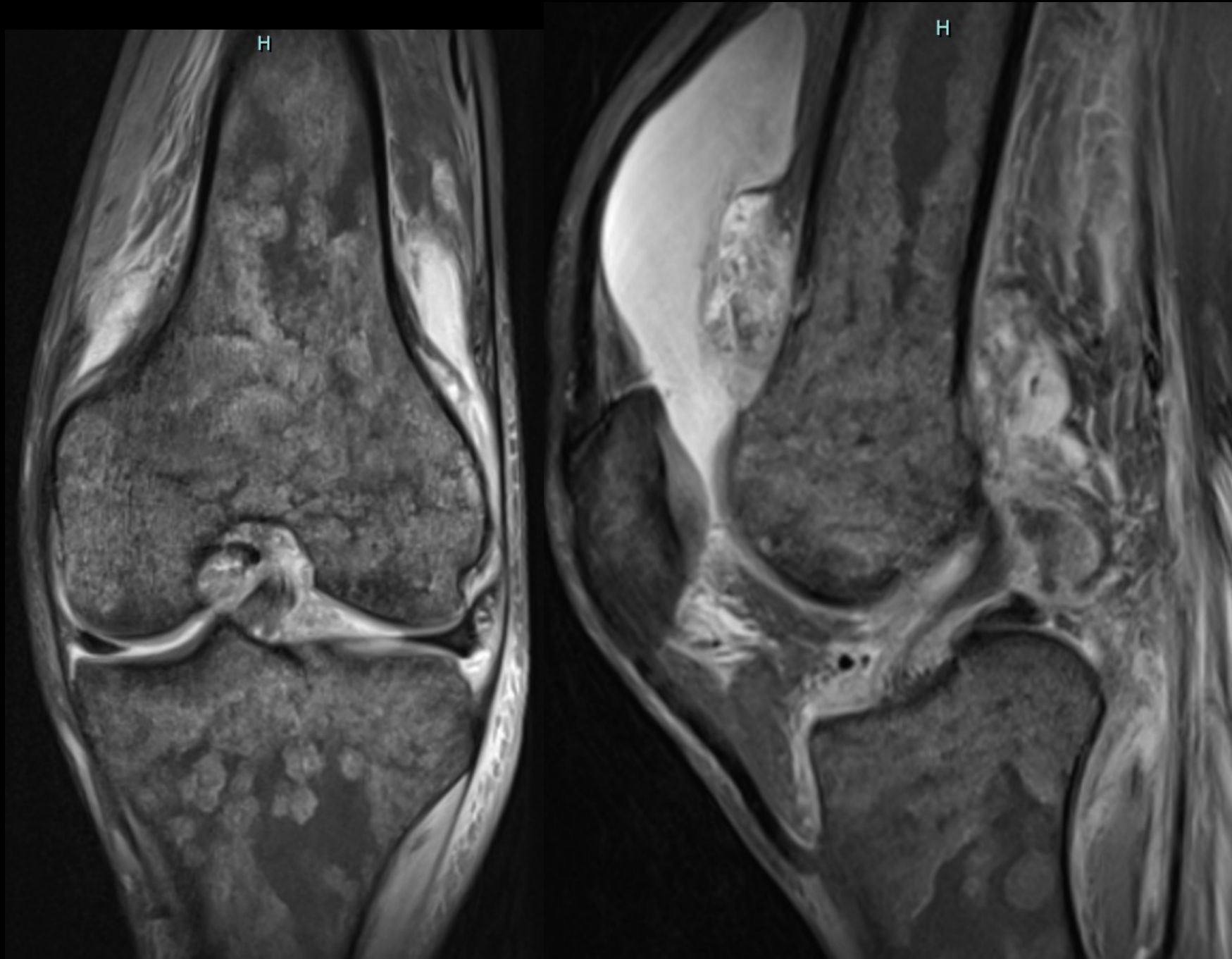
Case contributor – Dr. Darshana Sanghvi

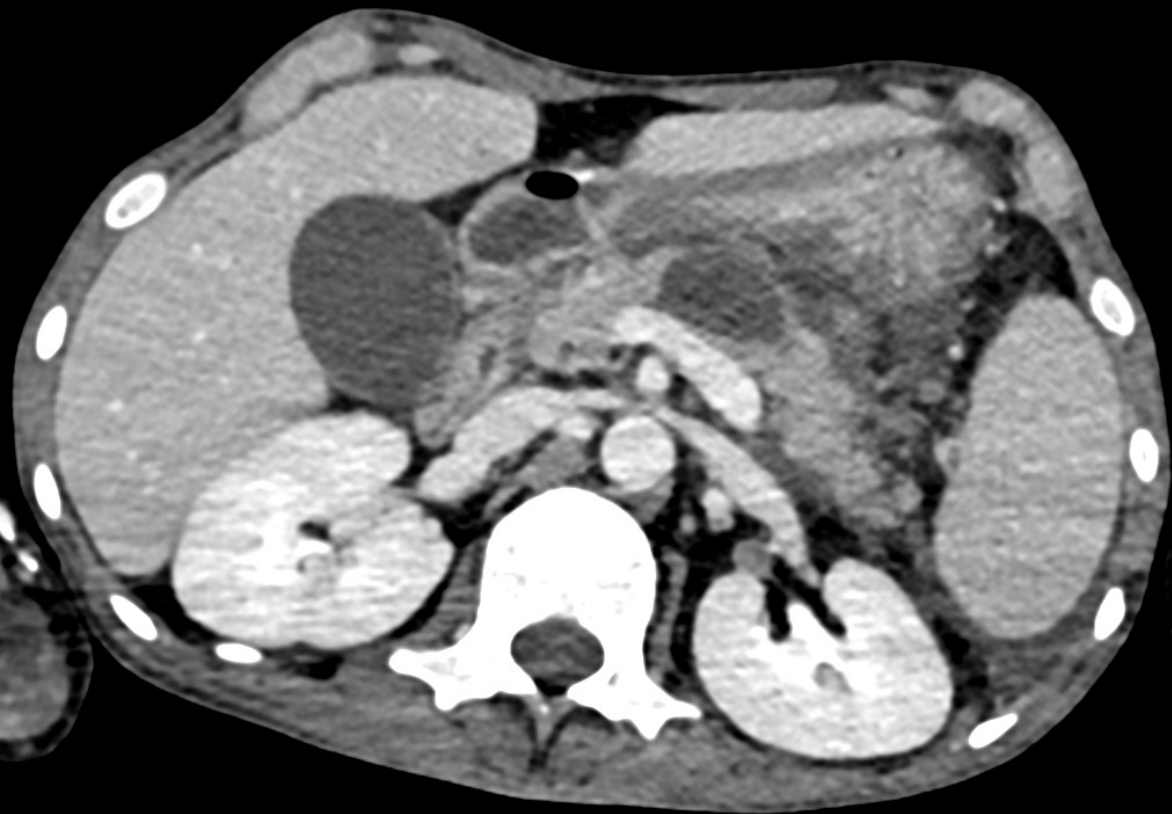# MI-COD

MSS INDIA- Case Of the Day

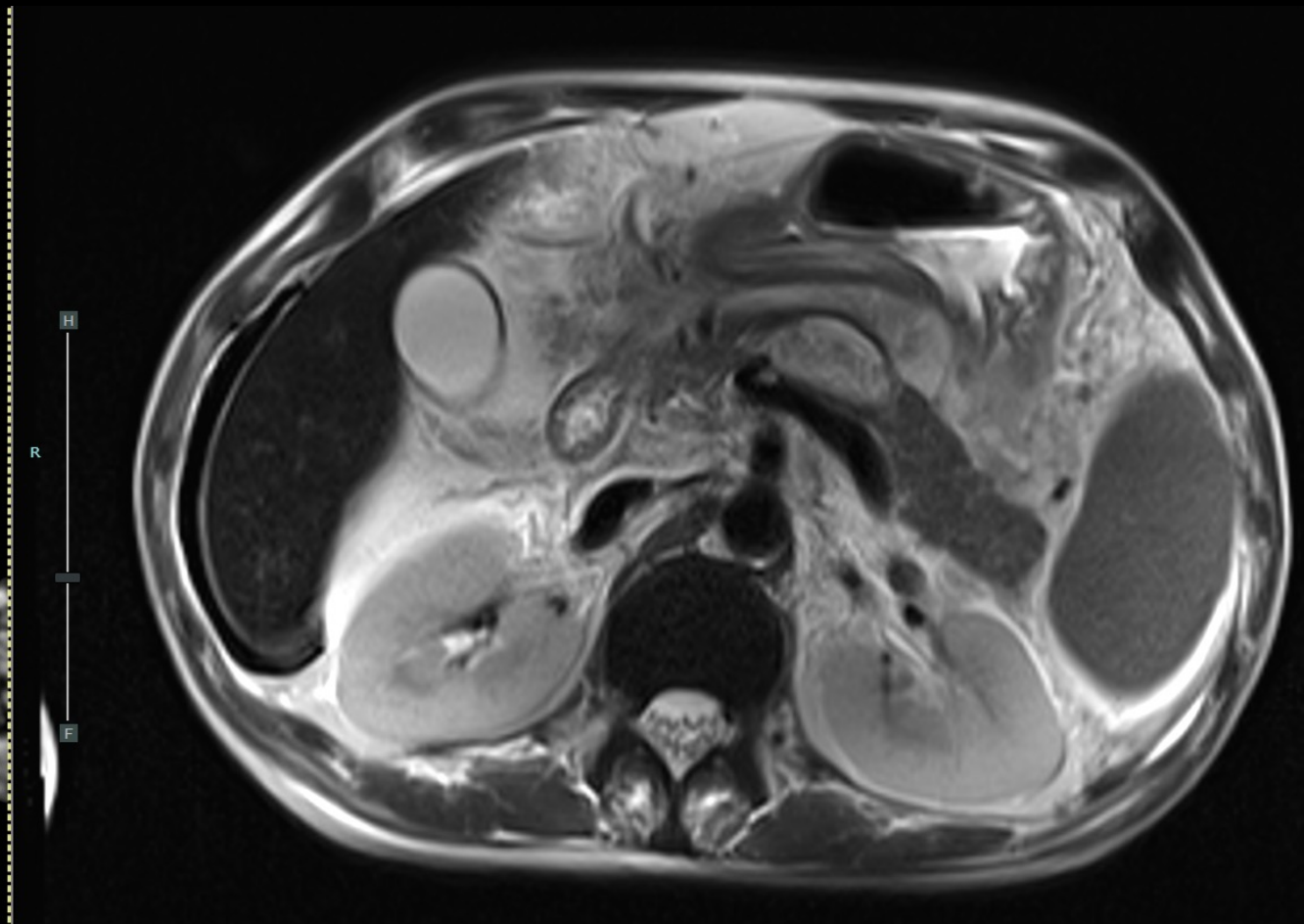


30/M with joint & abdominal pain





L R

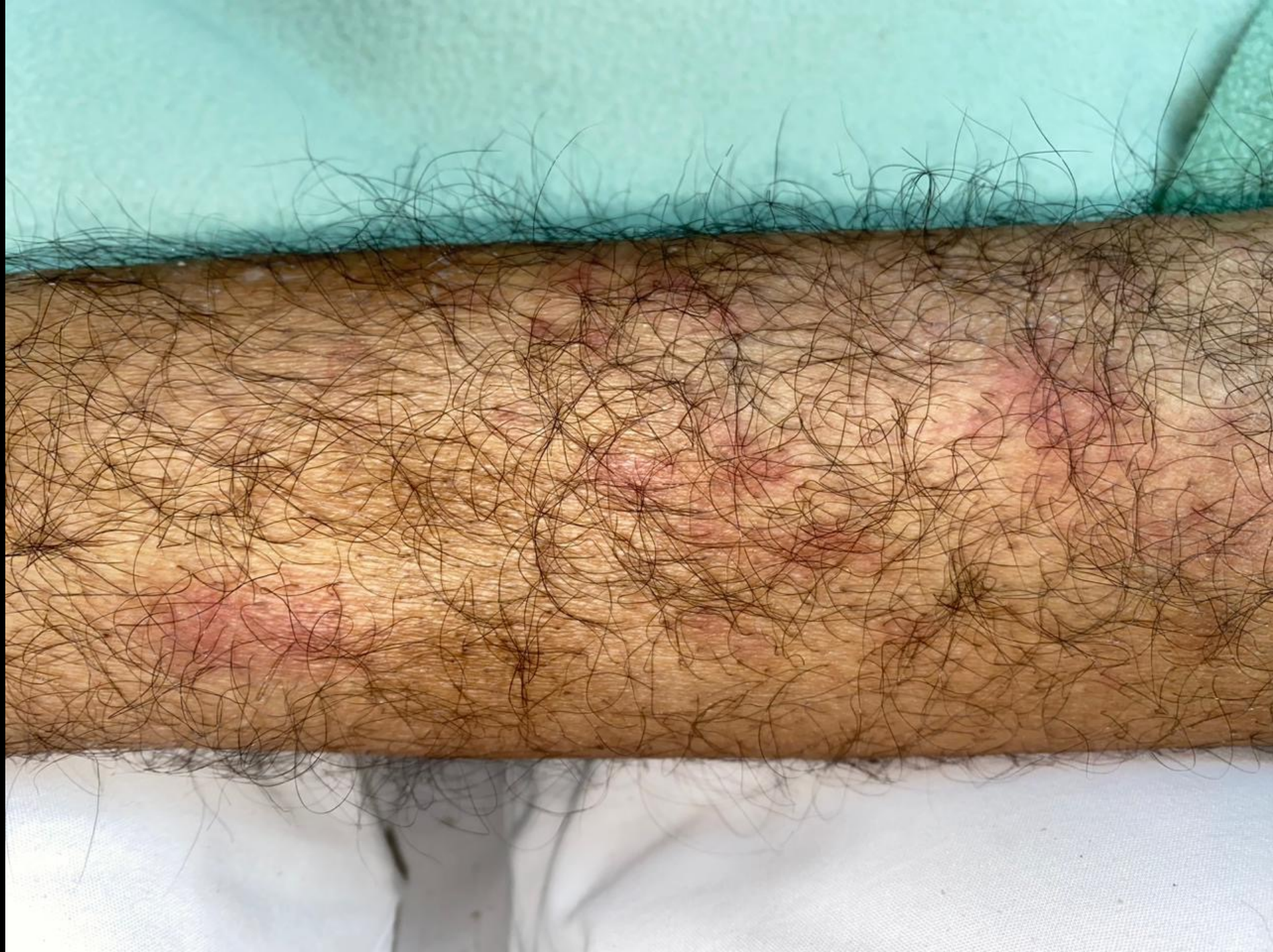

H

R

F





## Diagnosis: Pancreatitis, Panniculitis, and Polyarthrititis (PPP) syndrome

- Serum Lipase was 582 (N is 13-60)
- PPP syndrome occurs in the setting of pancreatitis or an underlying pancreatic mass. Patients may report mild or absent abdominal symptoms, making it difficult to diagnose
- Lipase enzyme leakage leads to multiple manifestations such as polyarthralgia, panniculitis, and bone necrosis due to tissue autodigestion