

MICOD – 05/08/2024

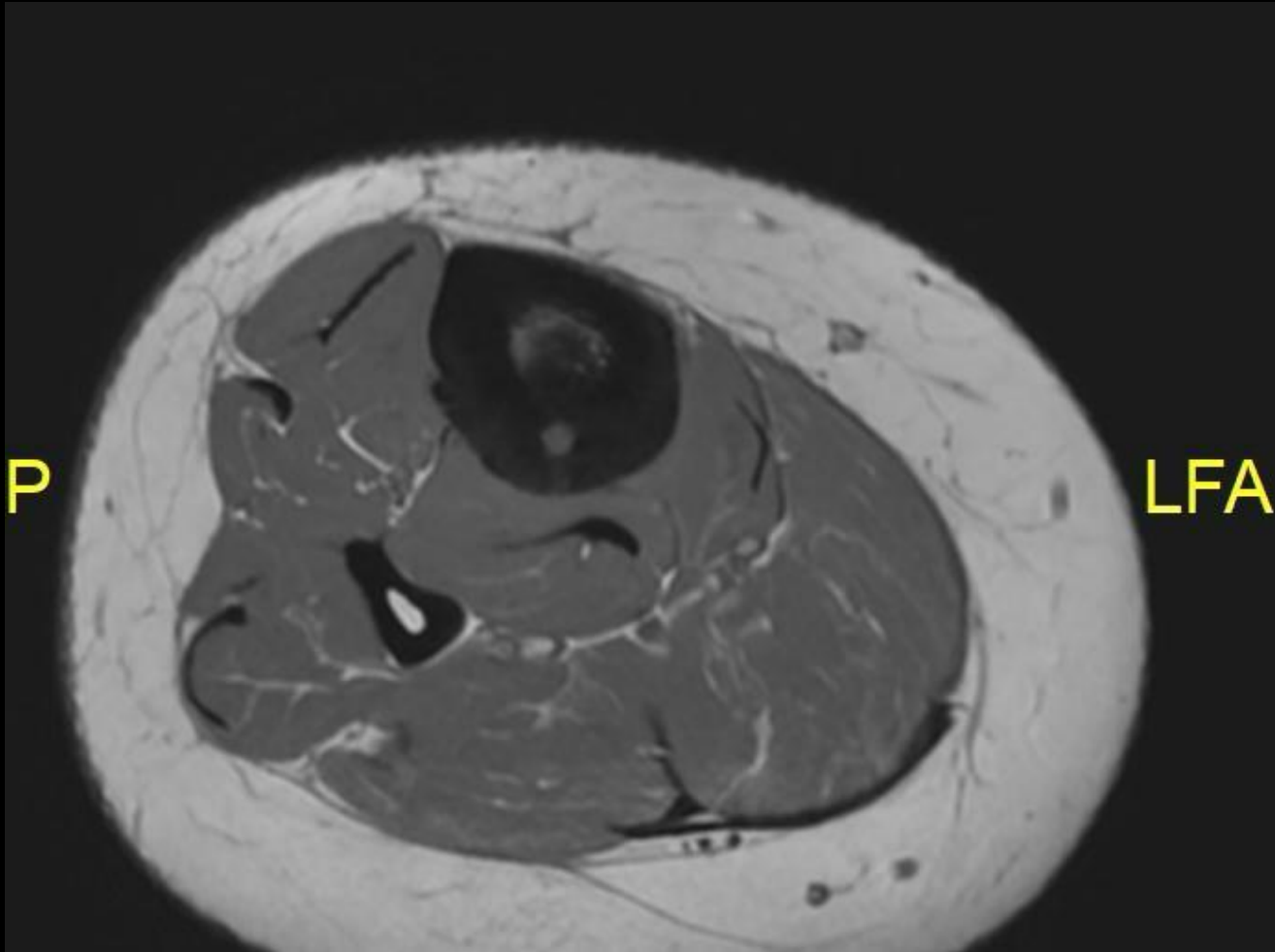
Case contributor – Dr. Rajesh Botchu

MI-COD

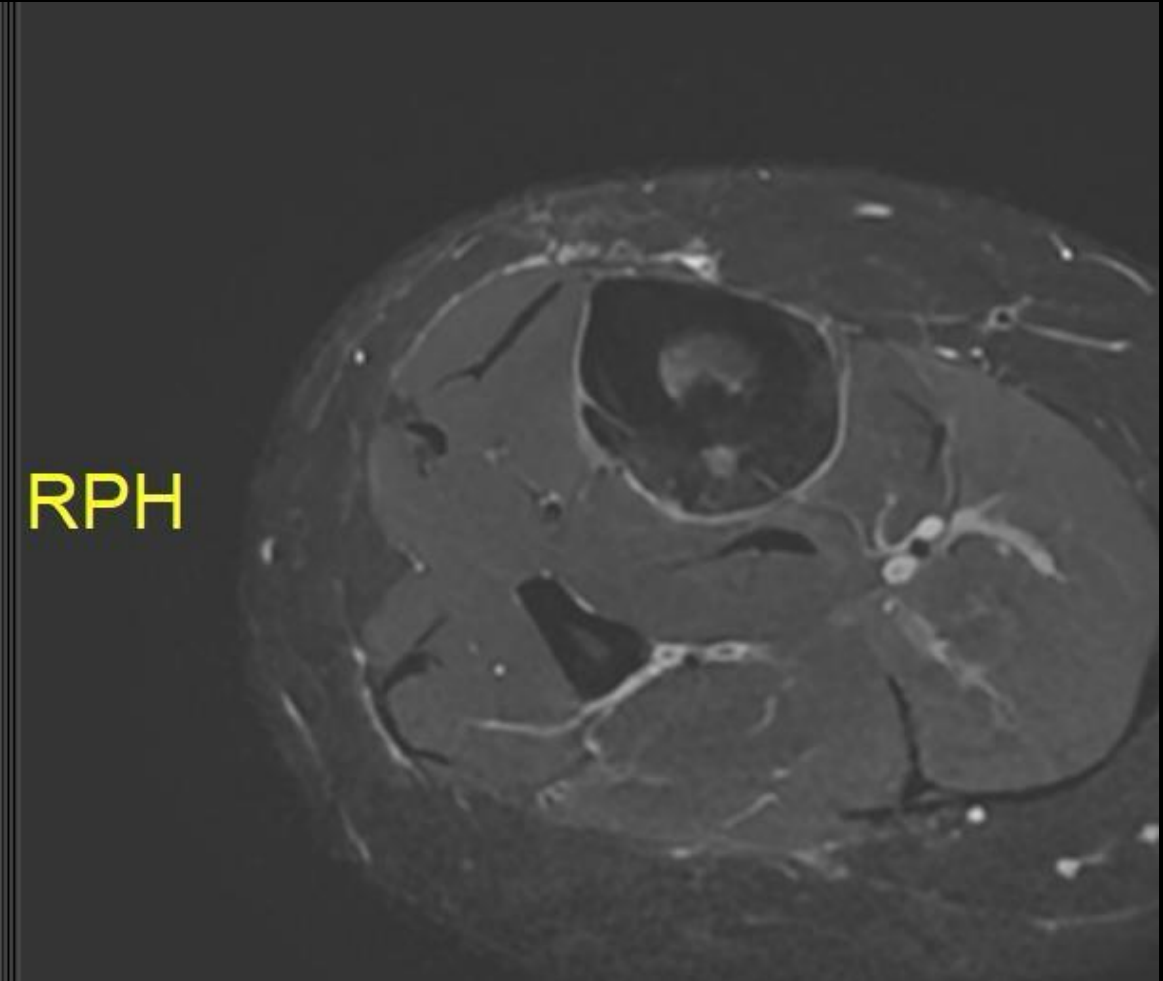
MSS INDIA- Case Of the Day



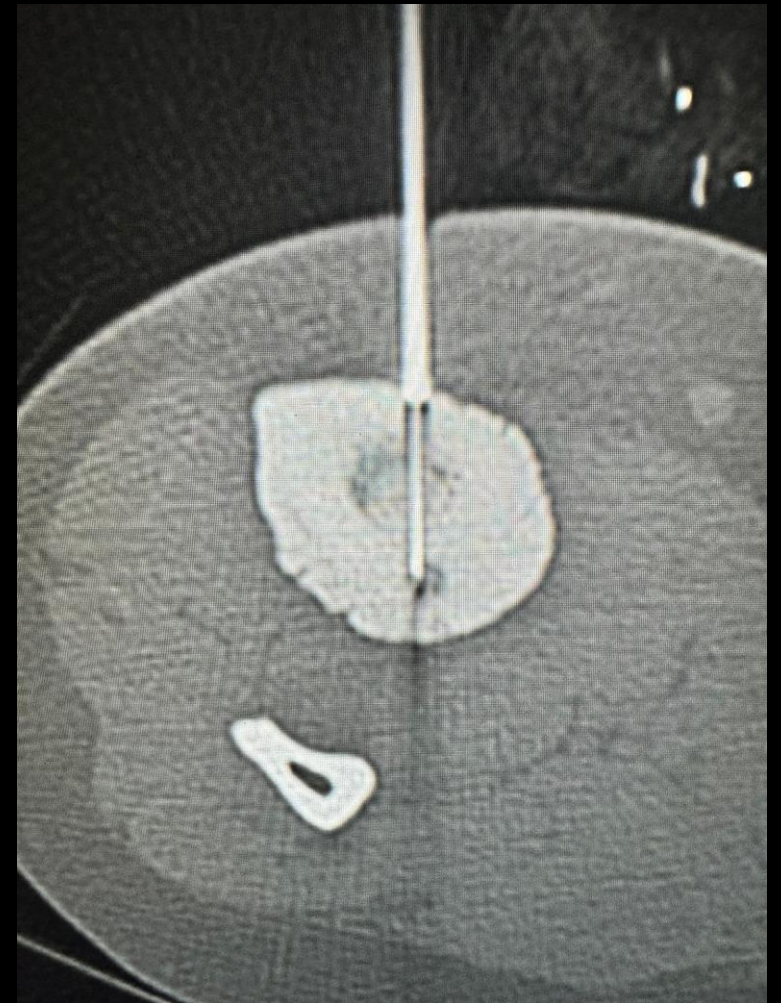
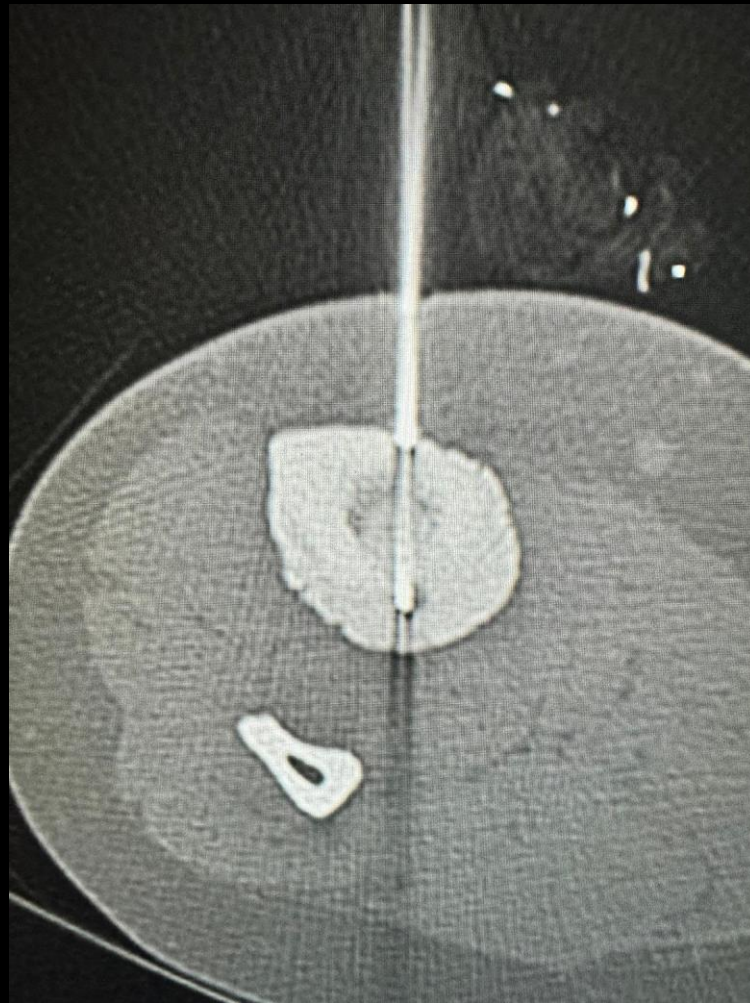
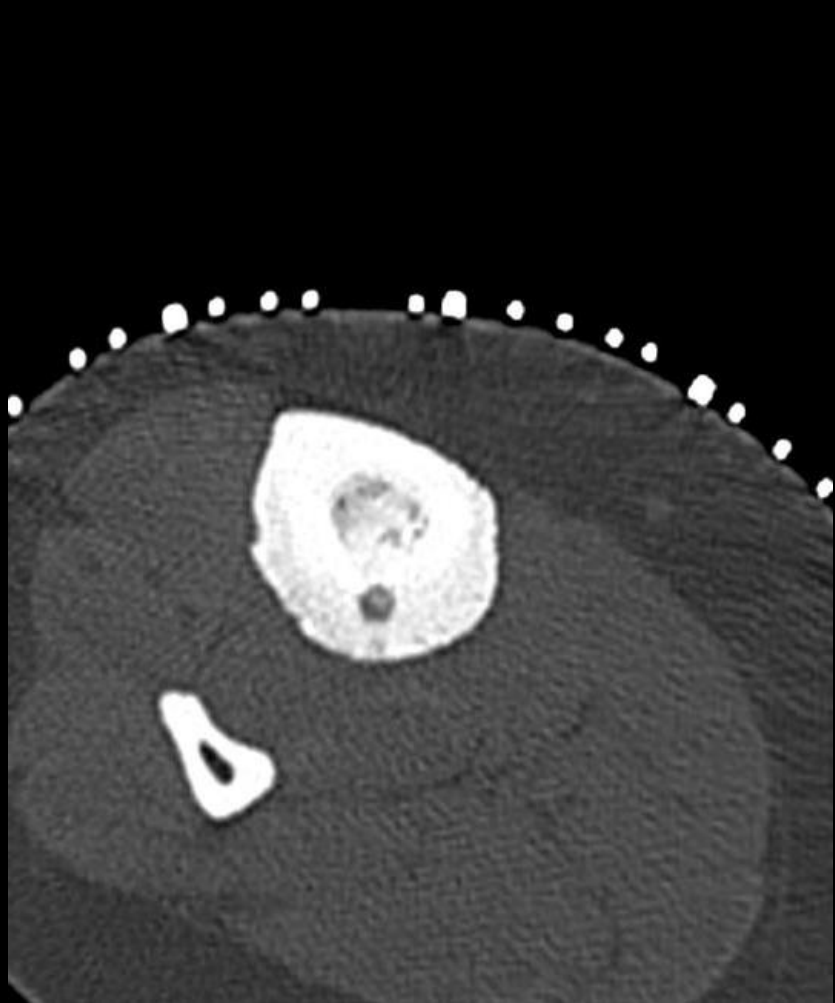
Osteoid osteoma and RFA next



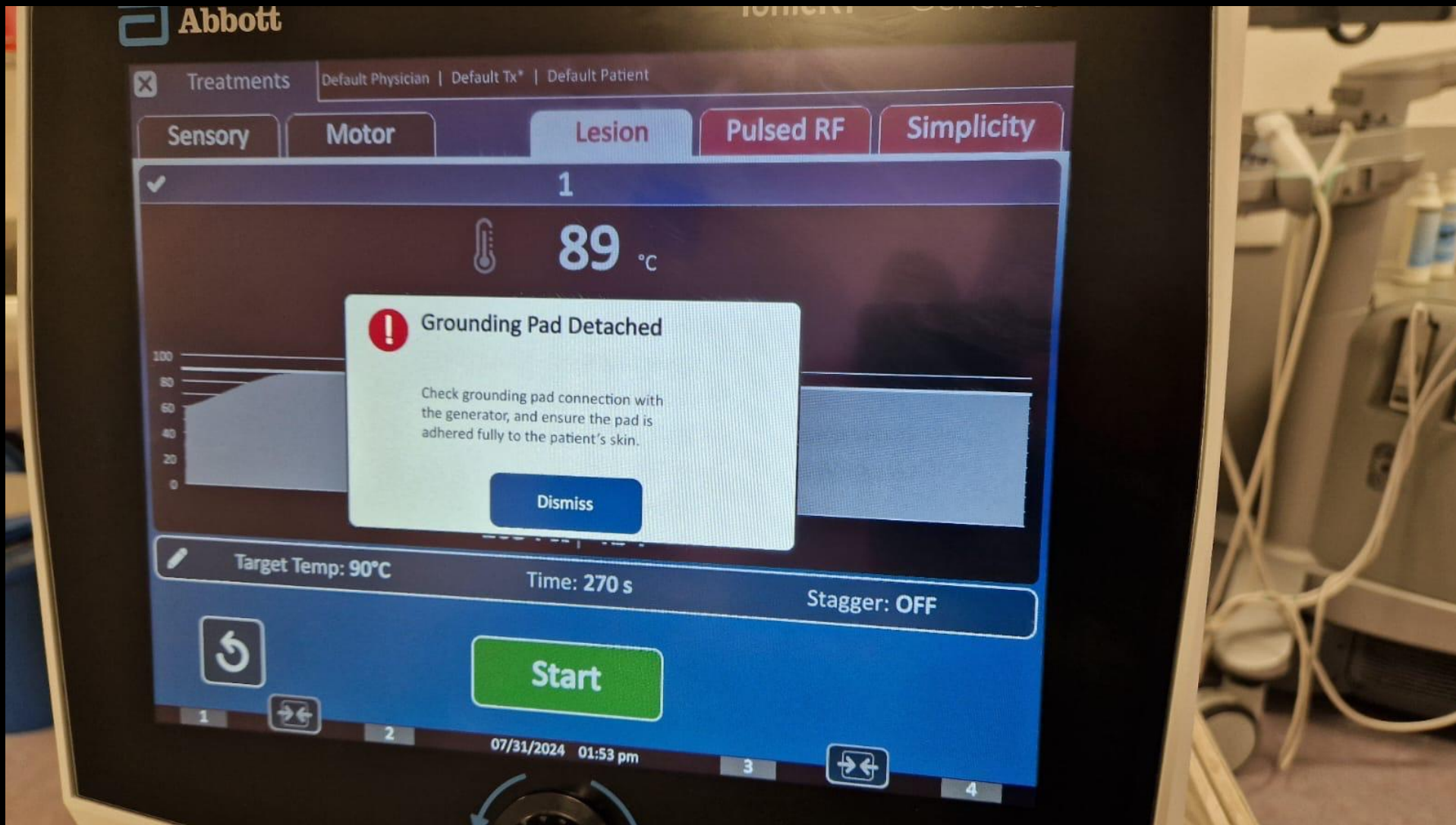
LFA RPH



During the procedure



Repeated error messages pop out in spite changing the device multiple times



What next?

Over drill and flush the trocar and then insert the RFA needle

