

MICOD – 23/07/2024

Case contributor – Dr. Nirmala Jambhekar

MI-COD

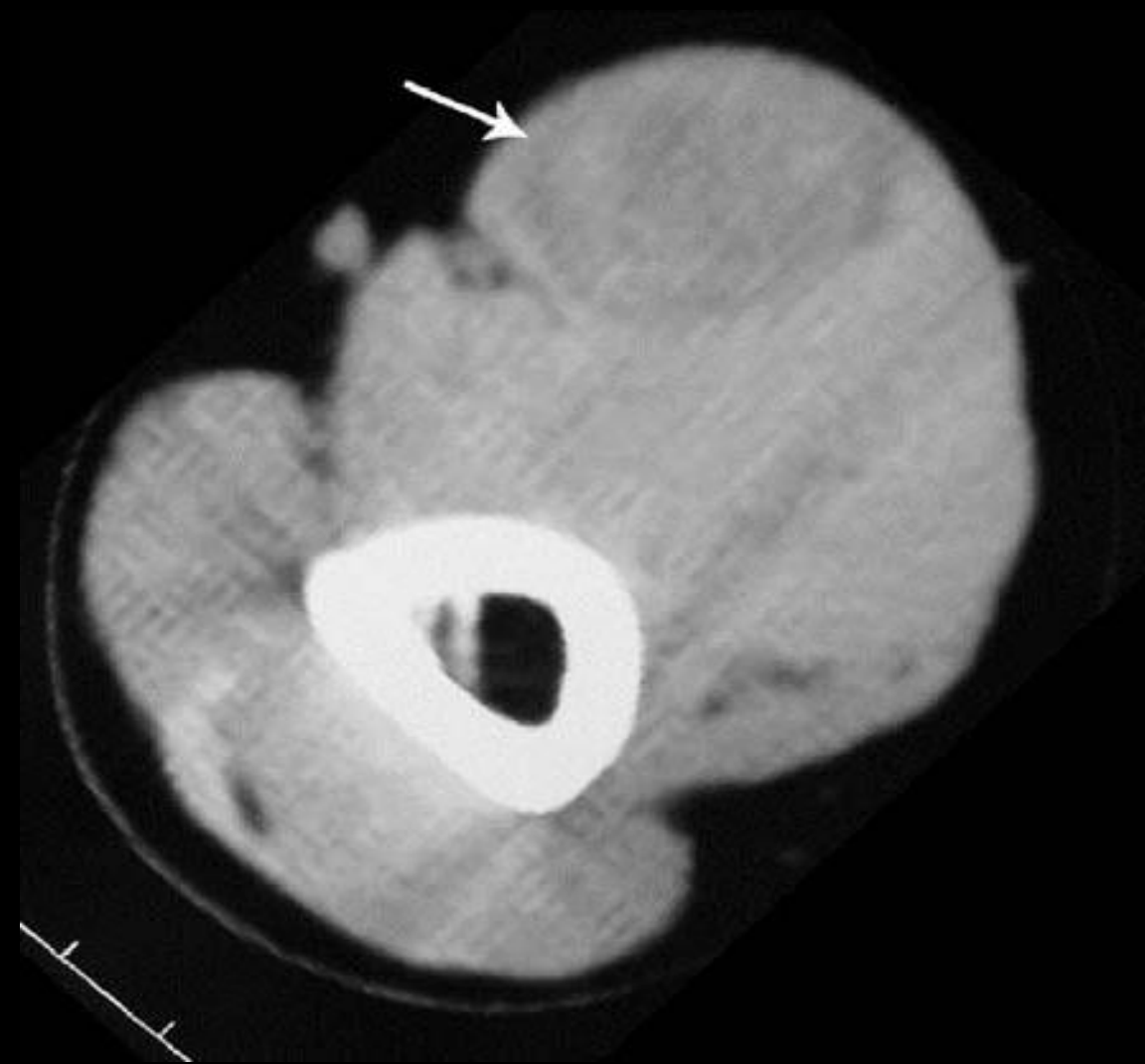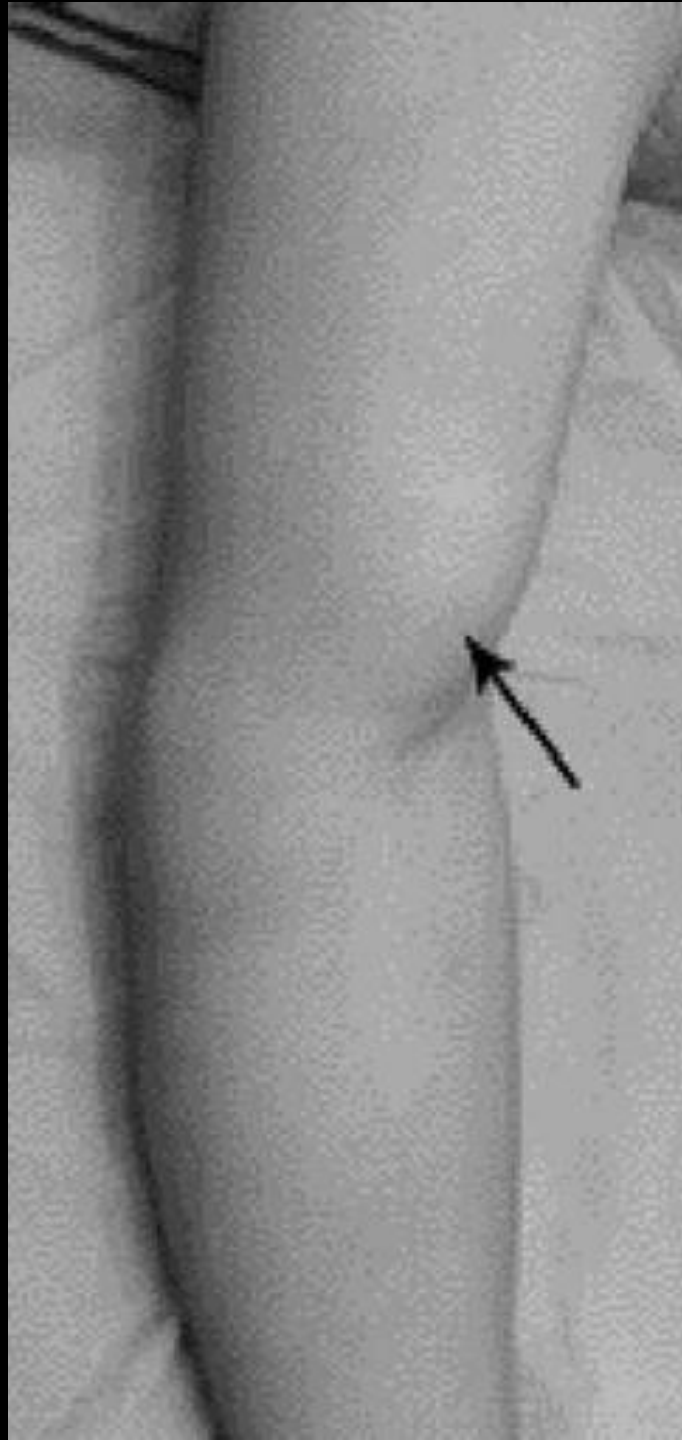
MSS INDIA- Case Of the Day



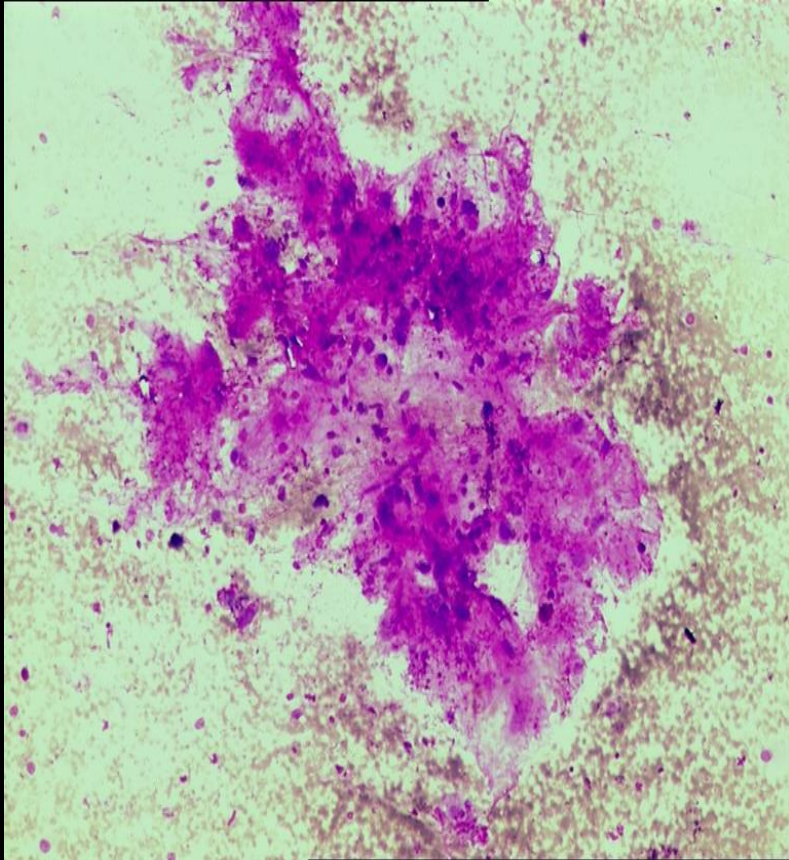
27-year-old gentleman with swelling over the left arm which first appeared 4 years earlier while lifting a heavy weight

Swelling was small and had remained static in size for the initial 2 years

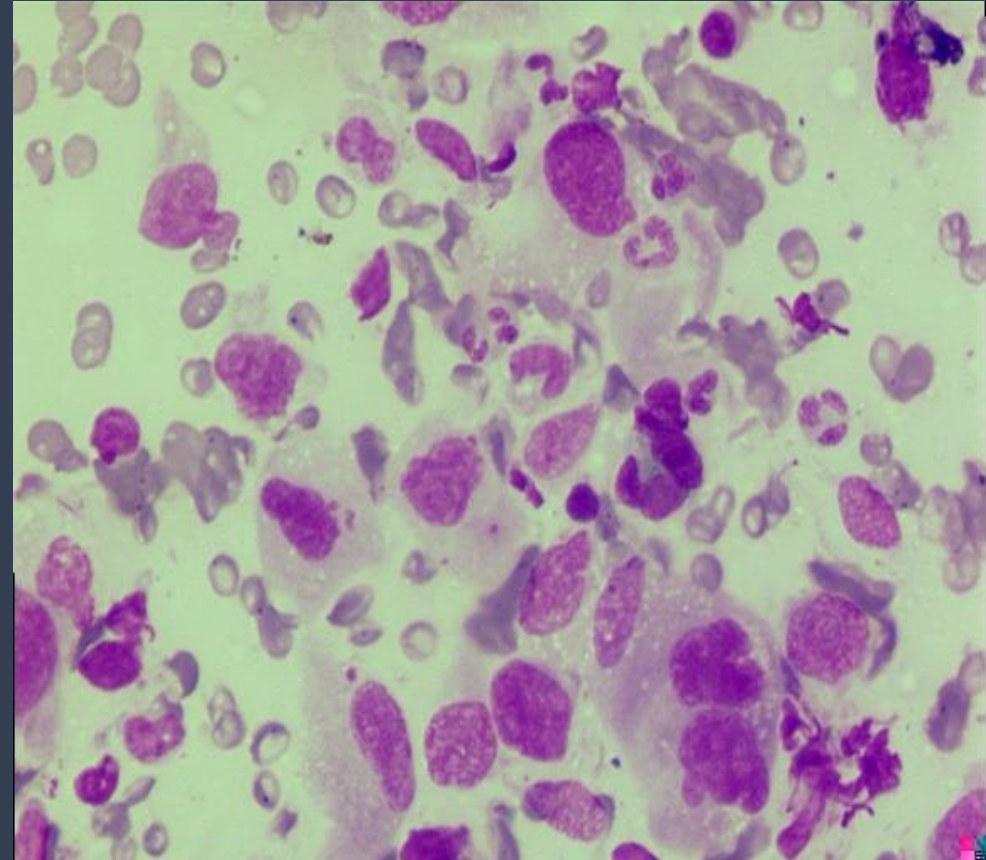
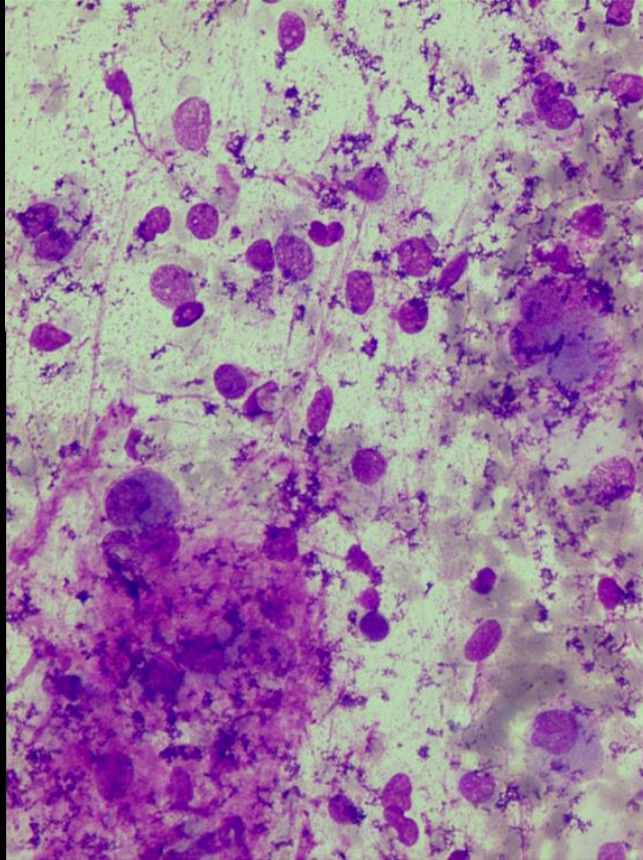
Swelling was increasing during past 2 years and had become painful

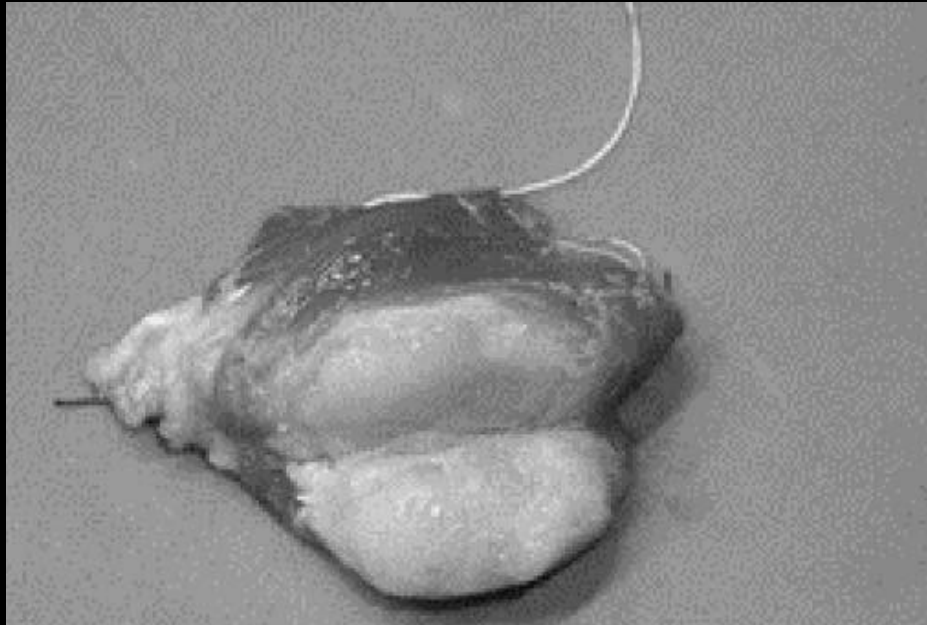


*FNAC reported elsewhere as
soft-tissue sarcoma with
Myxoid stroma*

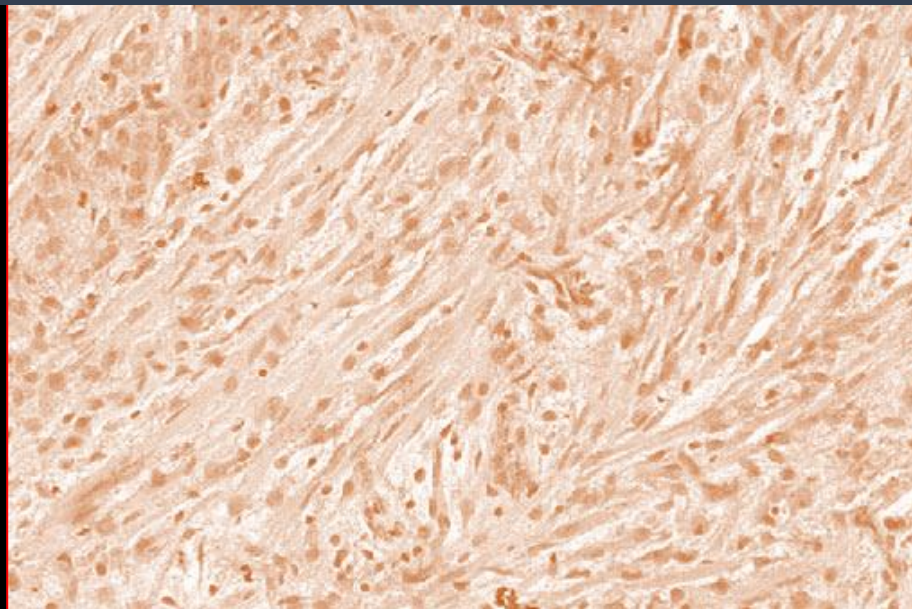


*FNAC reviewed at TMH
s/o possibly a sarcoma*





Mass was excised



Unusual late sequel of ruptured distal tendon of biceps brachii mimicking a soft-tissue tumor

Injury and repair can be mistaken for malignancy such as Proliferative fasciitis ,
Proliferative Myositis , Myositis
Ossificans , Florid reactive periostitis ,
Fracture callus

These are loosely termed as
“ **Pseudosarcomatous lesions** ”

Sometimes benign soft tissue and bone tumours such as ancient Schwannomas ,
Symplastic Leiomyomas, Osteoblastomas
may focally show large hyperchromatic
nuclei leading to an **overdiagnosis of malignancy.**

These are then loosely termed
“ **Pseudomalignant lesions** ”

Important Learning issue

Awareness is necessary to avoid overdiagnosis and overtreatment