

MICOD – 22/07/2024

Case contributor – Dr. Harmeet Kaur

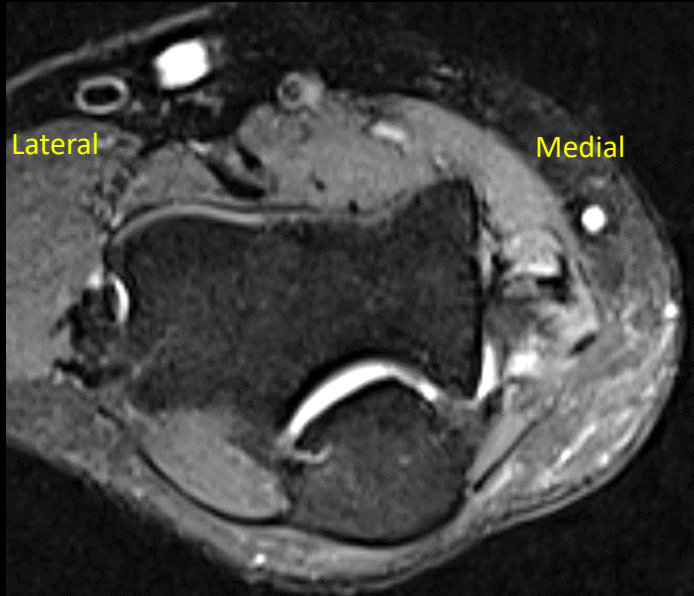
MI-COD

MSS INDIA- Case Of the Day

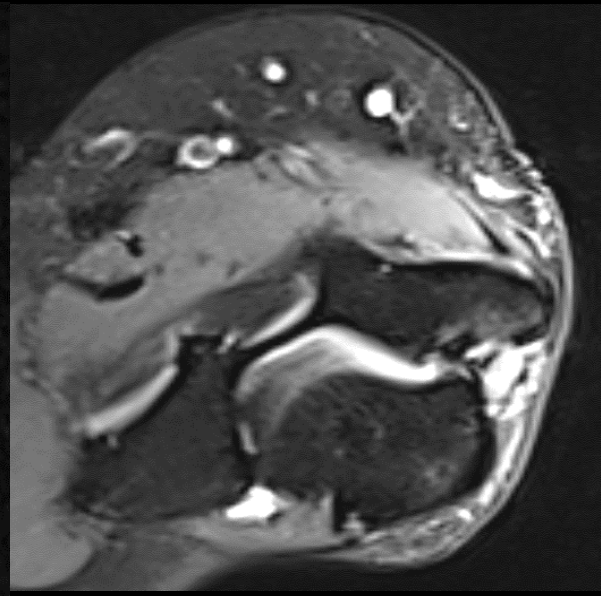


Medial epicondylitis

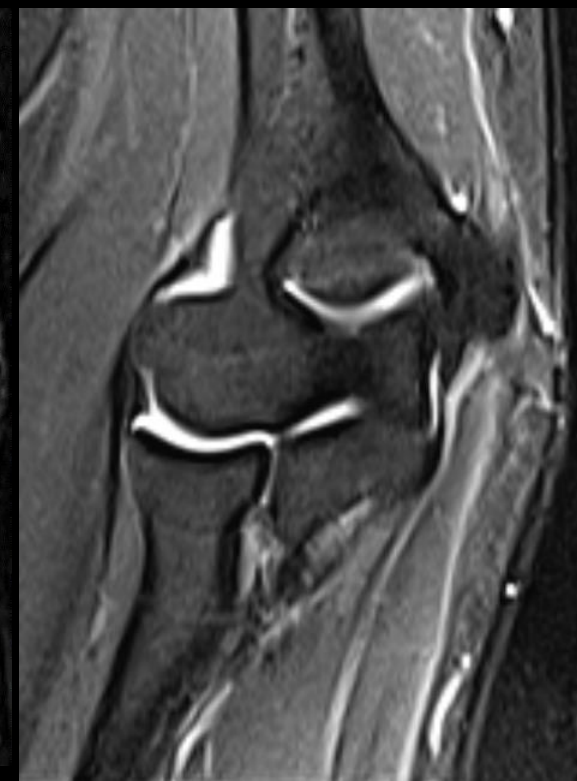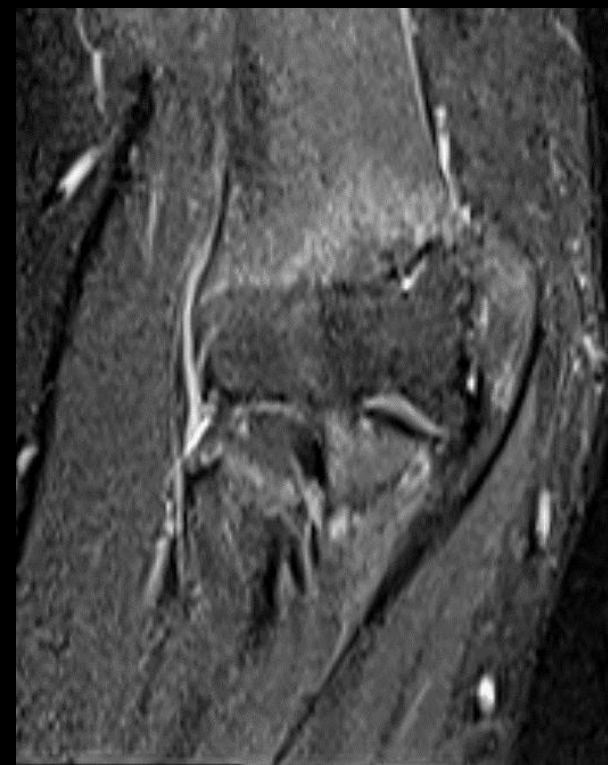Plain MRI



STIR (Axial)



PDFS (Axial)



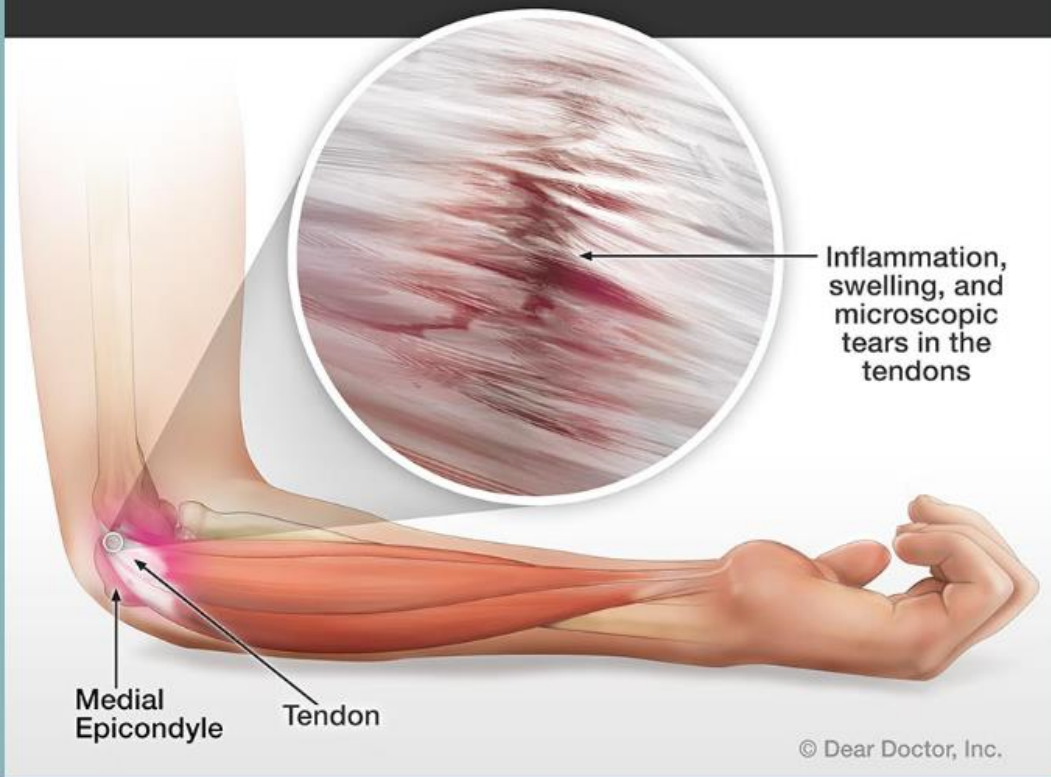
STIR Coronal

Medial epicondylitis

Konarski W et al. *USG in the Differential Diagnosis of Medial Epicondylalgia and Medial Elbow Pain-Imaging Findings and Narrative Literature Review. Healthcare (Basel). 2022 Aug 13*

Golfer's Elbow

Golfer's elbow is a repetitive stress injury that can cause inflammation, swelling, and microscopic tears in the tendons that connect your forearm to the inside of your elbow.



- Commonly known as “the golfer’s elbow”, typically develops due to repetitive forearm movements and weight-bearing activities
- US imaging, with a sensitivity and specificity of 95% and 92%, respectively, remains a practical and accessible alternative to MRI
- Differential diagnosis includes pathologies of the medial compartment of the elbow,
 - ✓ snapping triceps
 - ✓ medial collateral ligament injury
 - ✓ cubital tunnel neuropathy