

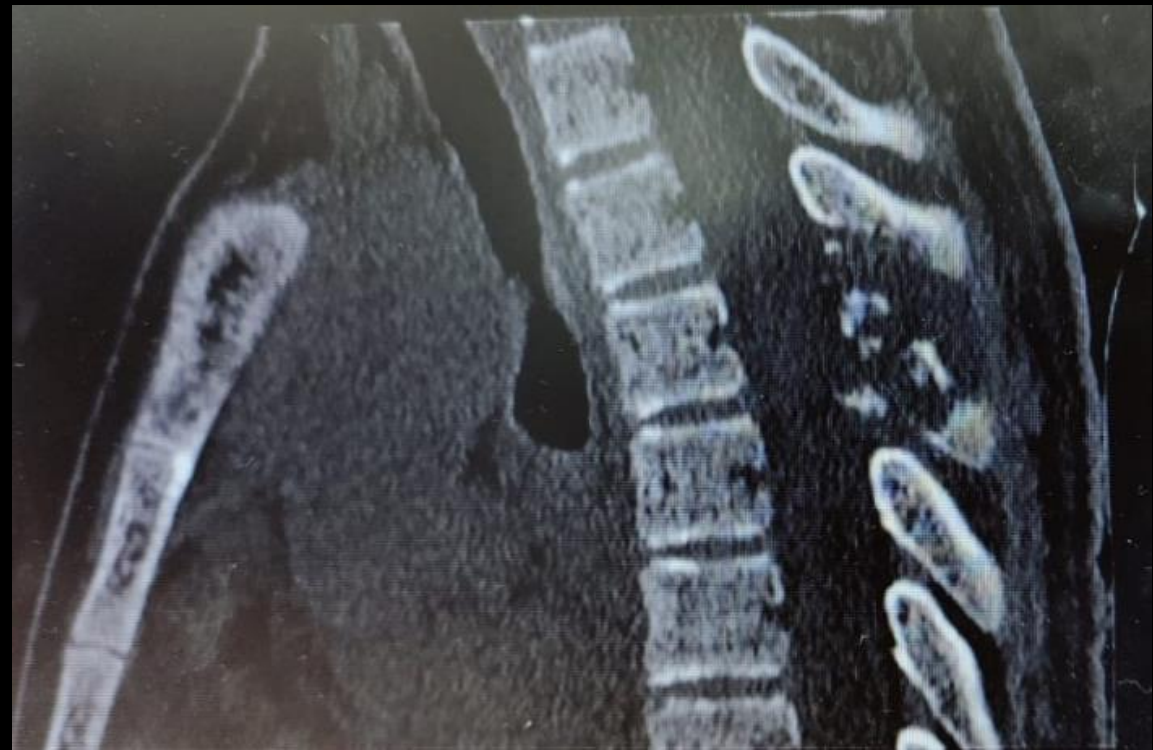
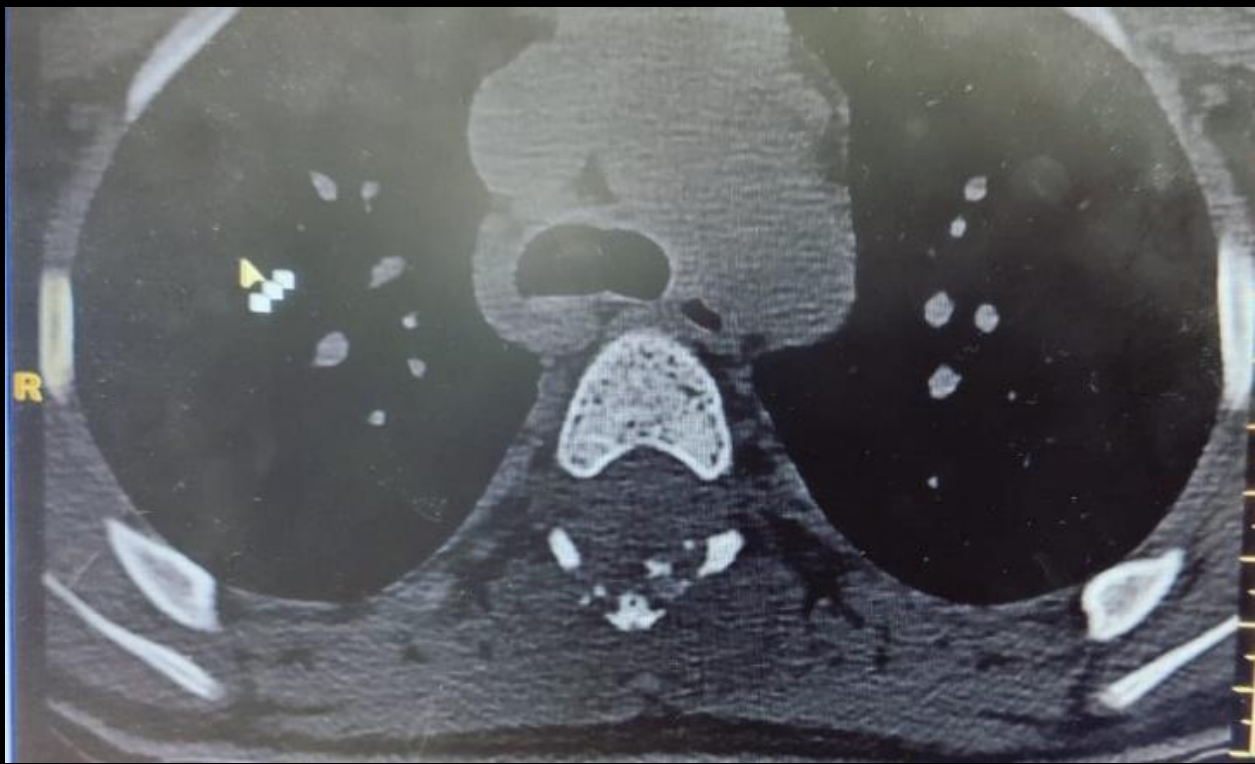MICOD -03/07/2024

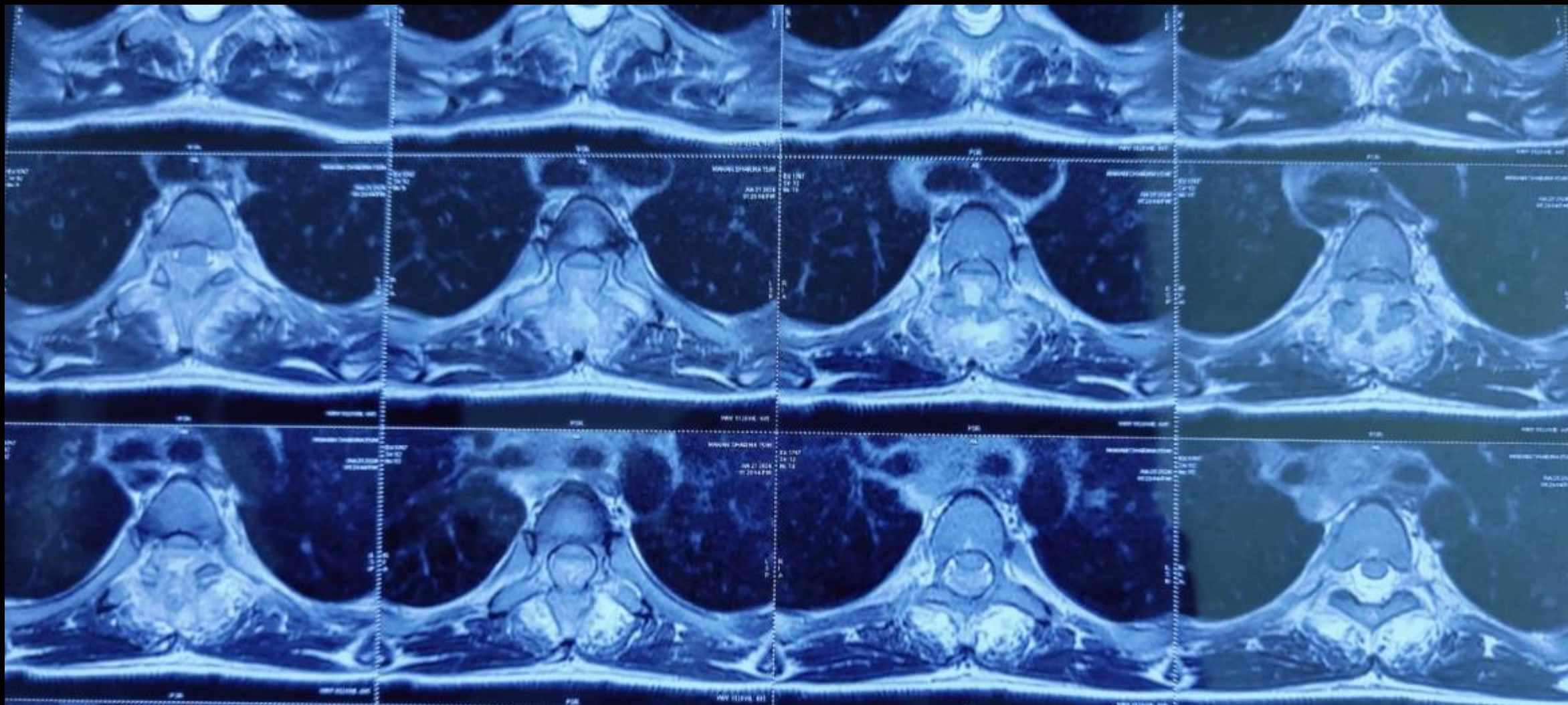
Case contributor – Dr. Sonal Saran

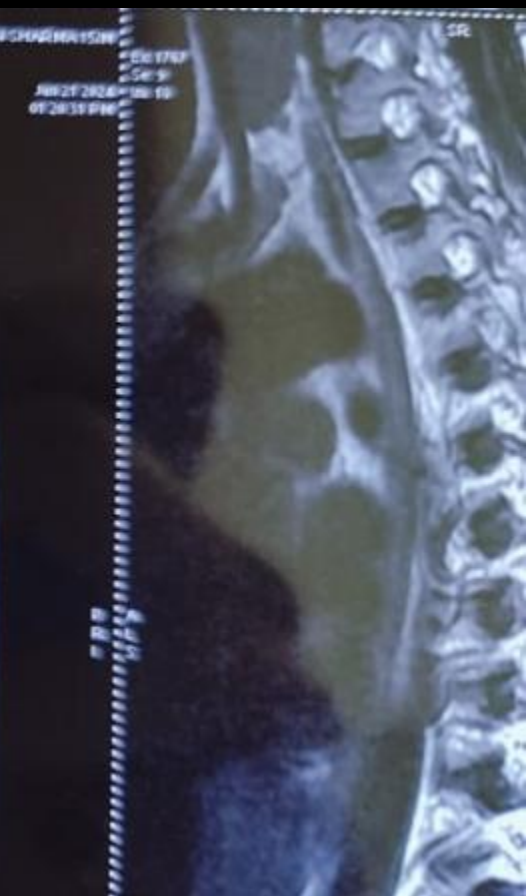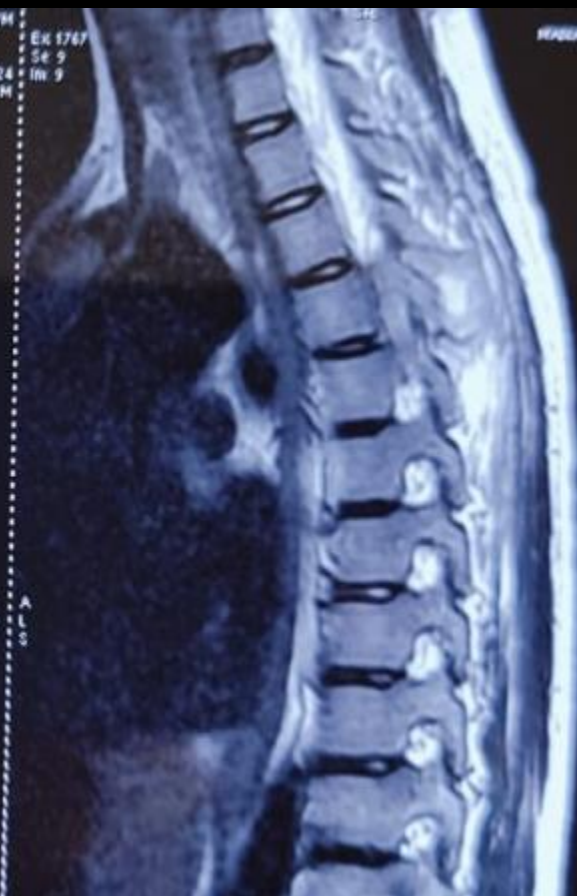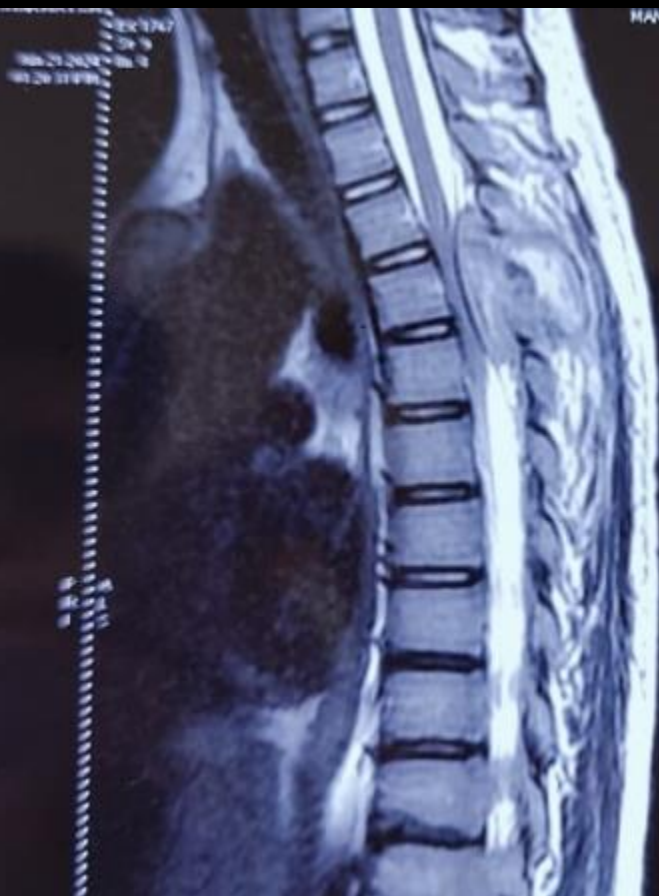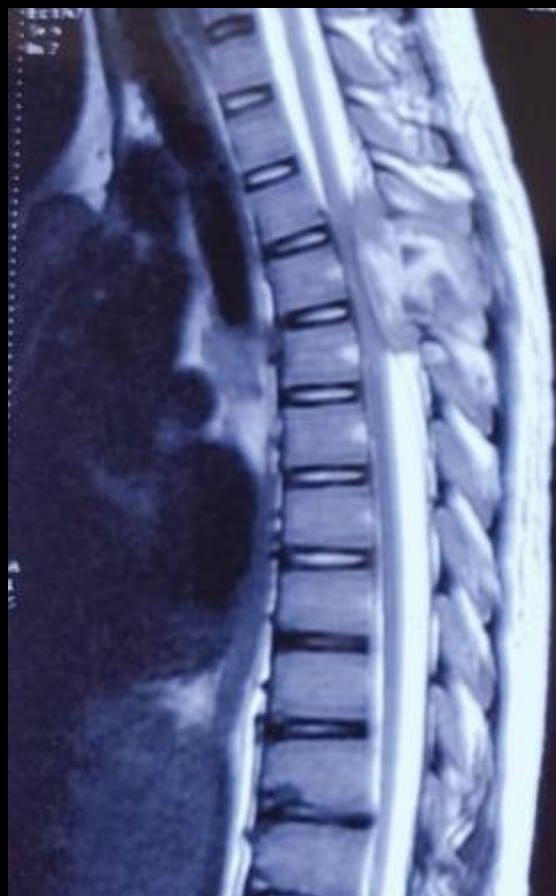MI-COD

MSS INDIA- Case Of the Day










EX 1767
SE 9
Im 9
Jul 21 2024
01:20:31 PM

MANAN SHARMA 15/M
EX 1767
SE 9
Im 9
Jul 21 2024
01:20:31 PM

EX 1767
SE 9
Im 9
Jul 21 2024
01:20:31 PM

P
R
I
A
L
S

Diagnosis??



ANSWER : NEURAL ARCH TB.

- The morbidity associated with this disease is serious.
- Routine radiographs can only indicate the level of the disease and the loss of disc space, but cannot define the full extent of the lesion.
- Computed tomography shows details of the tuberculous involvement of the neural arch, as well as the vertebral body and spinal canal; the site and extent of the soft tissue lesions can also be seen.
- It is essential for evaluation of the neural arch involvement which will enable the clinician to select the appropriate treatment, and so prevent neurological complications.
- MRI shows the extent and level of soft tissue and cord involvement.



THANKYOU