

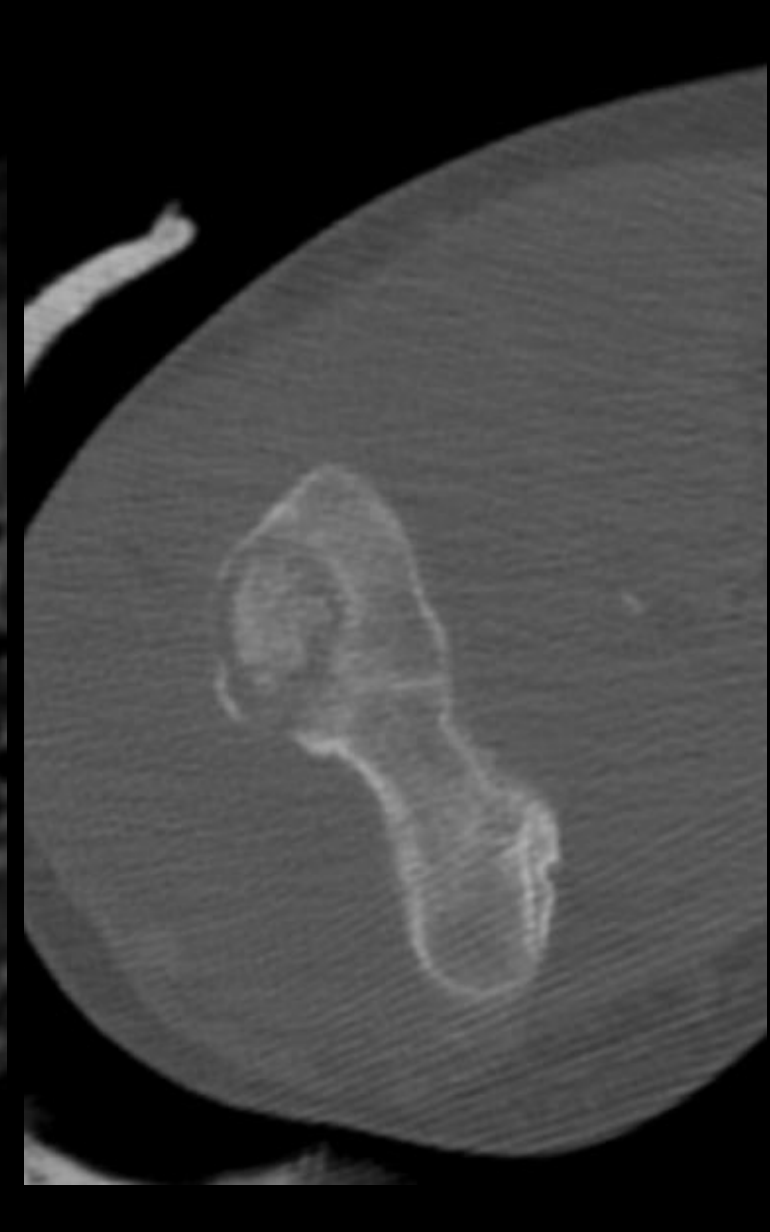
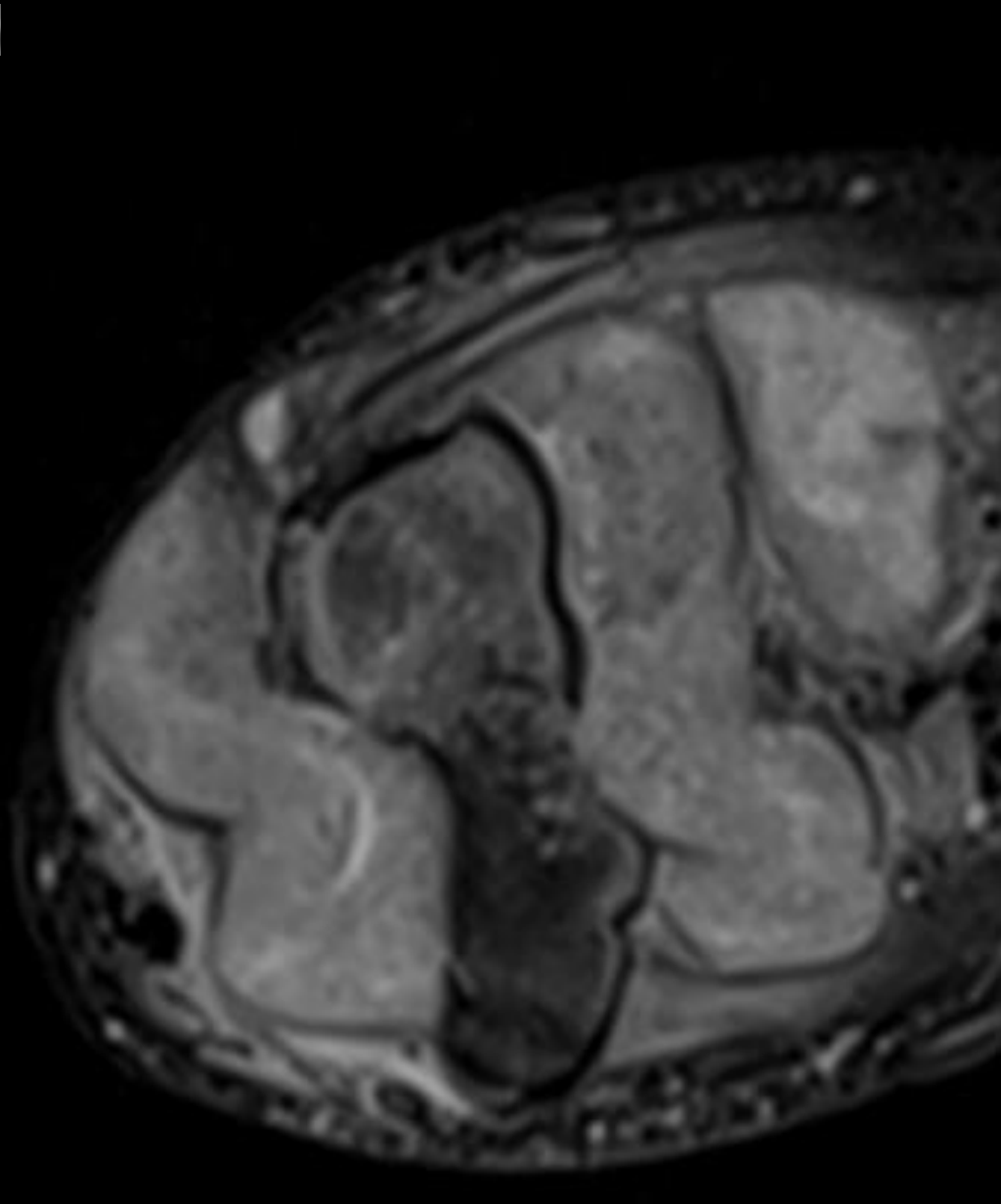
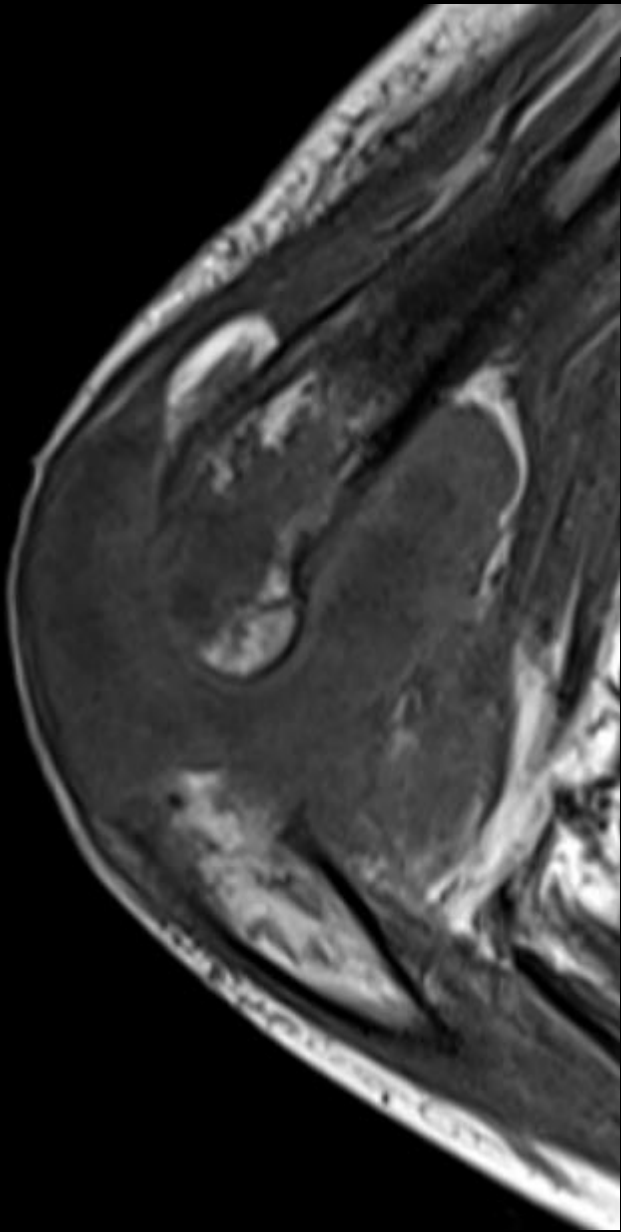
MICOD – 02/07/2024

Case contributor – Dr. Praveen Kumar Chinniah

MI-COD

MSS INDIA- Case Of the Day





T1 penumbra sign in MR images and button sequestrum in distal humerus - Tuberculosis

Button sequestrum

A small sequestrum of devascularised bone surrounded by lucency

- ✓ Osteomyelitis
- ✓ Eosinophilic granuloma
- ✓ Fibrosarcoma
- ✓ Lymphoma

Krasnokutsky MV. The button sequestrum sign. *Radiology*. 2005 Sep;236(3):1026-7

Penumbra sign

- Peripheral rim of T1W hyperintense signal relative to the low-signal abscess cavity (bone, soft tissue & in synovium) on pre-contrast images
- Due to the high protein content in granulation tissue

Alaia EF et al. MRI nomenclature for musculoskeletal infection. *Skeletal Radiol*. 2021 Dec;50(12):2319-2347.



Thank you