

MICOD – 28/06/2024

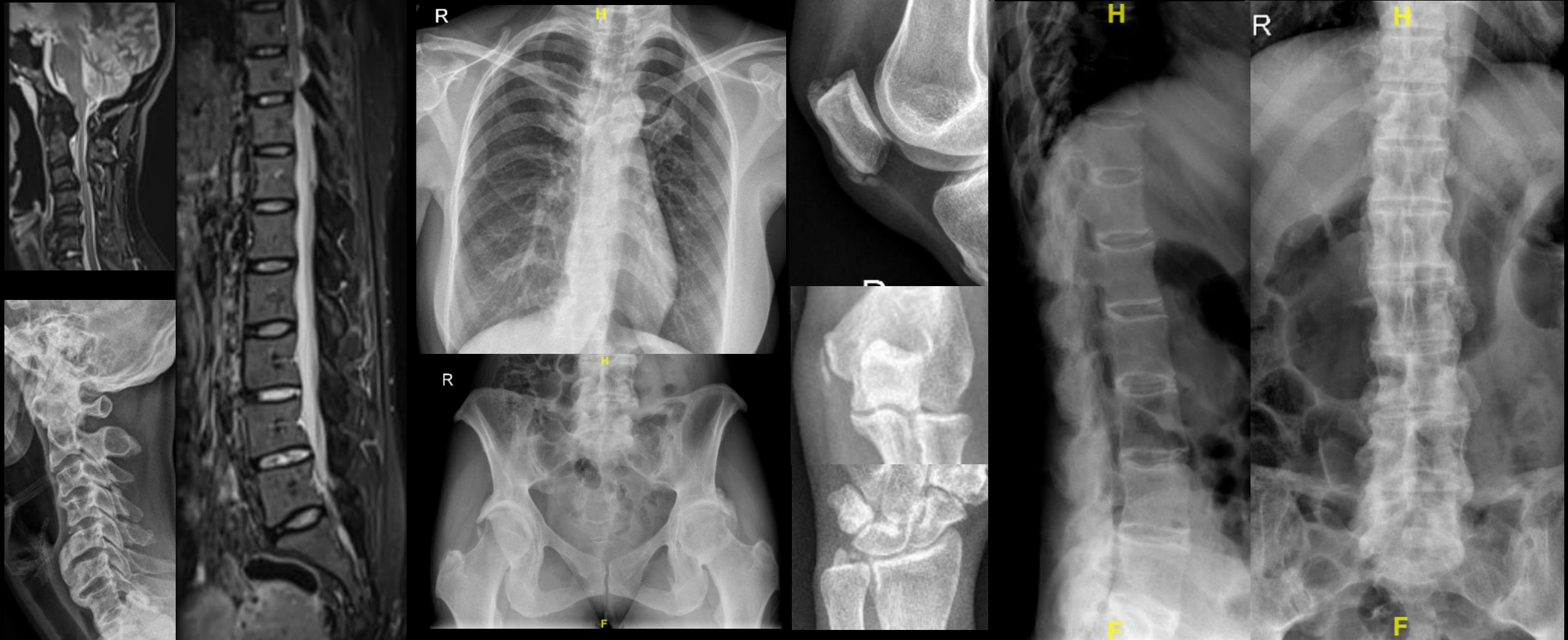
Case contributor – Dr. Praveen Kumar Chinniah

MI-COD

MSS INDIA- Case Of the Day




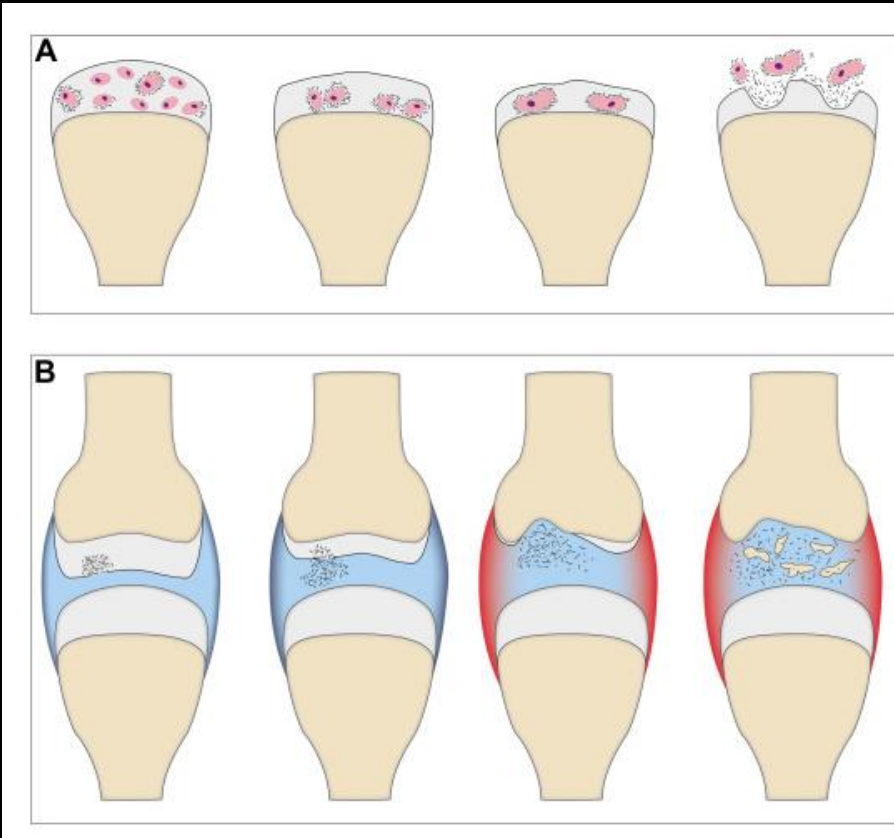
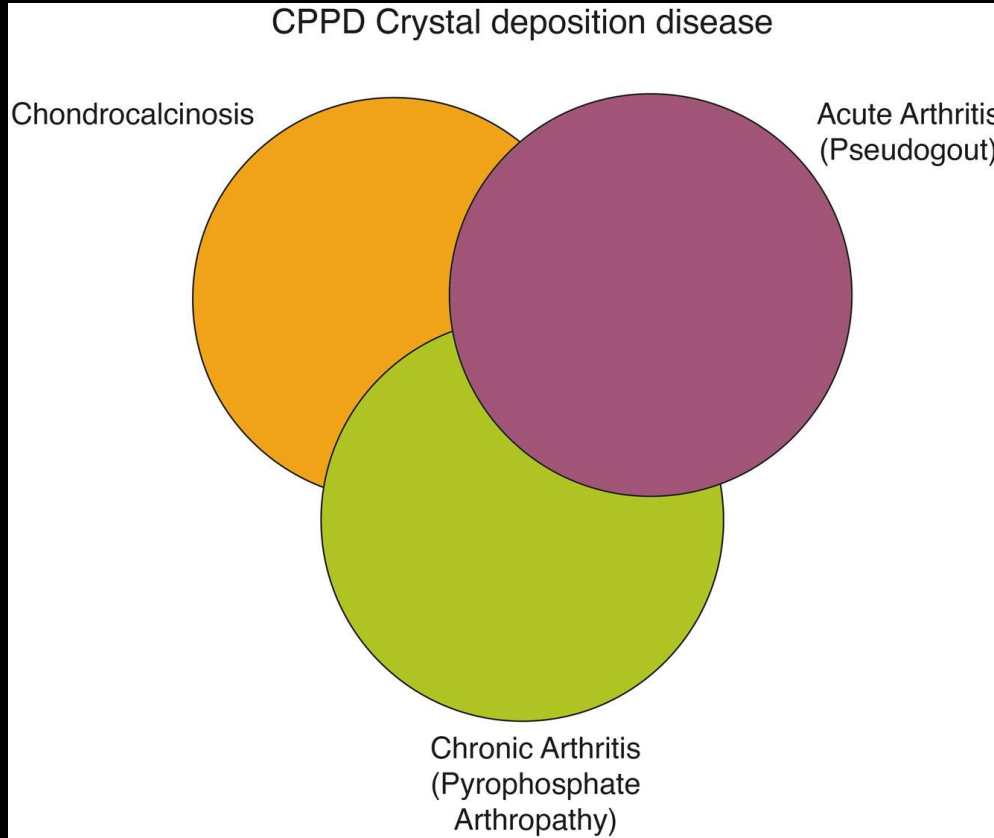
Calcium pyrophosphate deposition disease / pseudogout



Retroodontoid tumor (crowned dens), chondrocalcinosis of TFCC, multiple enthesophytes, disc calcifications in radiograph (not evident in MRI)

Crown & weakly positively birefringent & have a rhomboid or rod shape





*All 3 CPPD stages may be present in one patient
Diagnosis difficult when 2 or only 1 stage is seen*

*Acute CPPD attack hypothesis (A)
Pyrophosphate arthropathy pathogenesis (B)*

Including calcifications on radiographic reports is essential, as they may become symptomatic

Thank you

