

MICOD – 26/06/2024

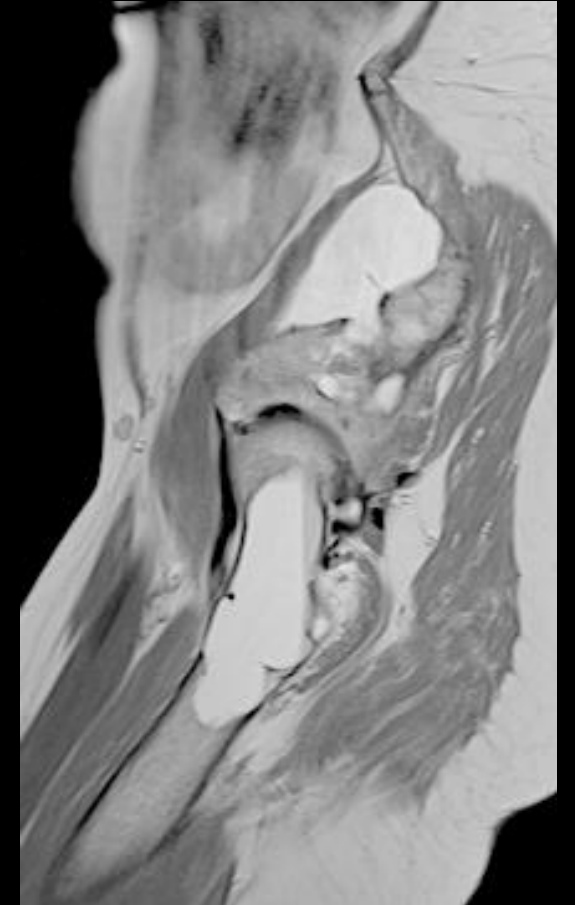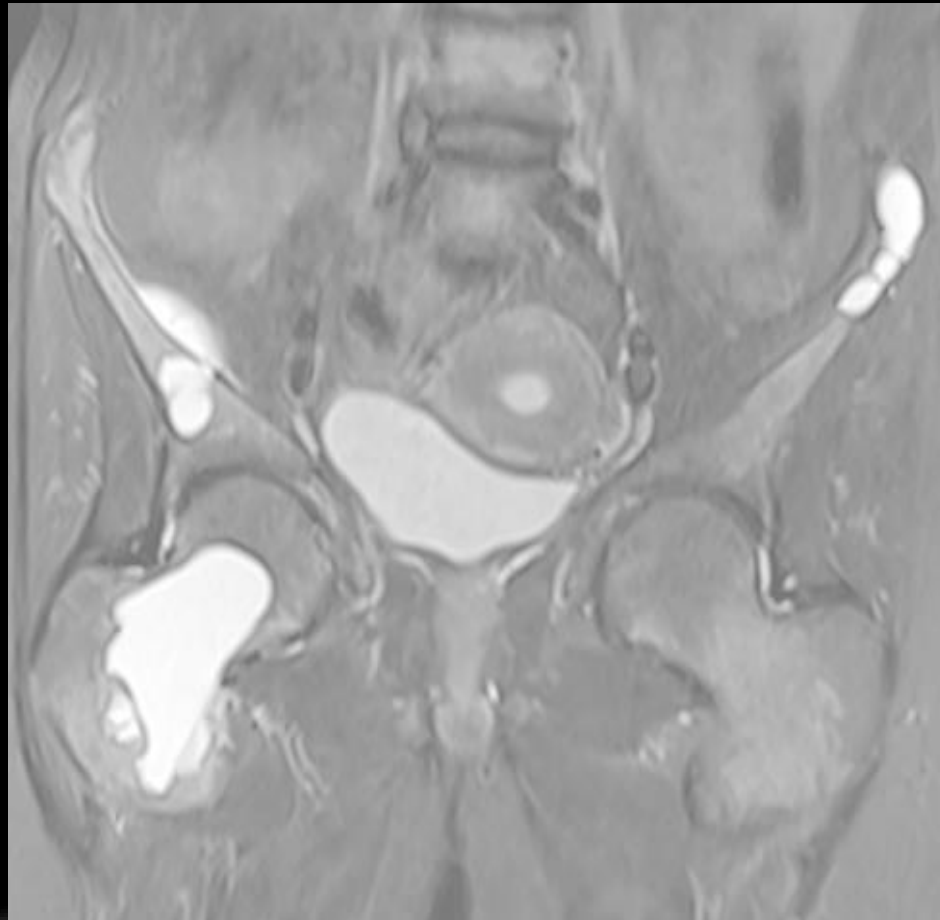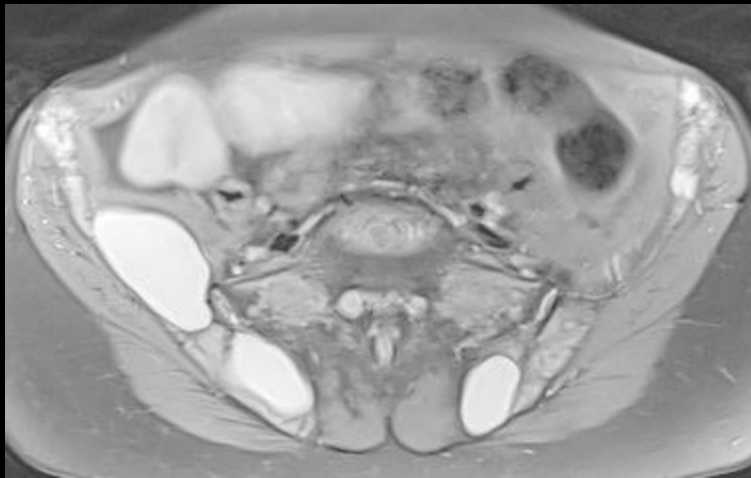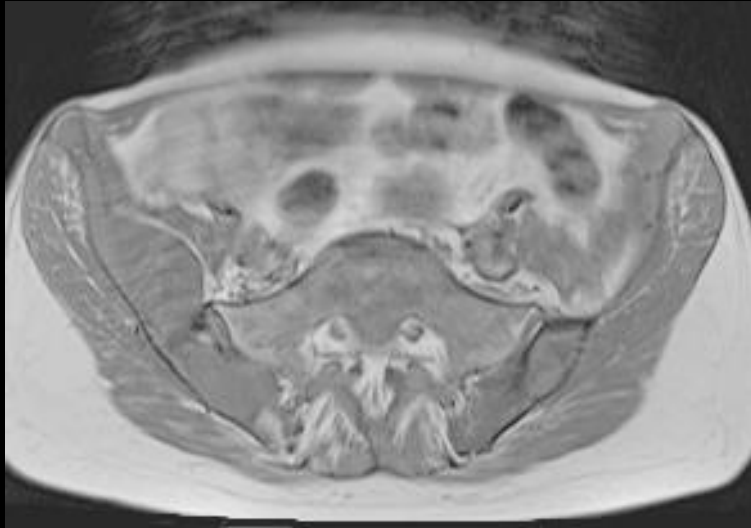Case contributor – Dr. Vaishali Upadhyaya

MI-COD

MSS INDIA- Case Of the Day



Brown tumors

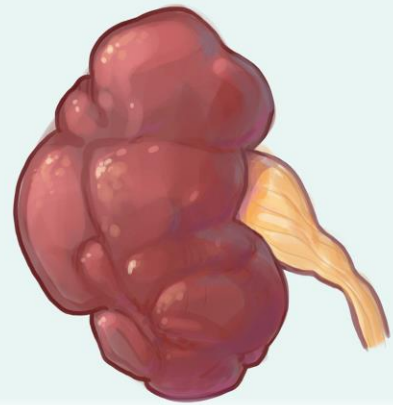


Patient has secondary hyperparathyroidism due to end stage renal disease

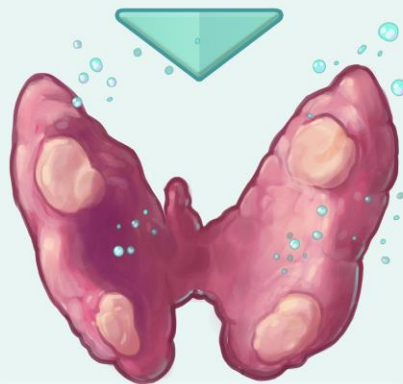Multiple cystic lesions in pelvic bones & right femur with fluid-fluid level in right femoral lesion

Osteitis fibrosa cystica (Brown tumors)

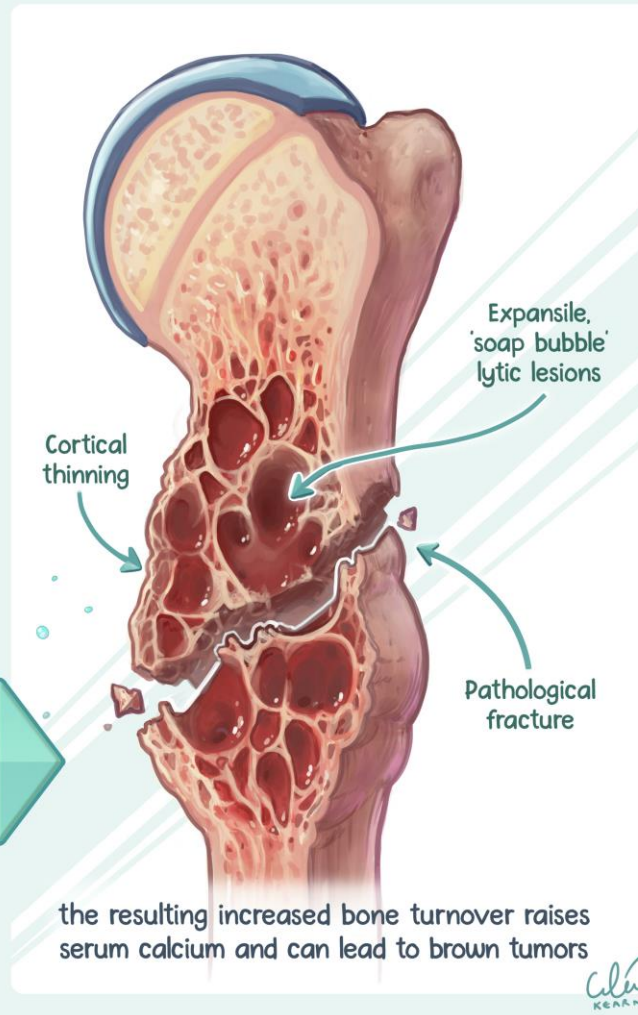
Vilanilam GK, Nikpanah M, Vo CD, Kearns C. Osteitis Fibrosa Cystica: Brown Tumors of Hyperparathyroidism and End-Stage Renal Disease. Radiographics. 2023 May



Renal failure reduces calcitriol production & phosphate excretion



increasing parathyroid hormone production...



- Rare manifestation of secondary hyperparathyroidism due to end-stage renal disease (ESRD), may simulate malignancy
- Patients may present with renal stones, generalized weakness, bone pain, and recurrent fractures
- Imaging findings are expansile multiloculated osteolytic lesions, which predominantly involve the pelvis, clavicle, mandible, and ribs
- Histologic analysis shows a gross brown mass consisting of microfractures, hemorrhage, macrophages with hemosiderin, bone resorption, and peritrabecular fibrosis
- Management with phosphate binders to treat hyperphosphatemia, calcimimetics or active vitamin D, and parathyroidectomy have been shown to be beneficial

Thank you

