

MICOD – 13/06/2024
Case contributor – Dr. Ankur Shah

MI-COD

MSS INDIA- Case Of the Day



-
- MRI OF A RYAN (DOG)-----
DIAGNOSIS ????

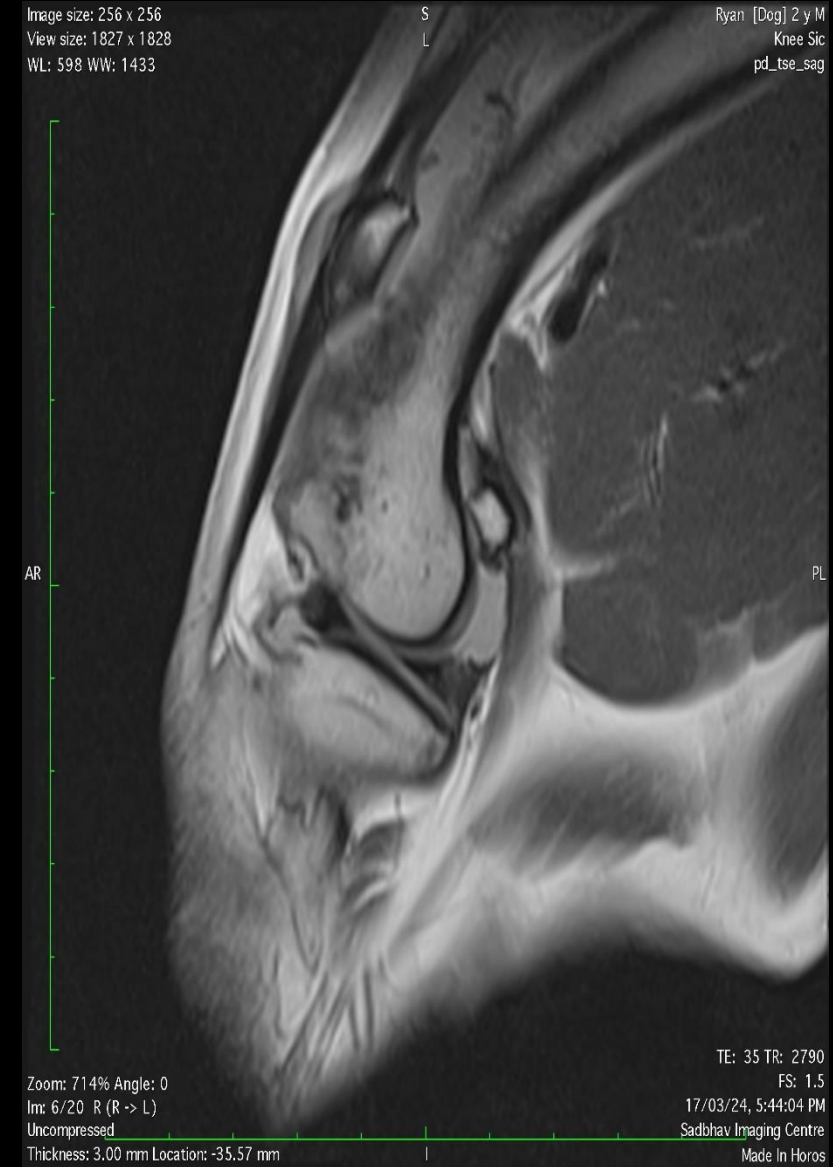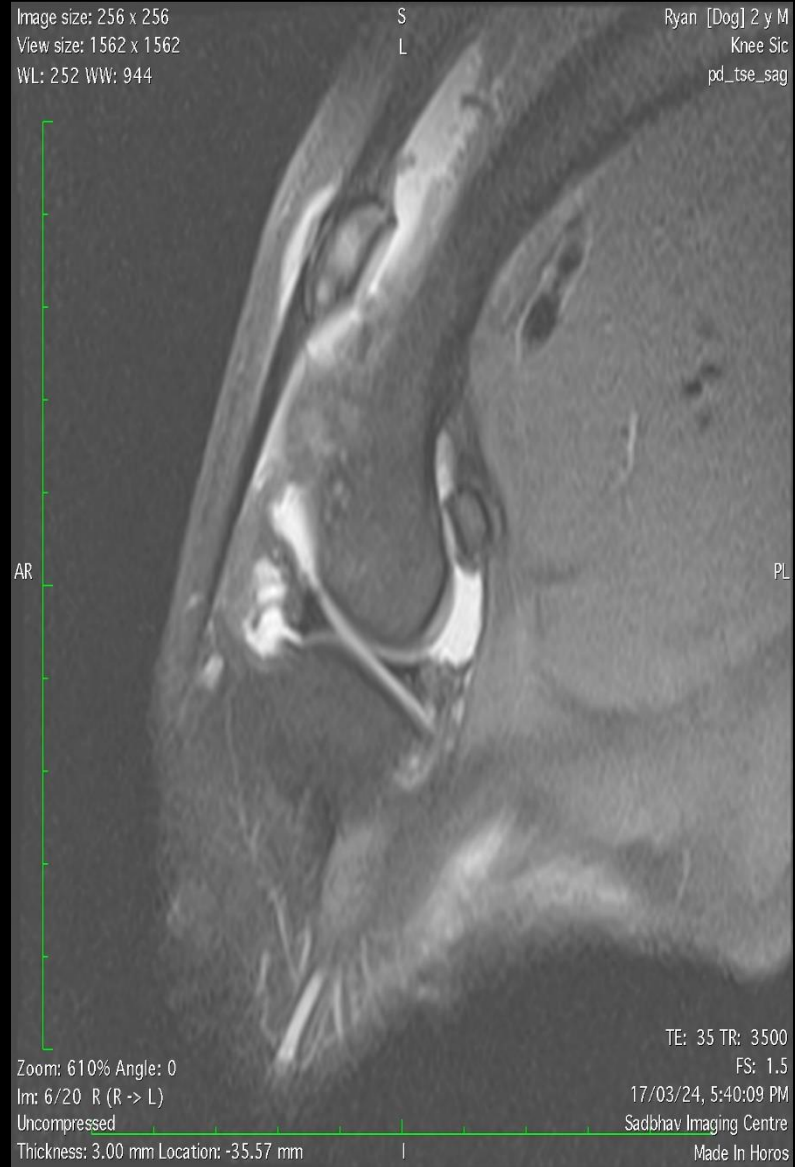
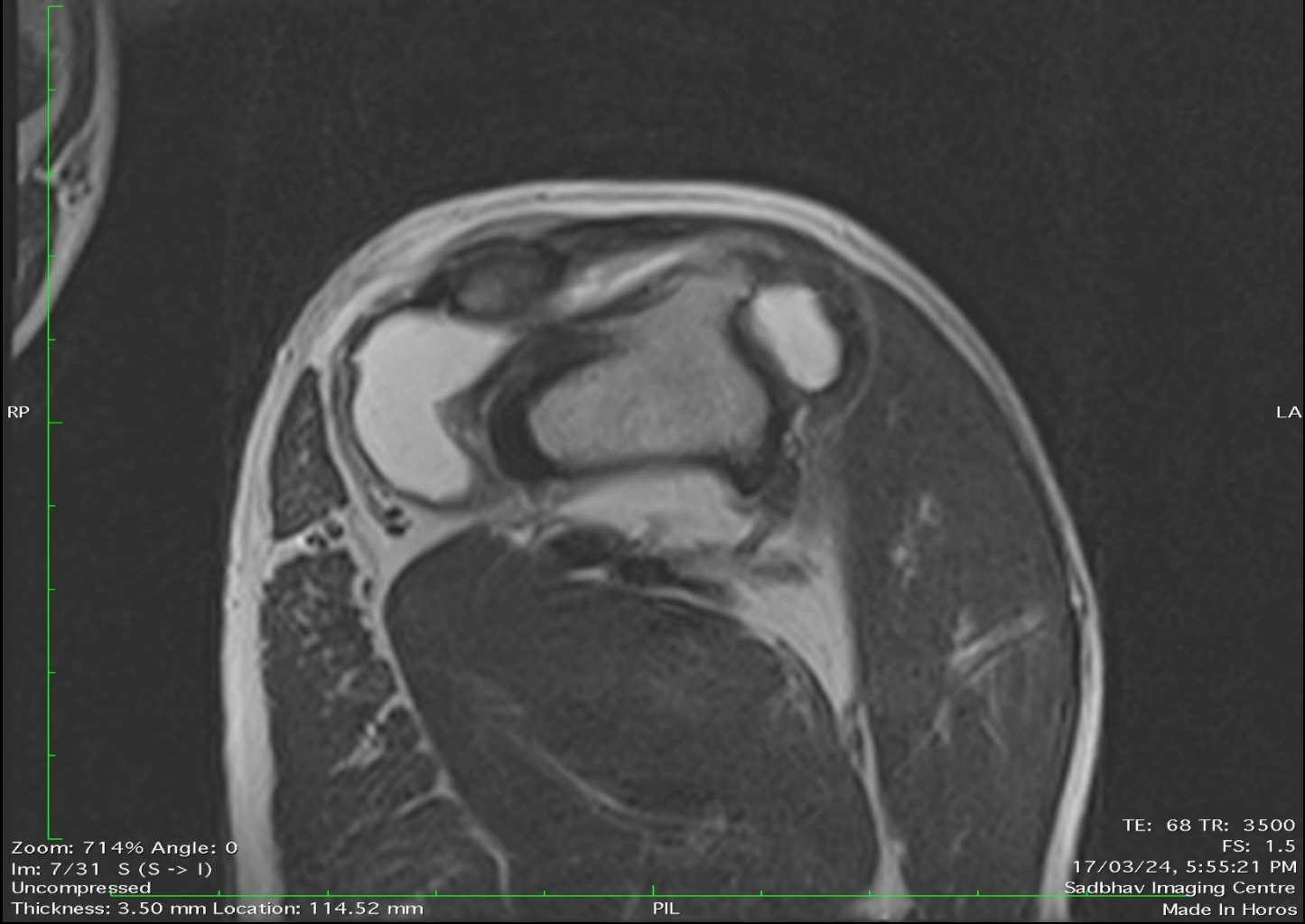


Image size: 256 x 256
View size: 1827 x 1828
WL: 599 WW: 1636

ASR
L

Ryan [Dog] 2 y M
Knee Sic
t2_tse_tra_320



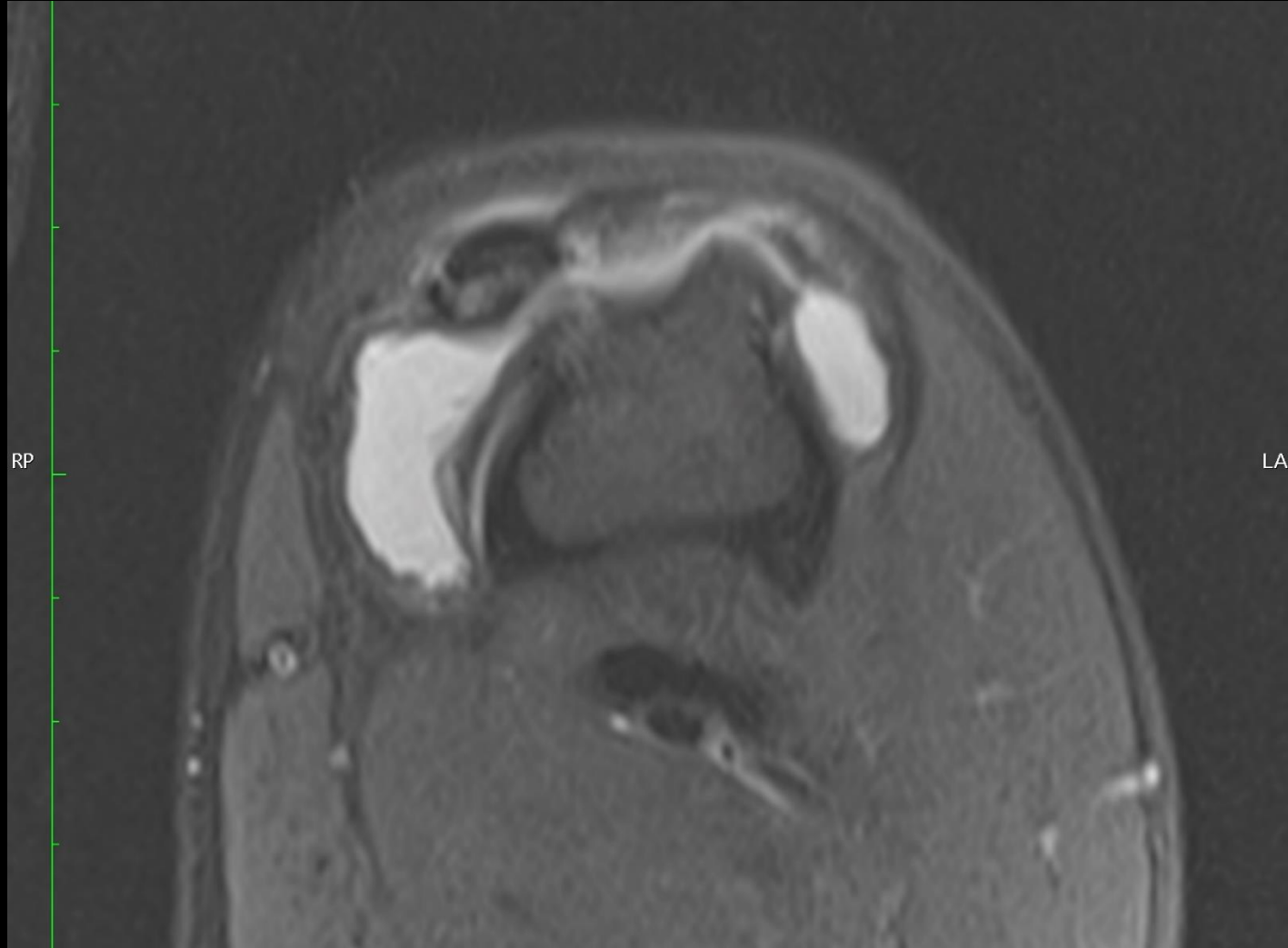
RP

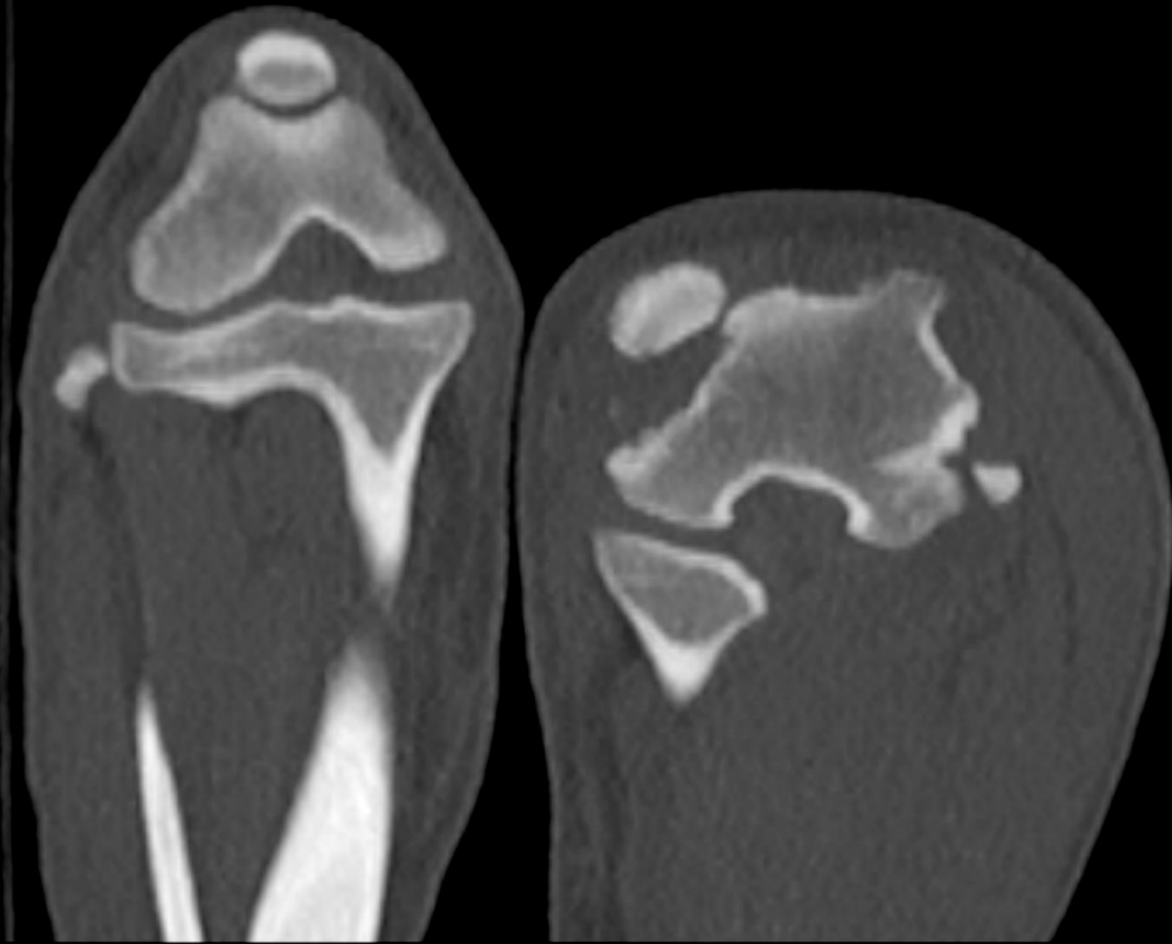
LA

Zoom: 714% Angle: 0
Im: 7/31 S (S -> I)
Uncompressed
Thickness: 3.50 mm Location: 114.52 mm

PIL

TE: 68 TR: 3500
FS: 1.5
17/03/24, 5:55:21 PM
Sadbhav Imaging Centre
Made In Horos





A close-up photograph of a golden retriever lying down on a light-colored surface. The dog's eyes are closed, and it appears to be resting or sleeping. A blue, inflatable E-collar (E-collar) is positioned around its neck, extending upwards. The background is a plain, light-colored wall.

DIAGNOSIS

MEDIAL DISLOCATION OF PATELLA IN RYAN (DOG)

GRADES

- Grade 1: A knee cap that can be luxating with manual pressure but is otherwise is within the groove.
- Grade 2: The knee cap spontaneously luxates, is typically associated with a skipping lameness when the knee cap moves.
- Grade 3: The knee cap is permanently luxated but can be manually replaced in the groove.



THANKYOU

