


MICOD – 25/04/2024

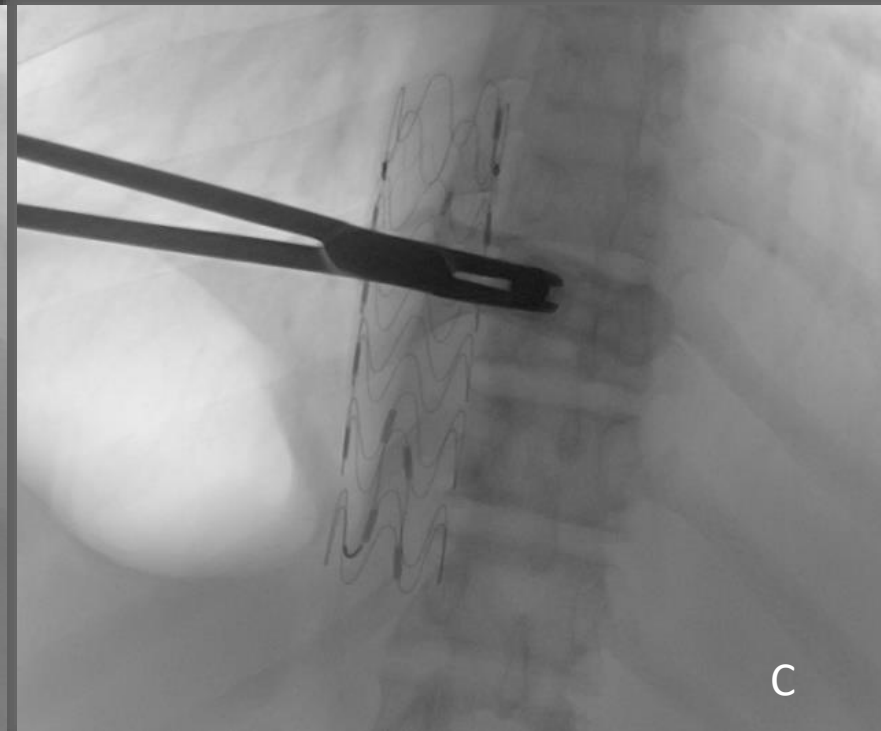
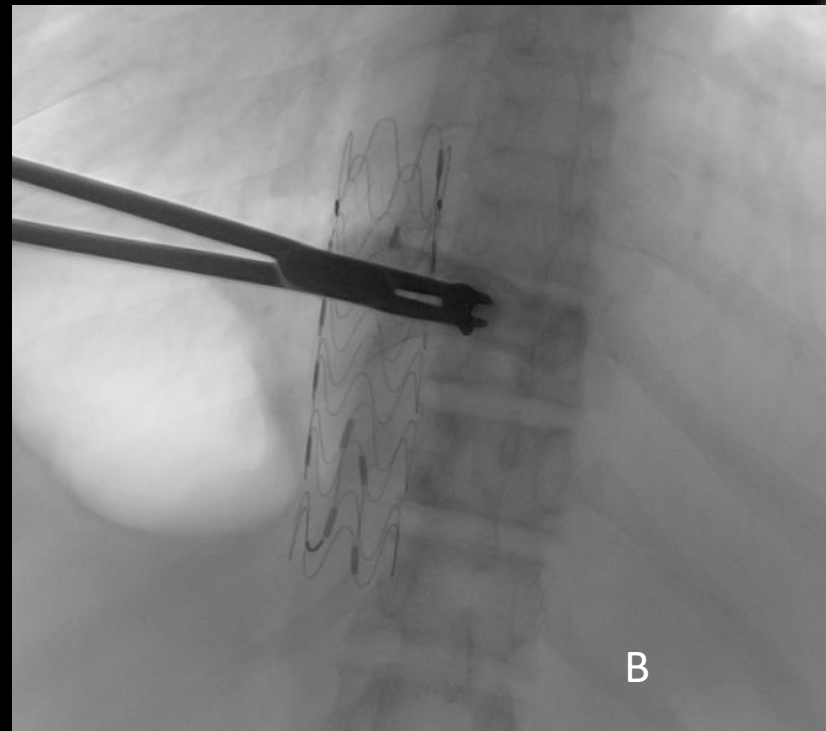
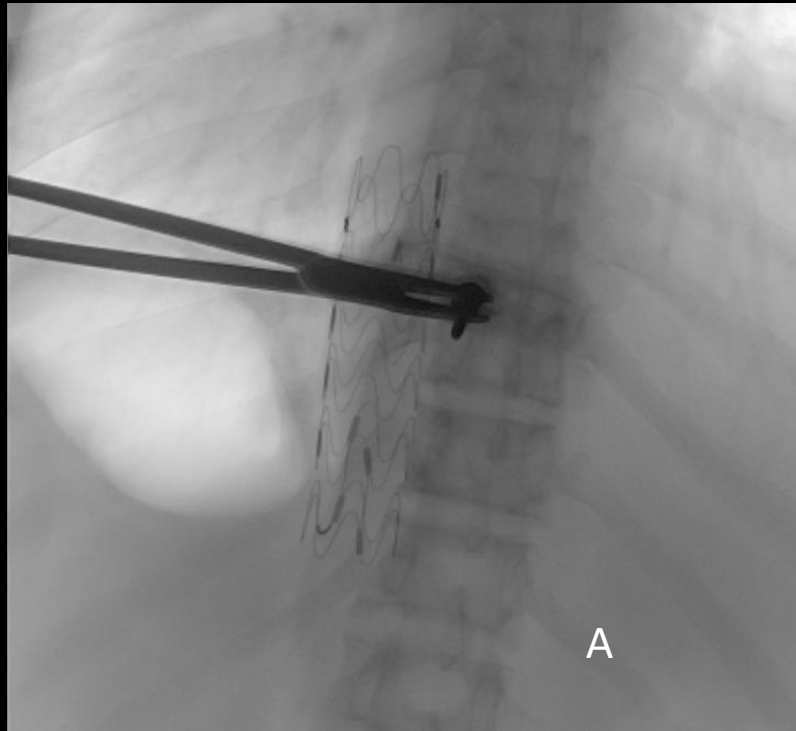
Case contributor – Dr. Dharmendra Singh

MI-COD

MSS INDIA- Case Of the Day



Which one is correct approach of doing transpedicular lower thoracic vertebrae intervention?



Answer: C, End-on approach barrel view