

MICOD – 24/04/2024

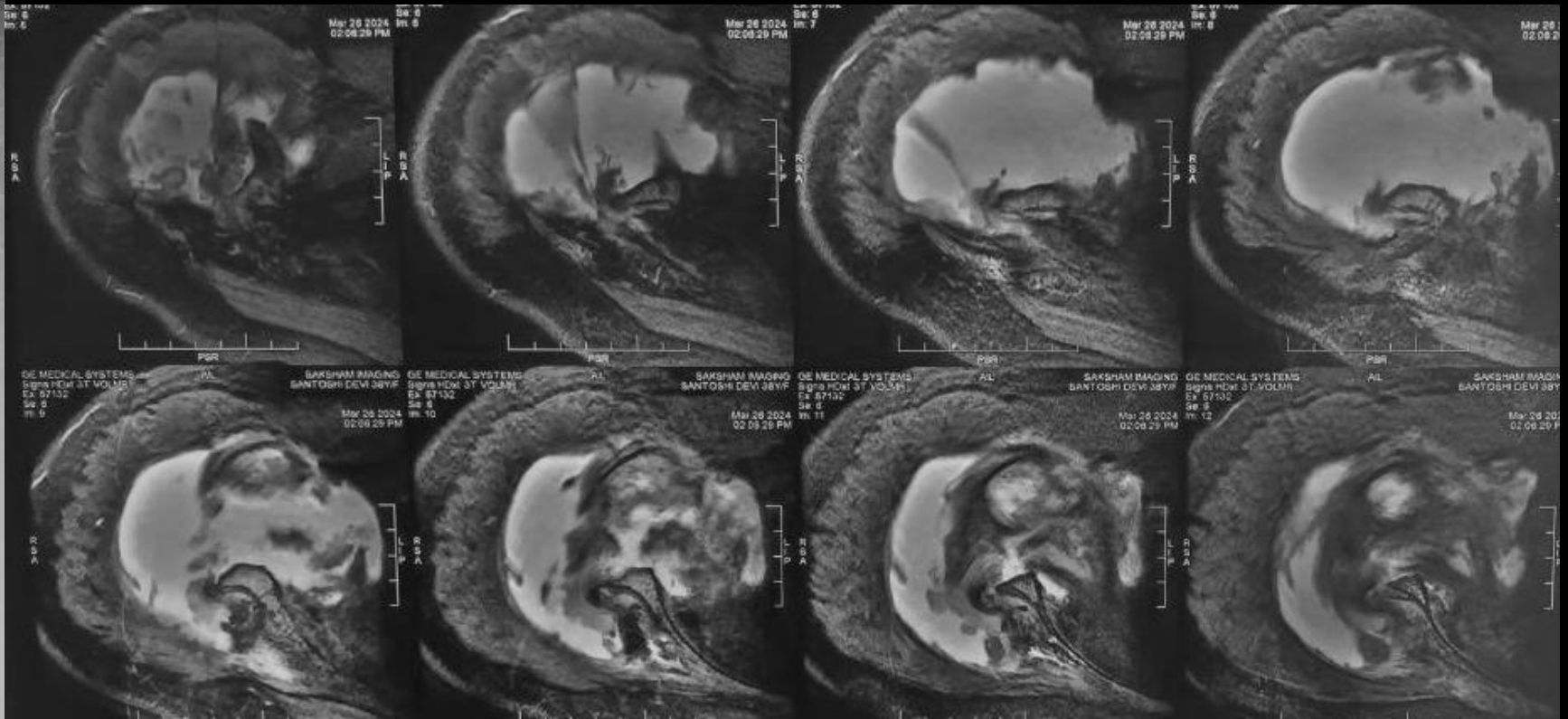
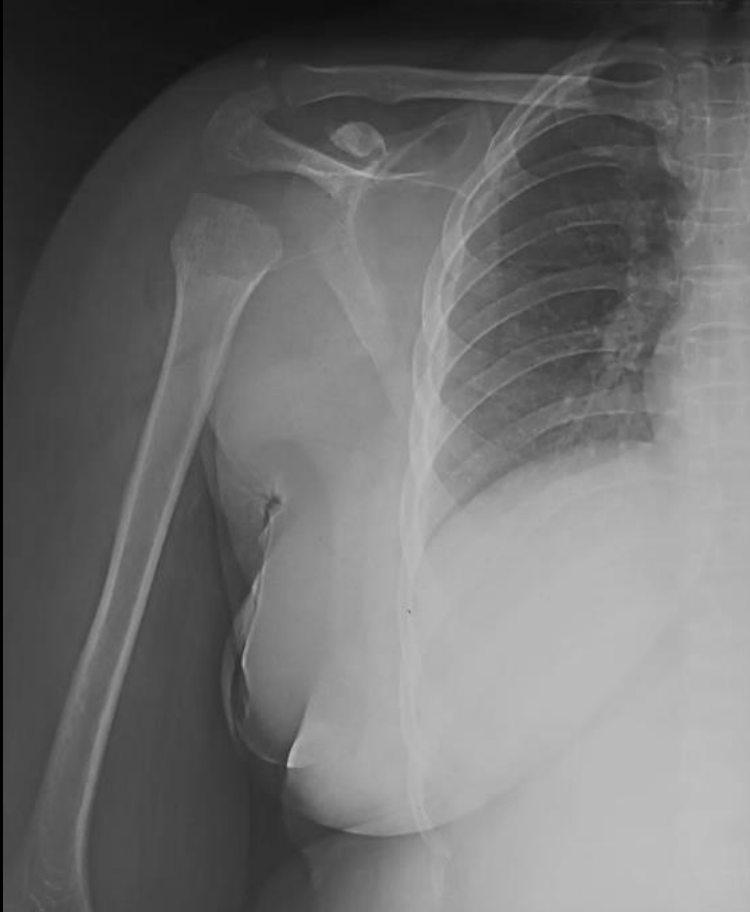Case contributor – Dr. Dharmendra Singh

MI-COD

MSS INDIA- Case Of the Day



37-year-old lady with insidious pain in shoulder since 2 years. Took ATT in rural hospital “ as per the dictum “ TB in india can present like anything”



Rapidly destructive arthrosis of shoulder

- RDA in shoulder is a *rare* event, characterized by rapid collapse of the humeral head with no evidence of other nonseptic articular arthropathy & presents a diagnostic challenge.
- Postel and Kerboull defined *rapid destruction as >2 mm in 1 year or 50% joint space narrowing in 1 year.*
- A unique pattern of *humeral head flattening, which appeared like a clean surgical cut with bone debris around the humeral head.*
- MRI findings revealed significant joint effusion and bone marrow edema in the humeral head, *without involvement of the glenoid.*
- Pathologic findings showed both fragmentation and regeneration of bone matrix, representing fracture healing

A wide-angle landscape photograph showing a massive waterfall cascading down a dark, rocky cliff face. The waterfall is the central focus, with water splashing at the base. The surrounding area is covered in dense, lush green forest. In the background, rolling hills and a valley are visible under a bright sky. A semi-transparent dark banner is overlaid across the middle of the image, containing the text "Thank you".

Thank you