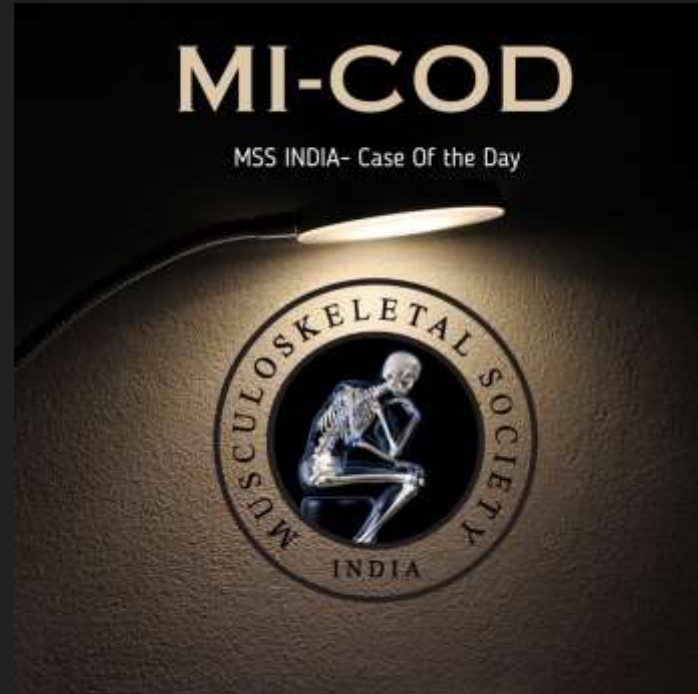
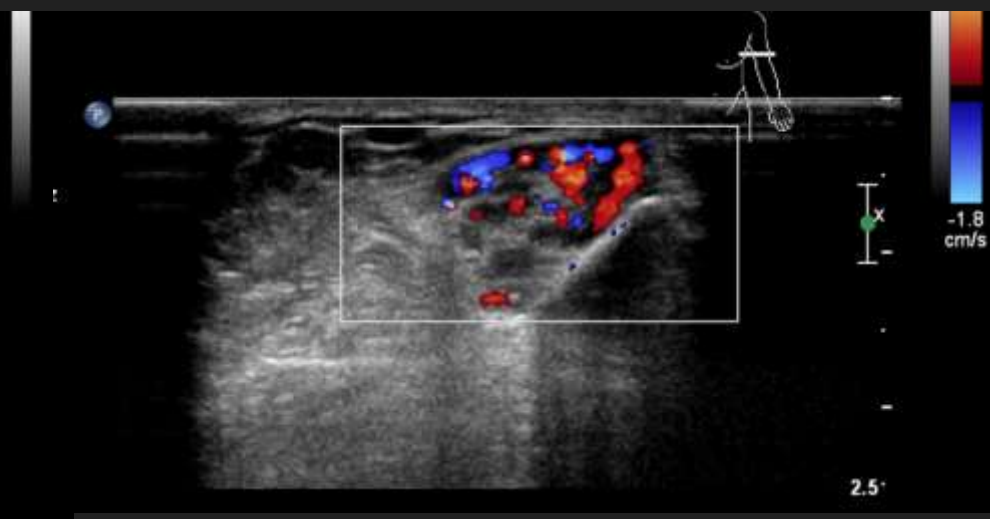
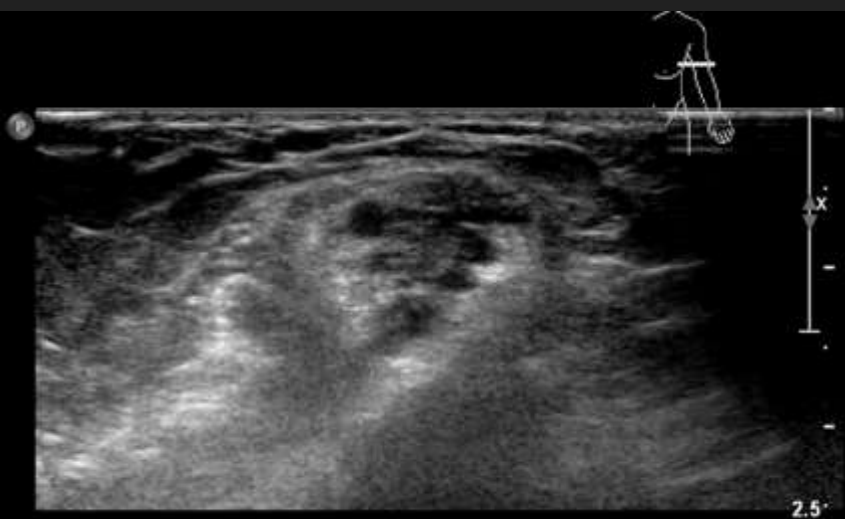


MICOD -10/04/24

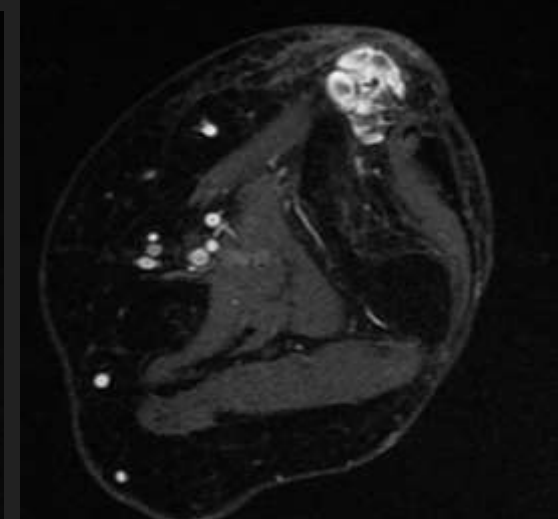
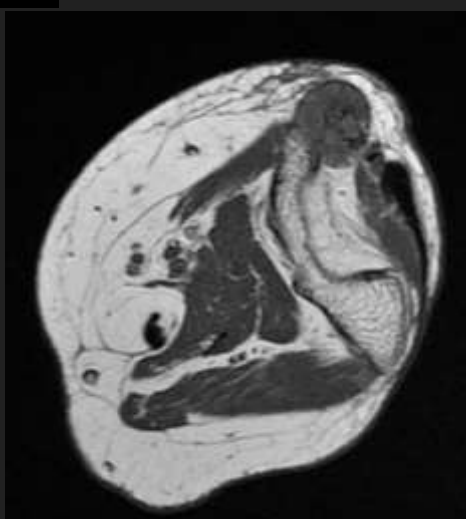
Case contributor – Dr. Satish

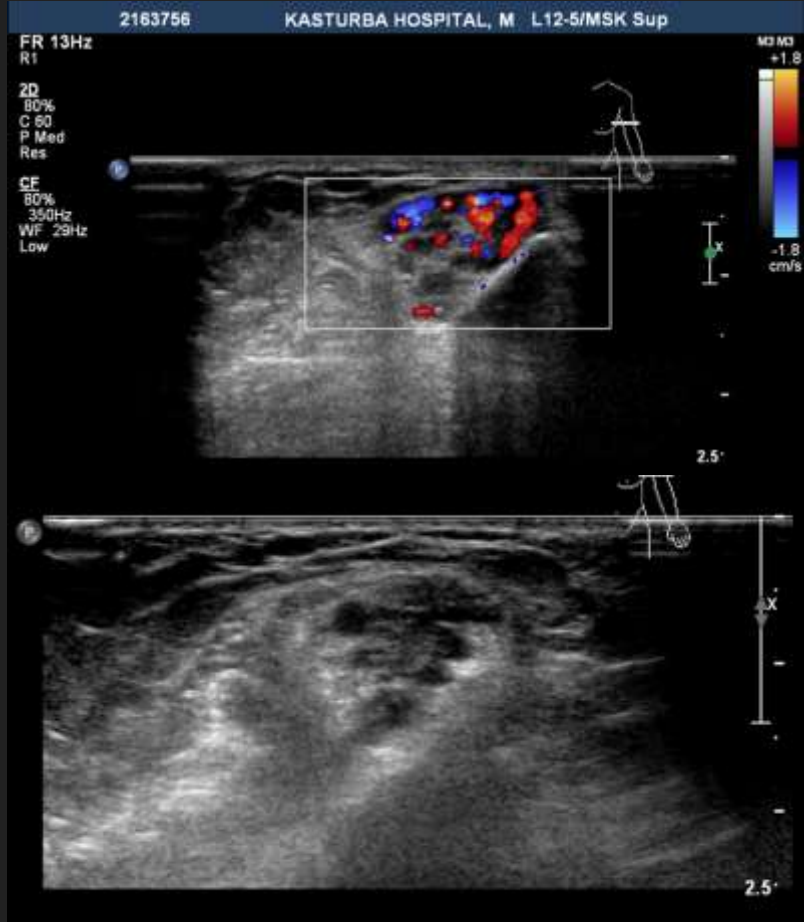


*40 yrs female*, Acute onset left elbow pain, palpable lesion along medial aspect of elbow. Patient is On treatment for borderline leprosy. Now, worsening of ulnar nerve palsy

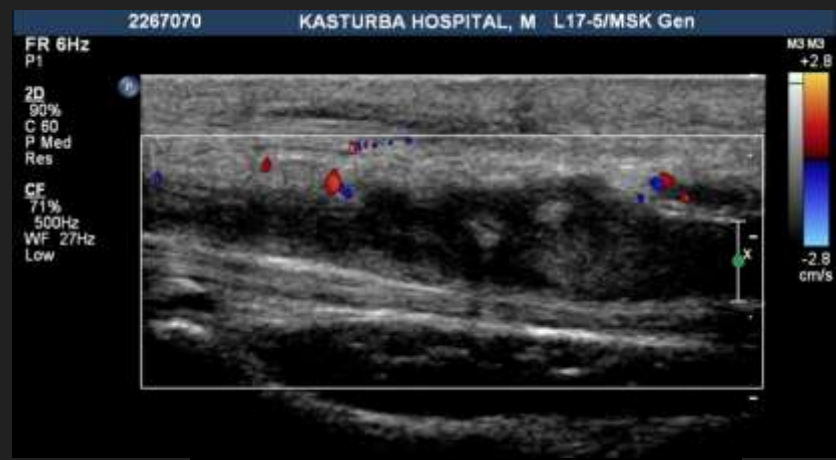

Answer - Reversal  
reaction

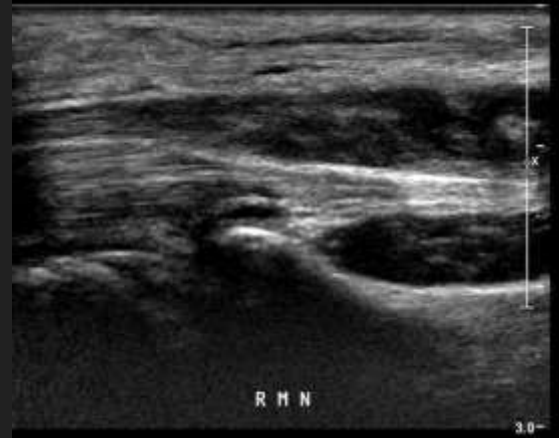



Reversal reaction - Bulky nerve with thickened fascicle and diffuse increase in vascularity of nerve



Close differential - Neuritis with abscess



# Why it is important to differentiate?

Reversal reaction

Treatment with steroids

Nerve abscess

Surgical decompression

