

MICOD – 28/03/2024

Case contributor – Dr. Harun Gupta (MSK teaching Room)

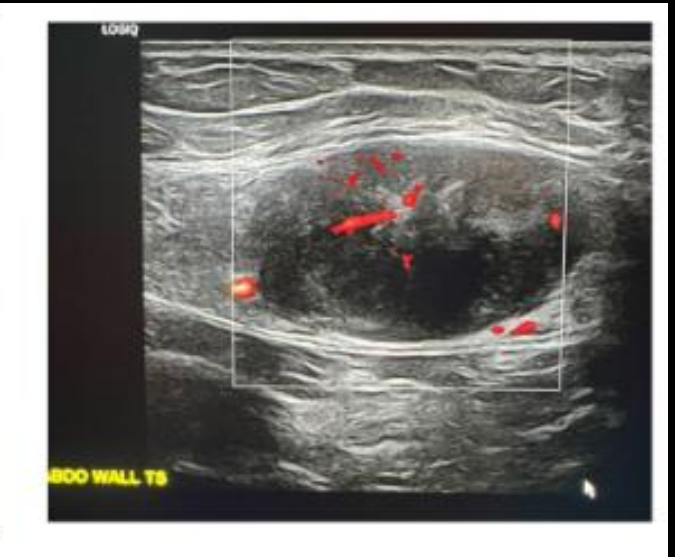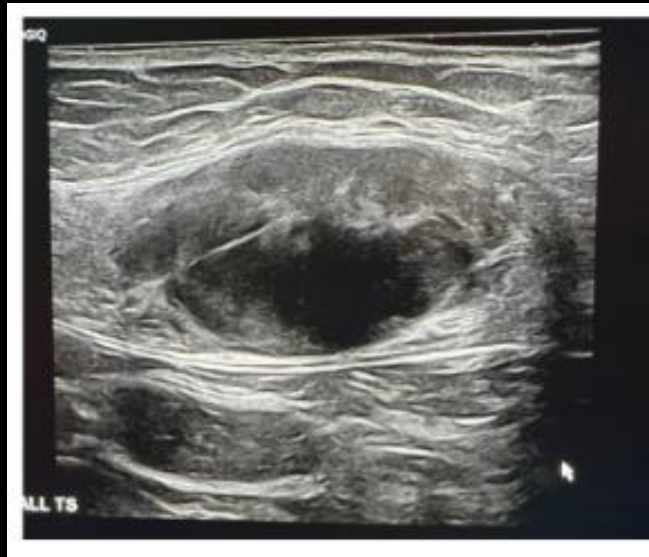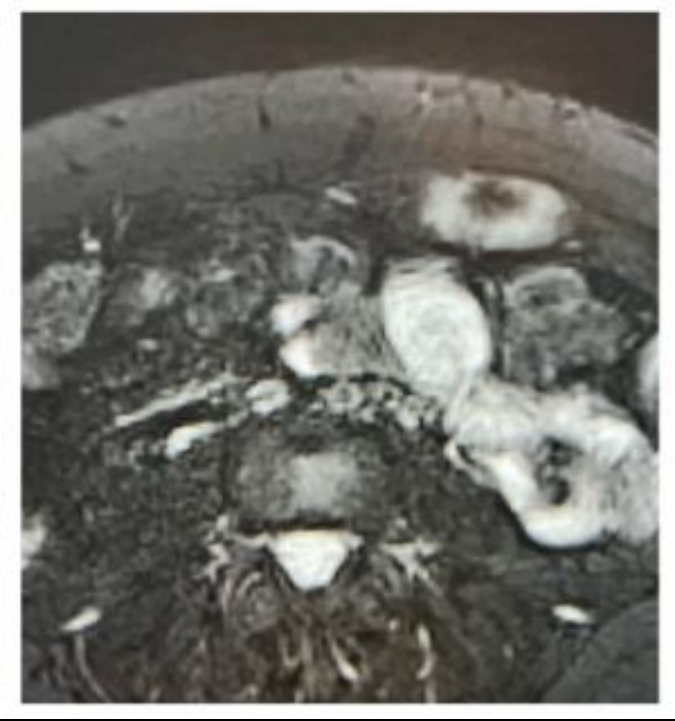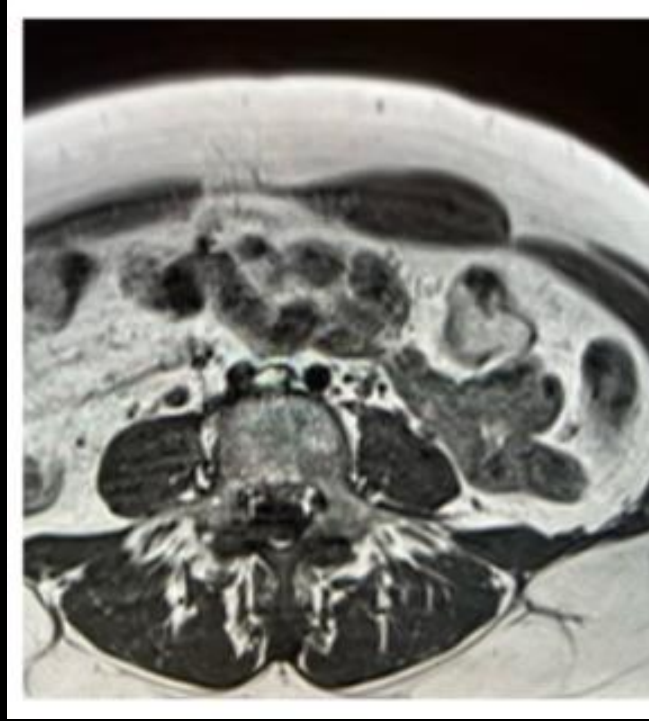
MI-COD

MSS INDIA- Case Of the Day



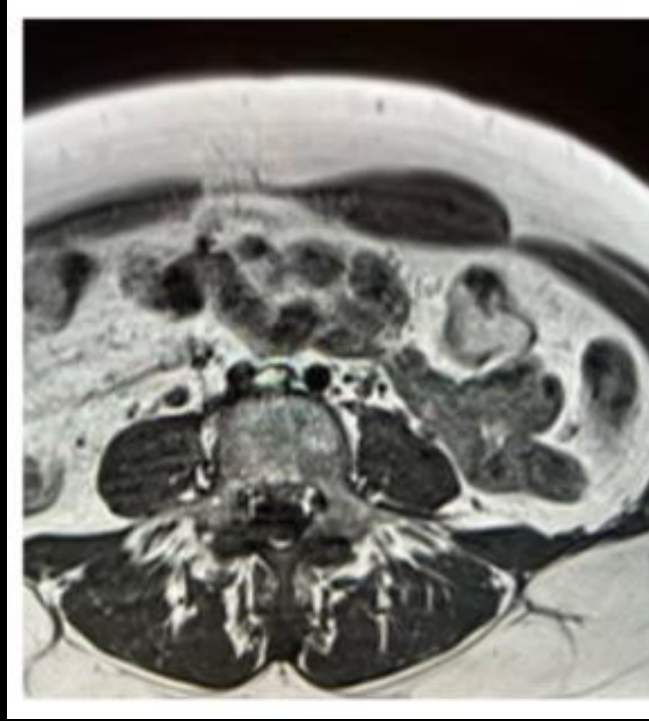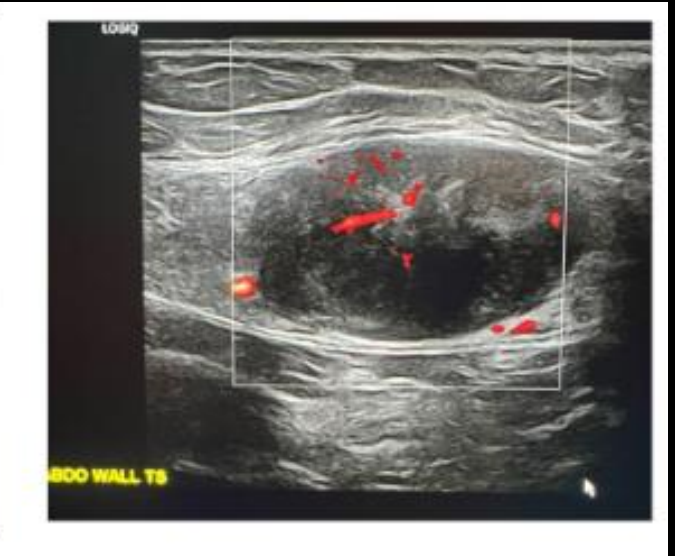
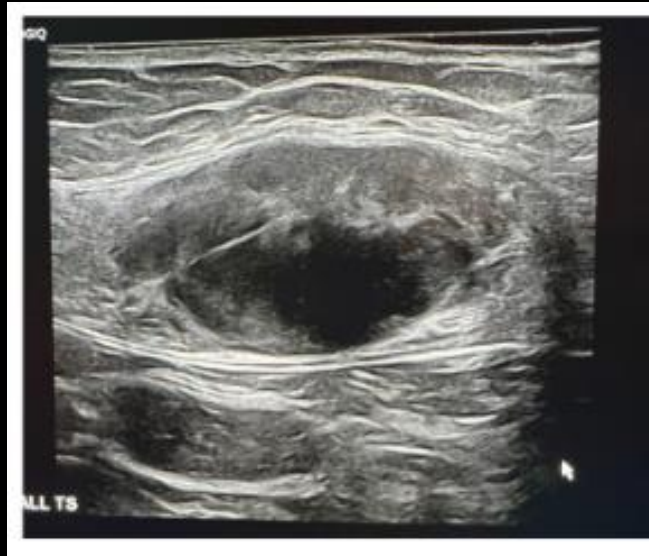35-year-old lady presents with feeling of mass in left abdominal wall

What is the lesion ?
Any differentials ?



This case is Desmoid
Young Female
Lesion entirely in Rectus
compartment
mostly low signal on MRI and
hypoechoic on US

D/d - endometriosis
often not entirely in rectus
compartment
Most cases need biopsy for
confirmation



Separate cases with examples of d/d

