

MICOD – 27/03/2024

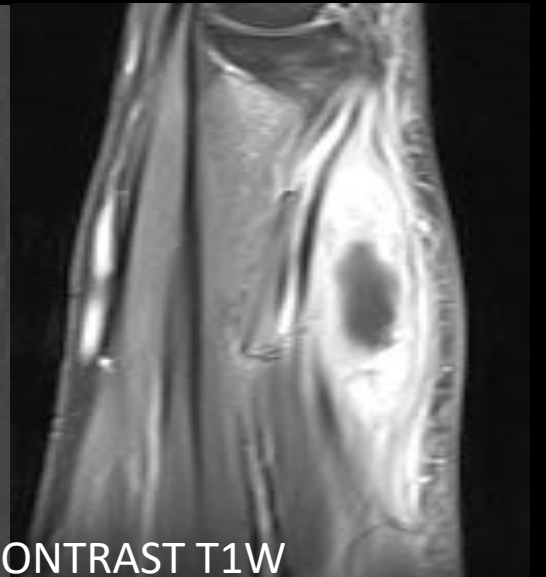
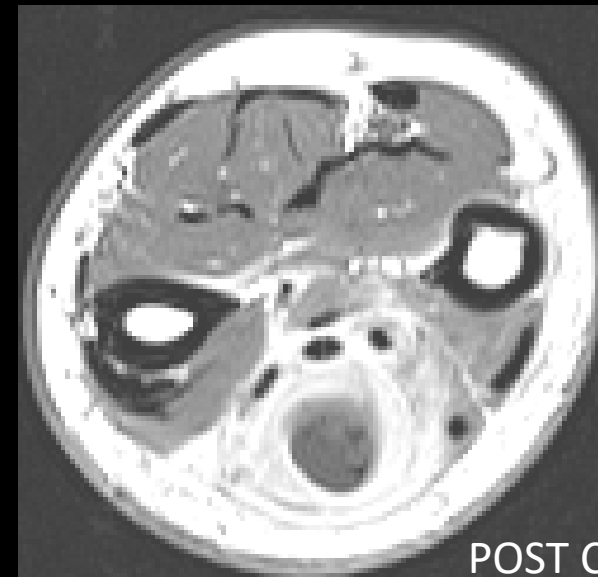
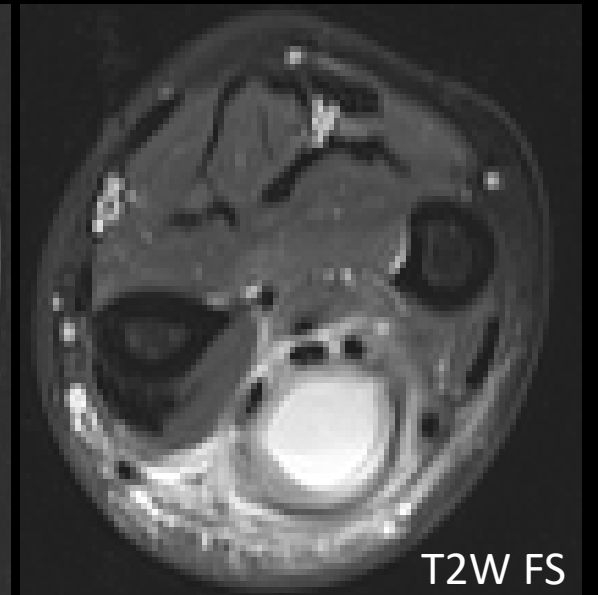
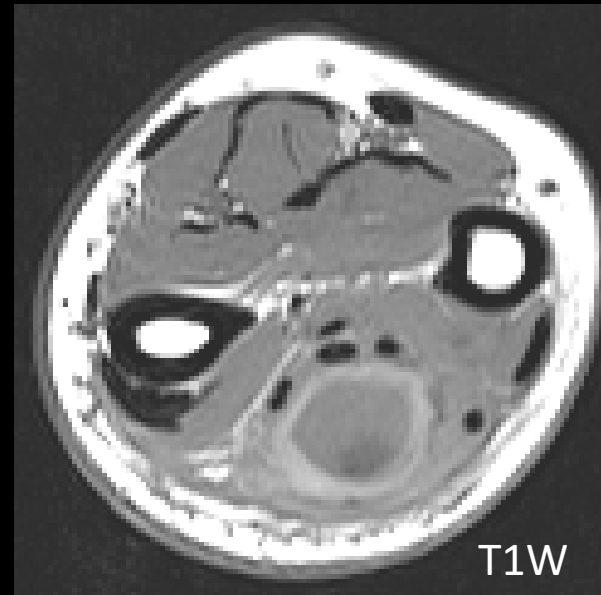
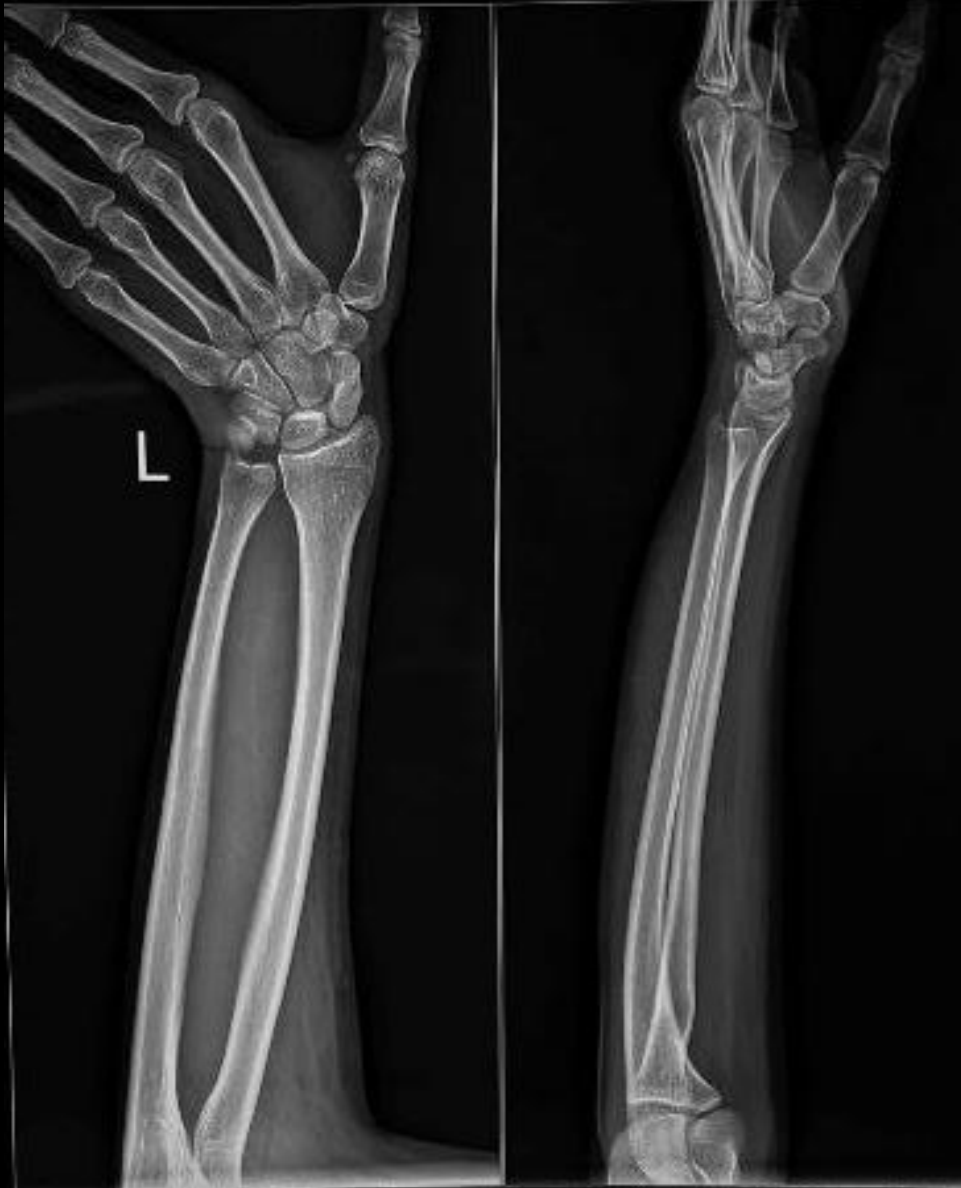Case contributor – Dr. Vaishali Upadhyaya

MI-COD

MSS INDIA- Case Of the Day

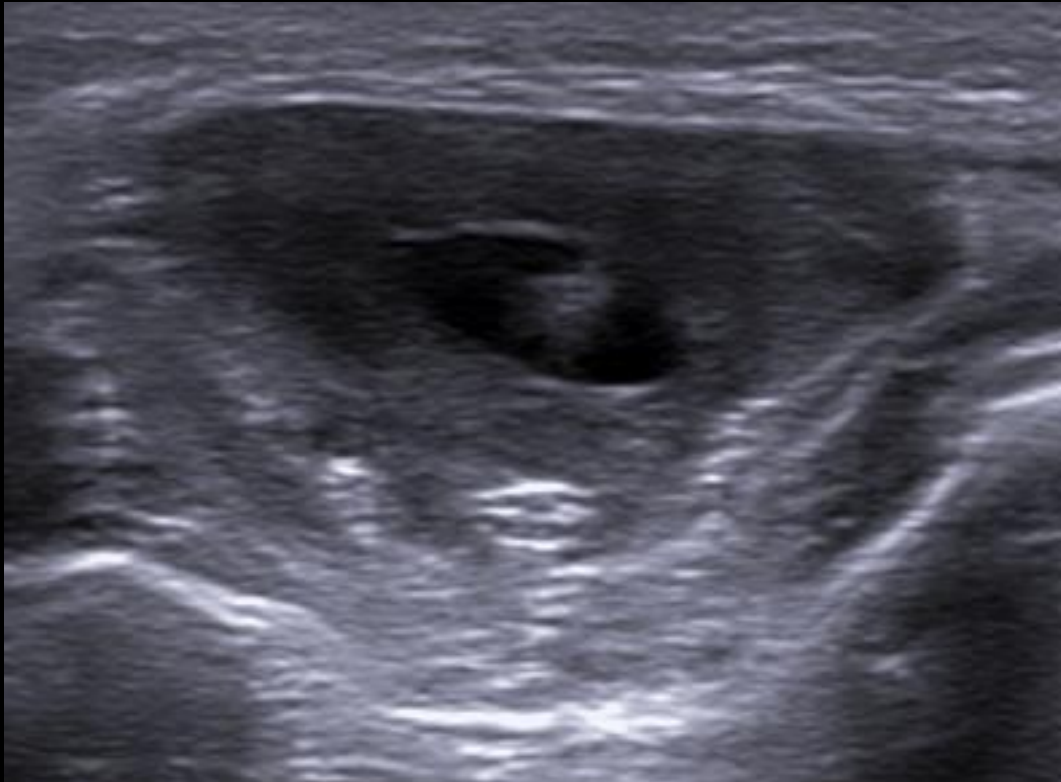


21-year-old lady with swelling on the dorsal aspect of left forearm, sometimes painful, no H/O fever or trauma



Myocysticercosis

USG of the lesion !!



Cysticercosis: parasitic infection (*Taenia solium*)
Cysts- brain, eyes, subcutaneous tissue, muscles
Larval death- acute inflammation
Cyst degeneration- chronic inflammation: mass-like, pseudotumor or abscess-like lesion
Cyst retraction, scolex calcification

USG : cyst with inflammatory mass around it/ Irregular cyst with minimal fluid on one side/ large fluid collection within the muscle with the cyst eccentrically within it/ calcified cyst

MRI: cyst is T1hypointense and T2 hyper intense, scolex T1 intermediate signal and intermediate to hypointense on T2
Perilesional edema and enhancement

(Case highlights the importance of USG in evaluation of such lesions!)