

MICOD -23/03

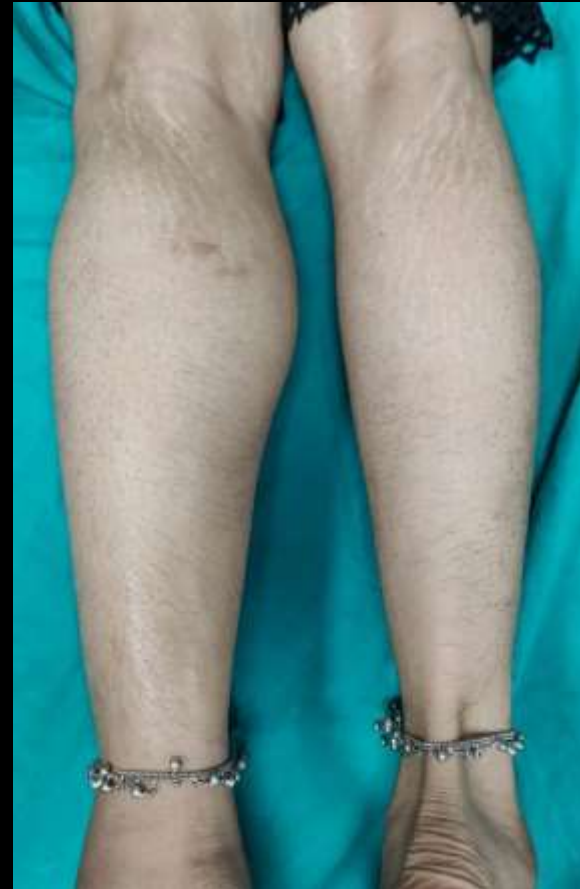Case contributor – Dr. Sonal Saran

MI-COD

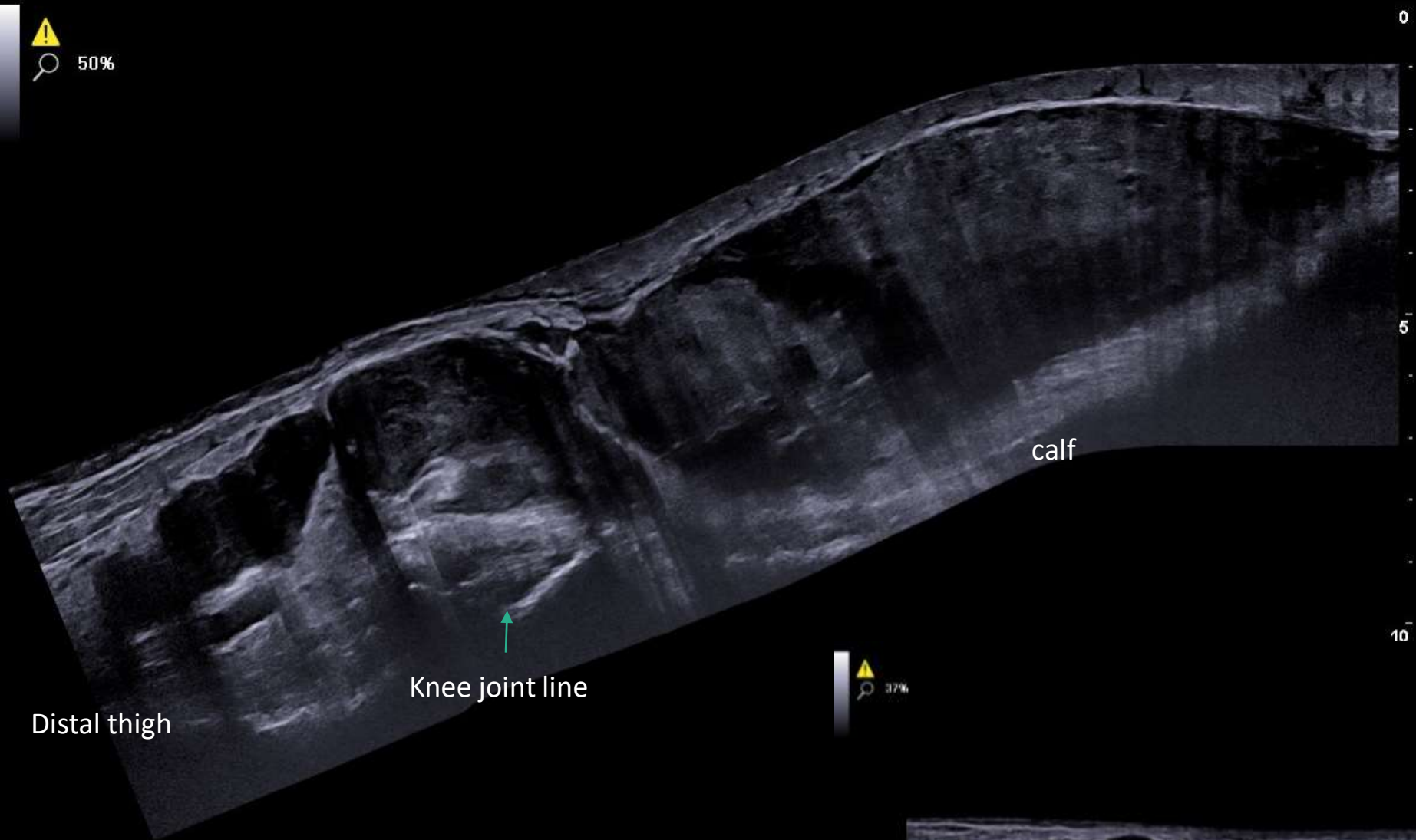
MSS INDIA- Case Of the Day



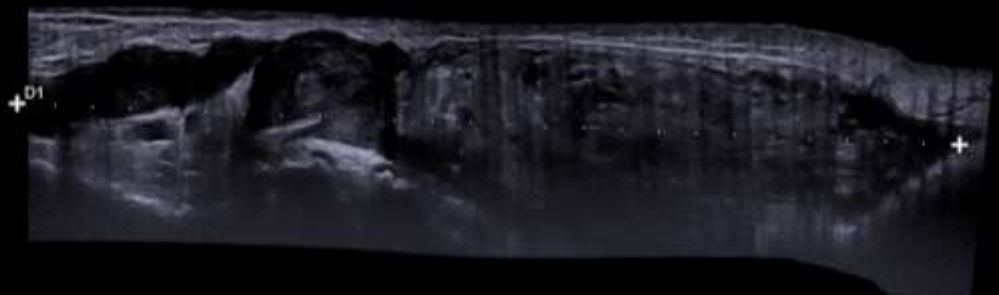
- A 30 year old female with known rheumatoid arthritis presented with left calf pain and mass.



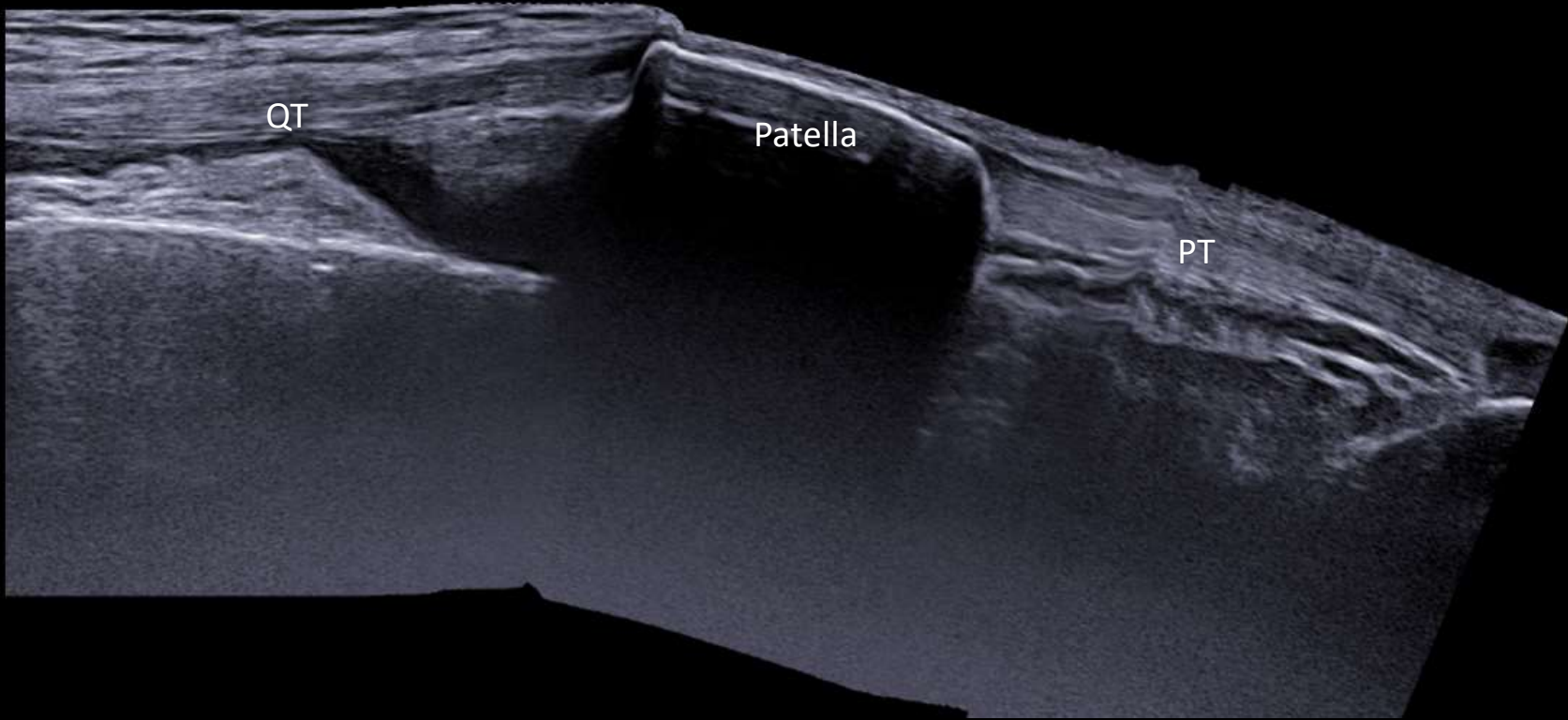50%



37%



D1 249.5 mm



Exuberant synovial thickening in baker cyst
forming giant pannus