

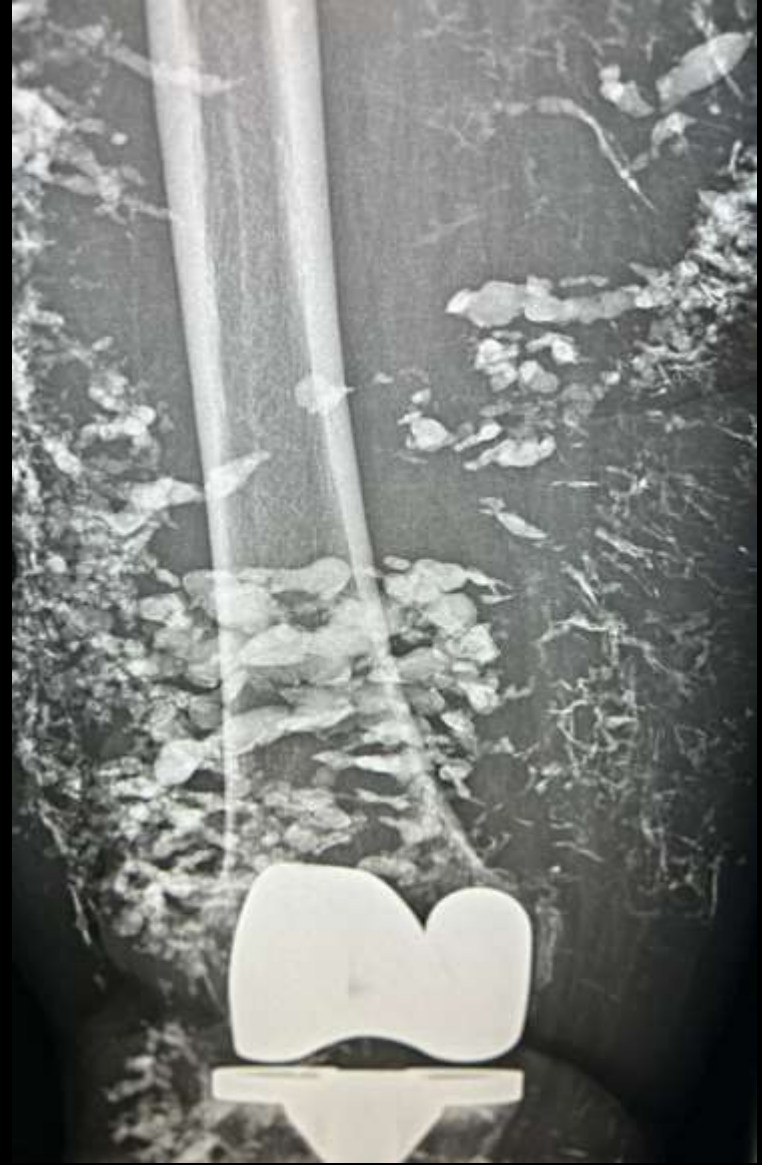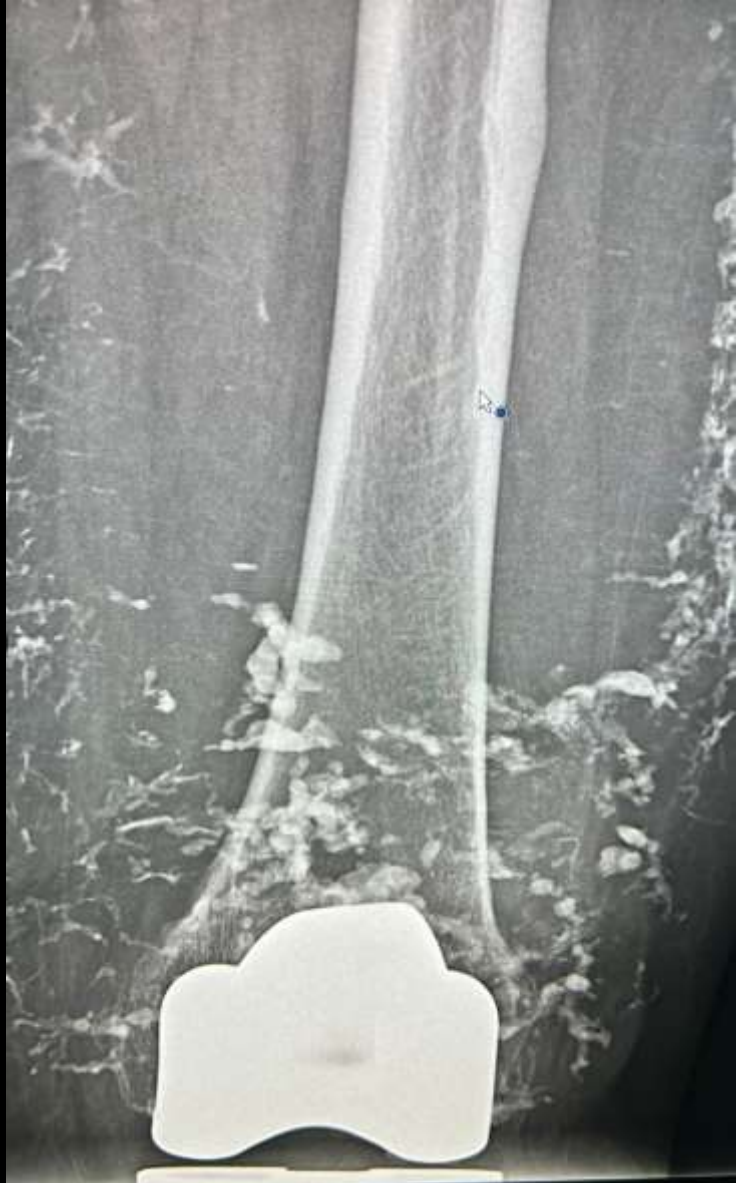
MICOD – 21/03/2024

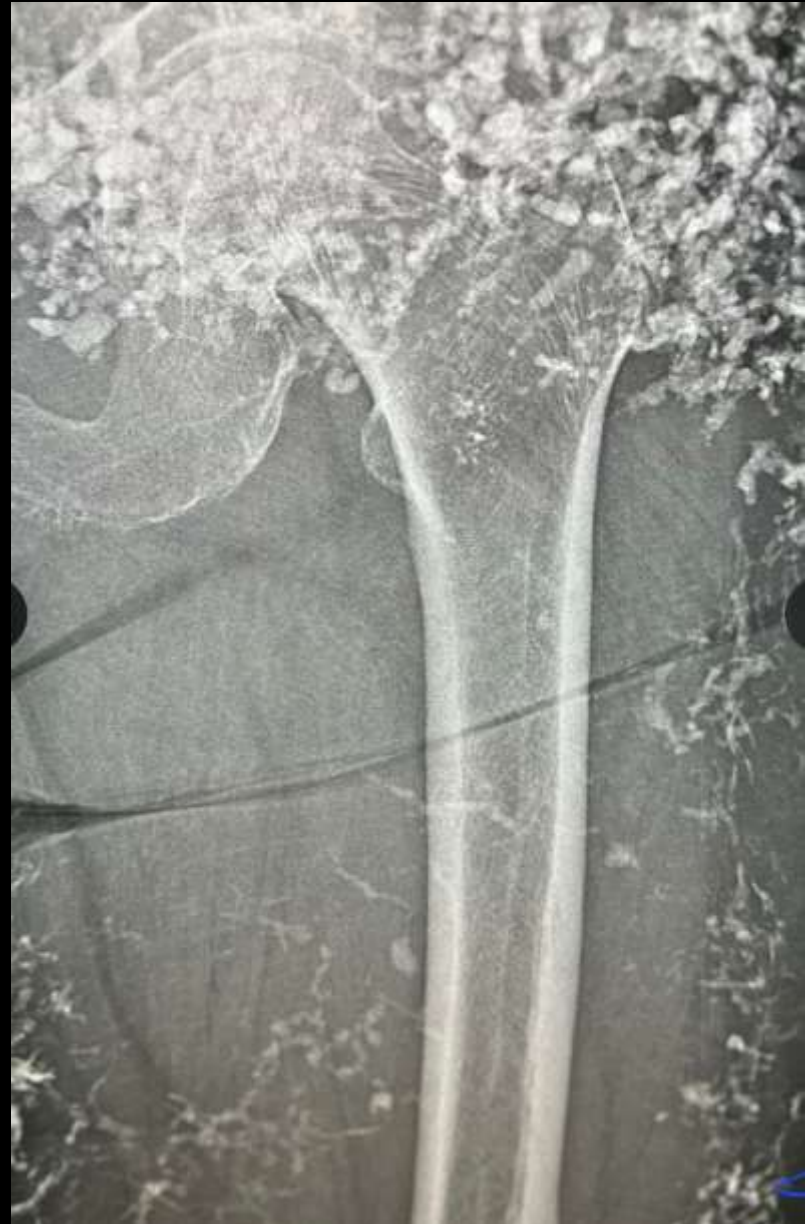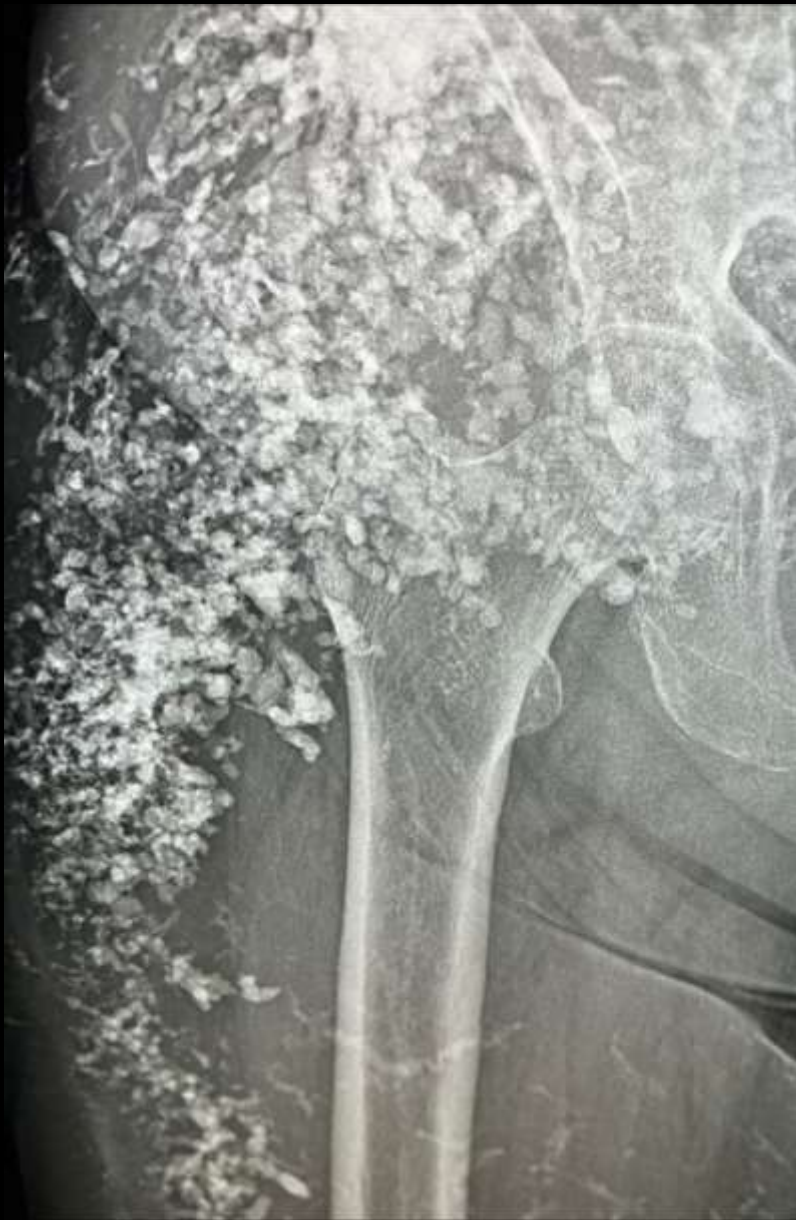Case contributor – Dr. Harun gupta (MSK Teaching Room)

# MI-COD

MSS INDIA- Case Of the Day







Middle aged female.

What are the findings and Diagnosis?

# DIAGNOSIS

- There is extensive diffuse calcinosis –Scleroderma
- The diagnosis in this case was limited cutaneous systemic sclerosis.