

MICOD – 18.03.2024

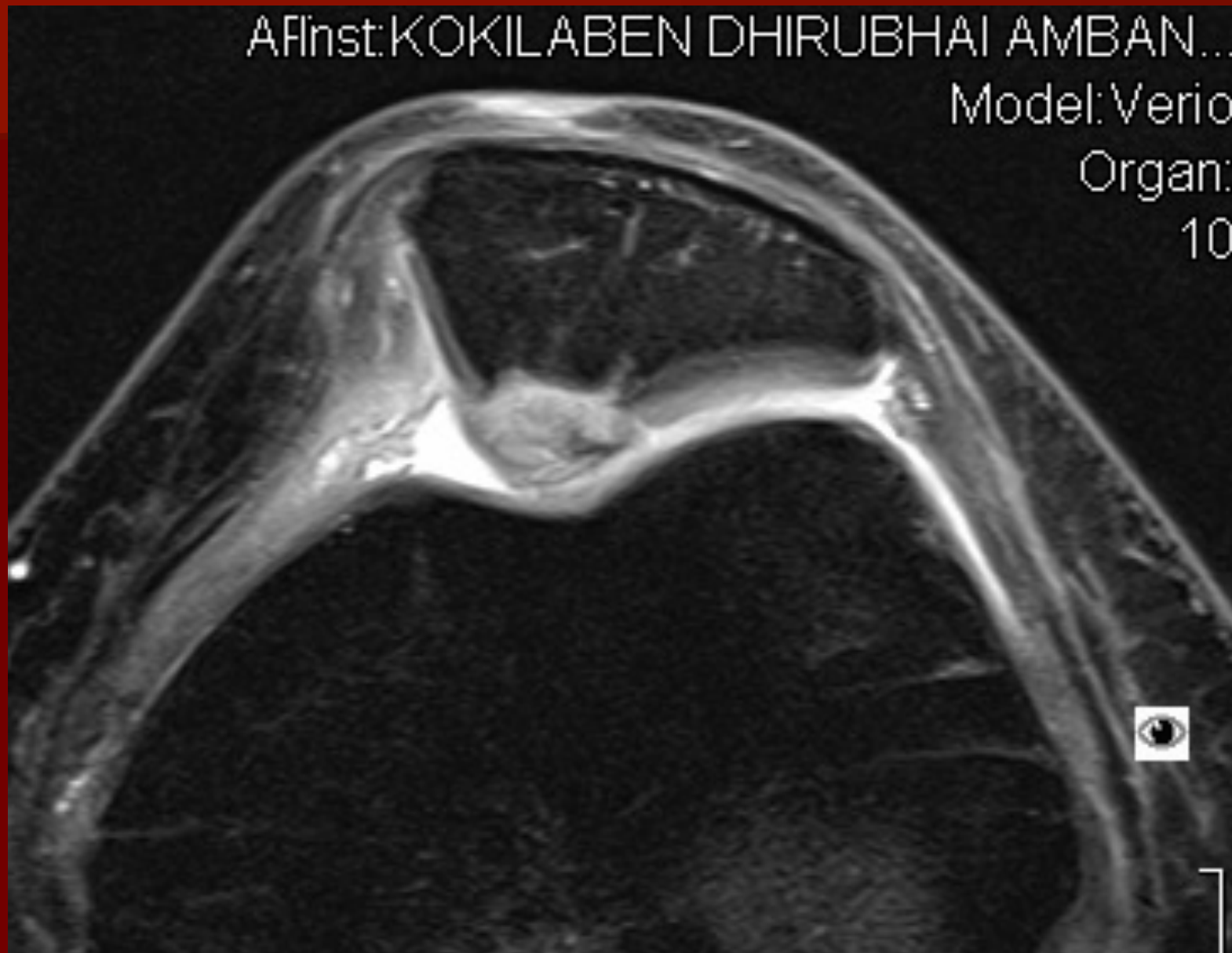
Case contributor – Dr. Darshana Sanghvi

MI-COD

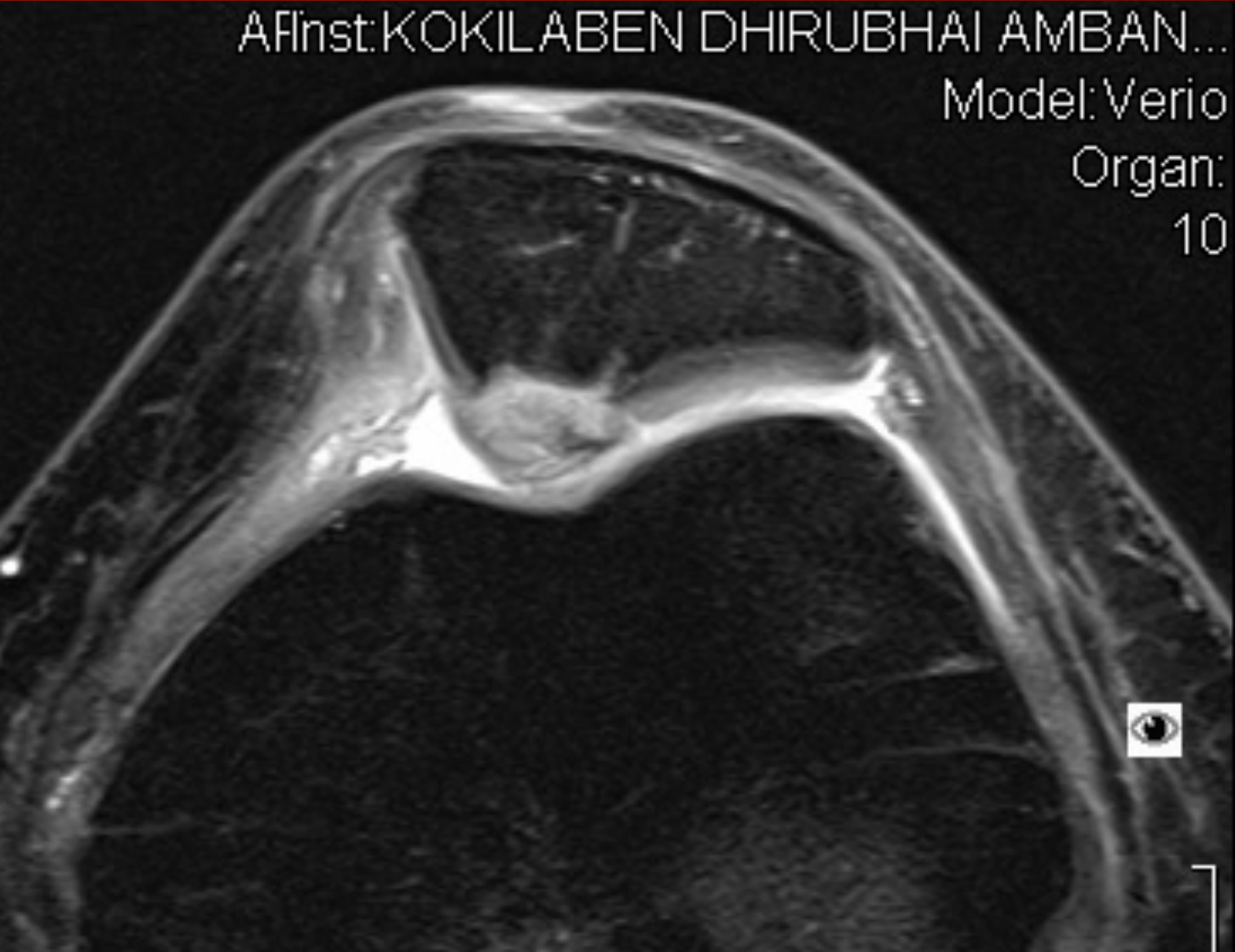
MSS INDIA- Case Of the Day



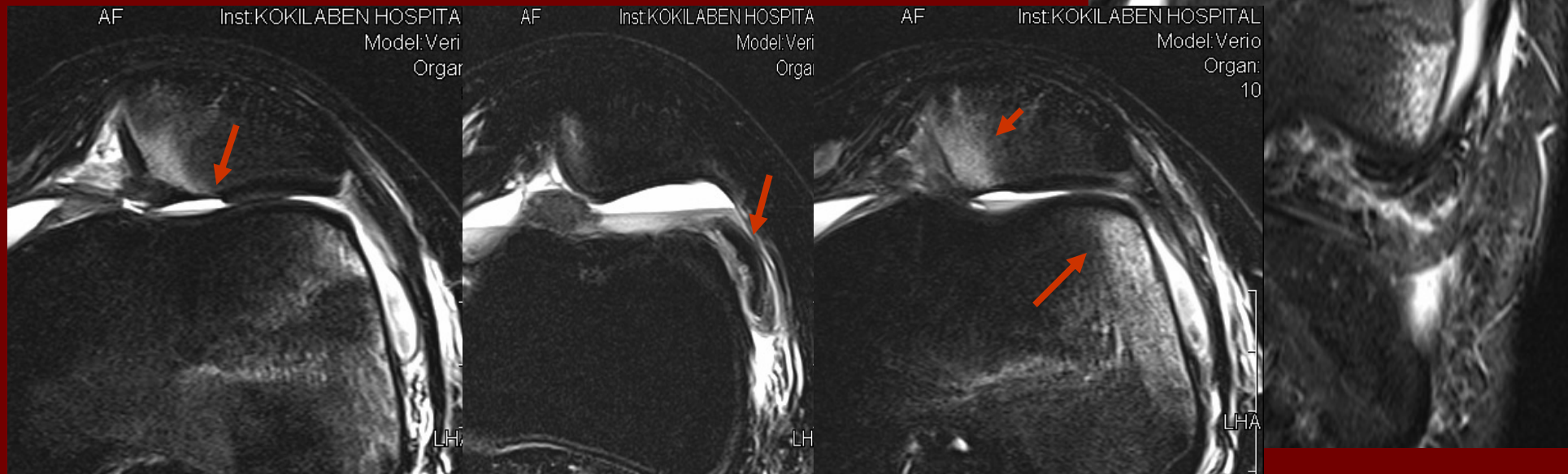
Anterior Pain & Catching Sensation After Autologous Chondrocyte Implantation



Diagnosis: Periosteal Hypertrophy: complication of first generation autologous chondrocyte implantation (ACI) where a periosteal flap was used to cover the chondral defect below which cultured chondrocytes were injected for treating cartilage lesions.

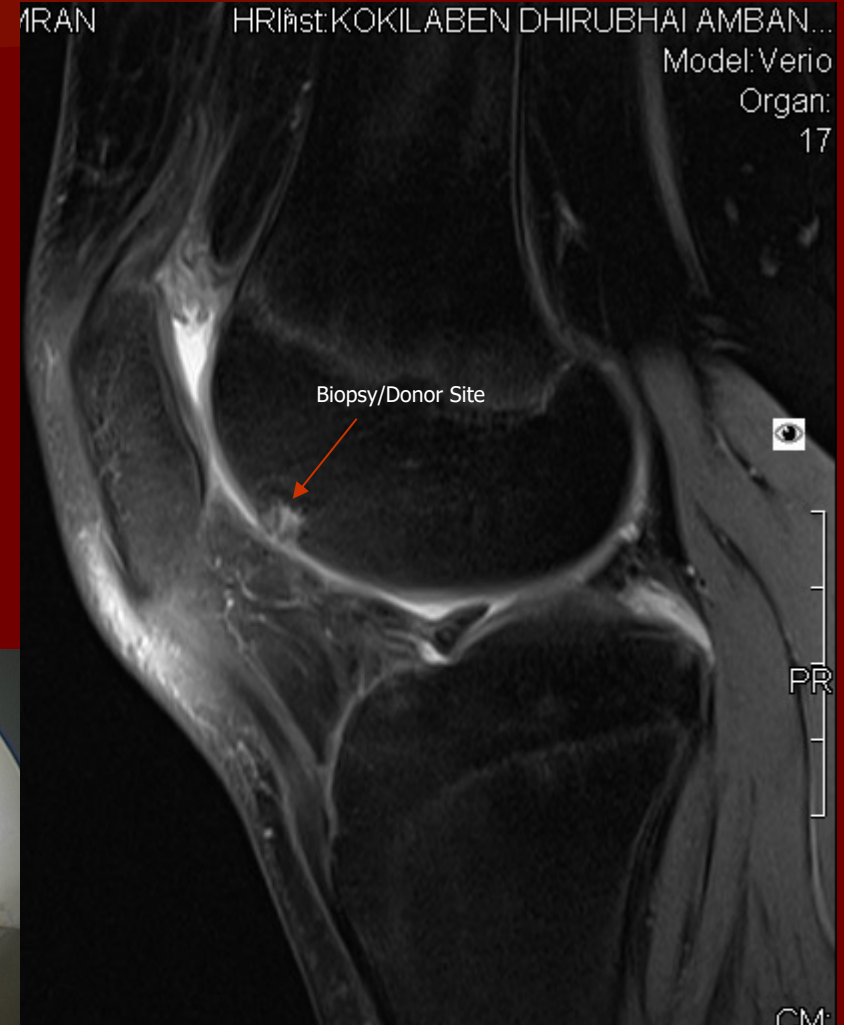
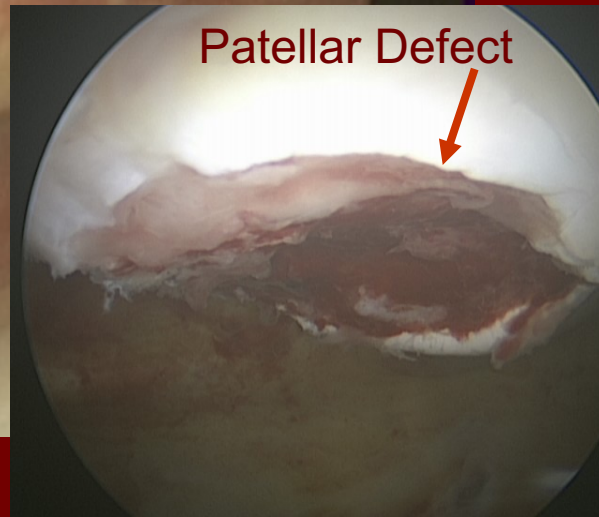
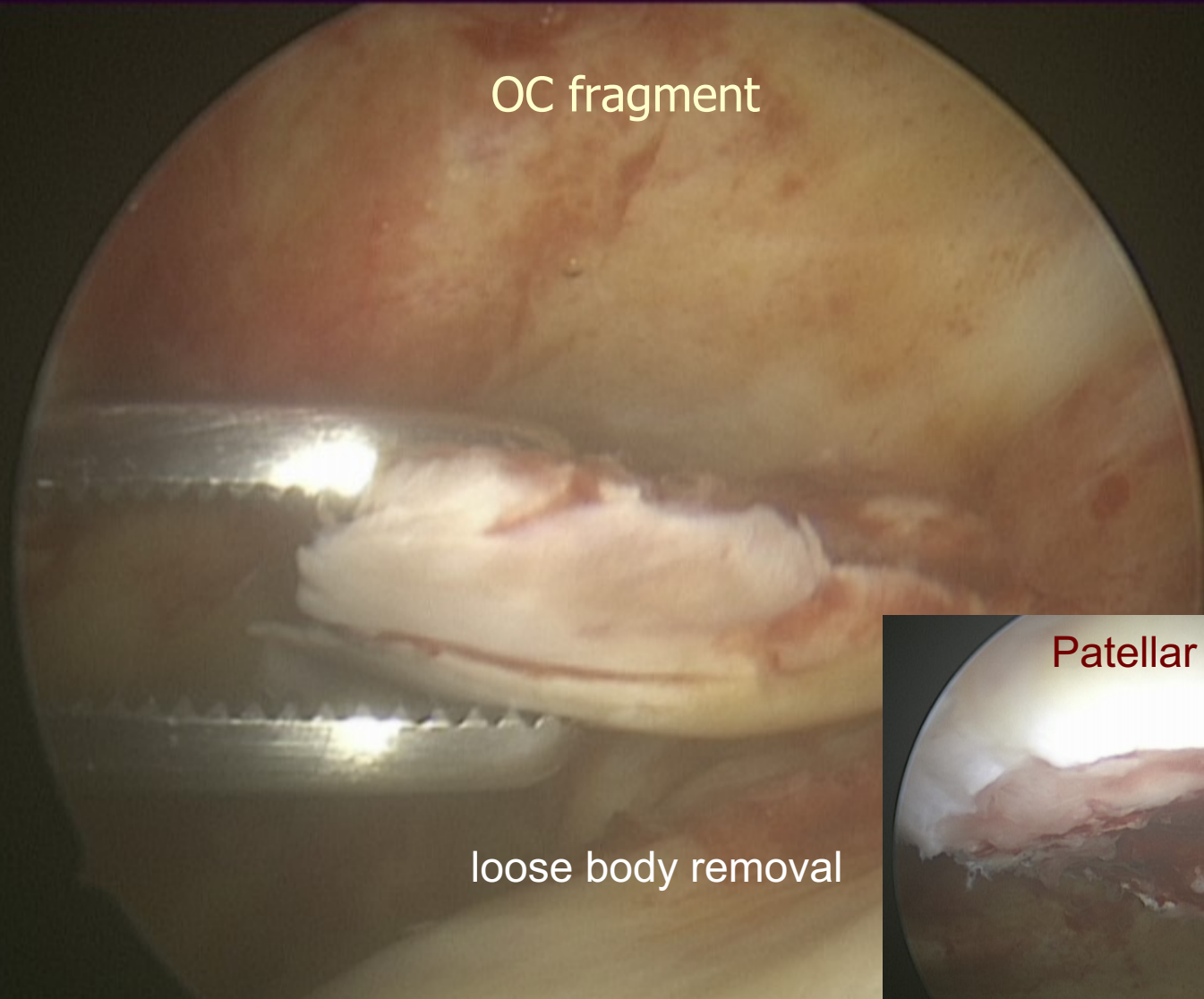


Pre Op MRI: Patient presented with acute patellar dislocation

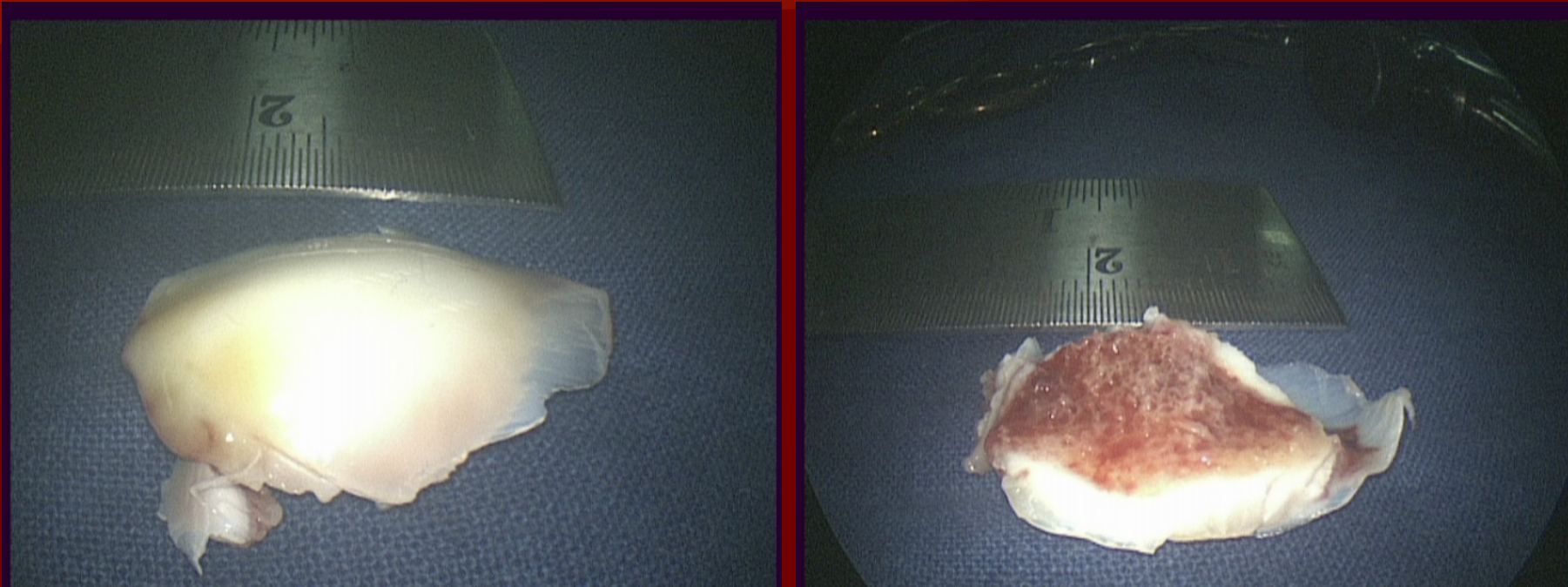


Matching Contusions & OC Fragment in lateral patellofemoral recess

ACI: in first stage loose body was removed & biopsy taken from non weight bearing trochlea to harvest & culture chondrocytes



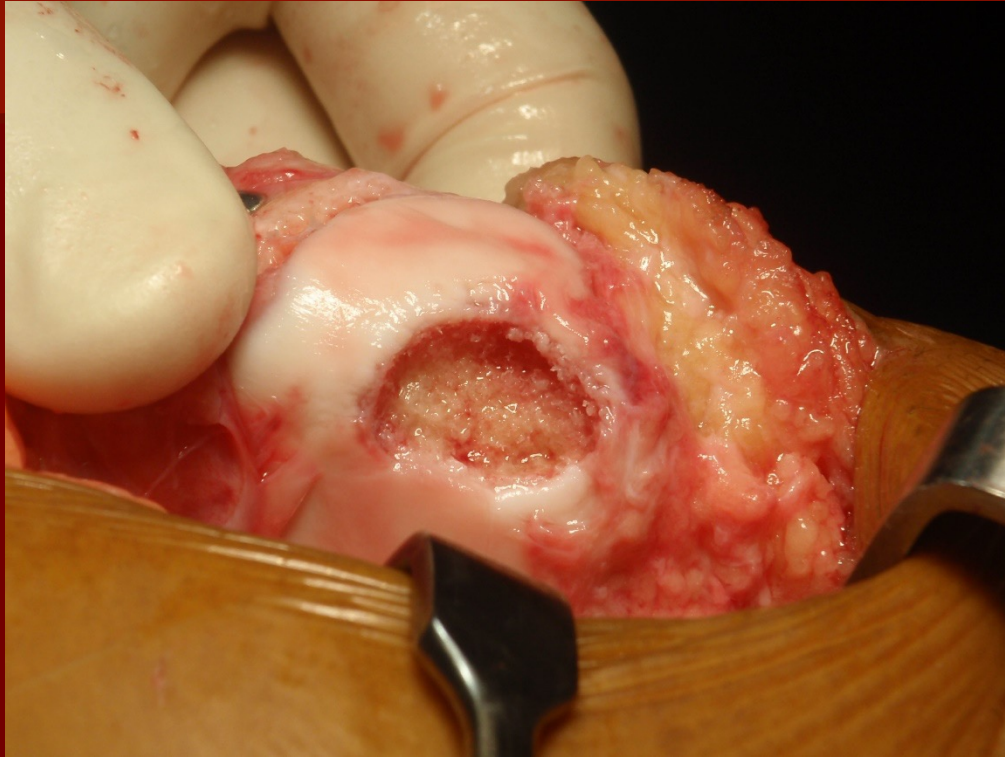
ACI



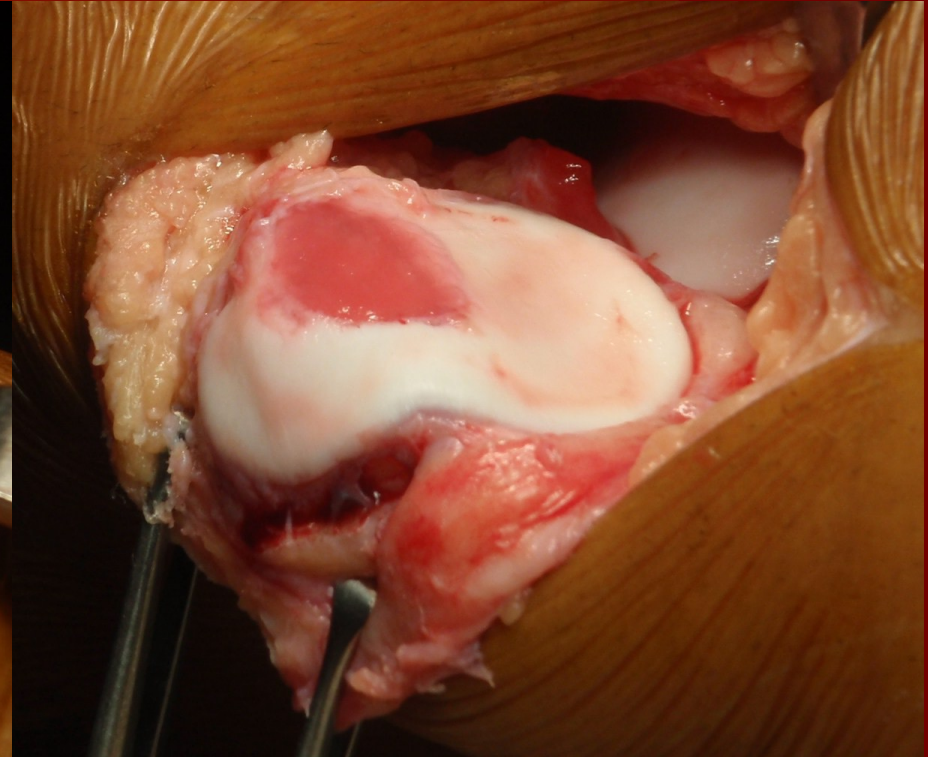
OC fragment

08.10.2010,
loose body
removal

ACI: Stage 2: Six weeks later

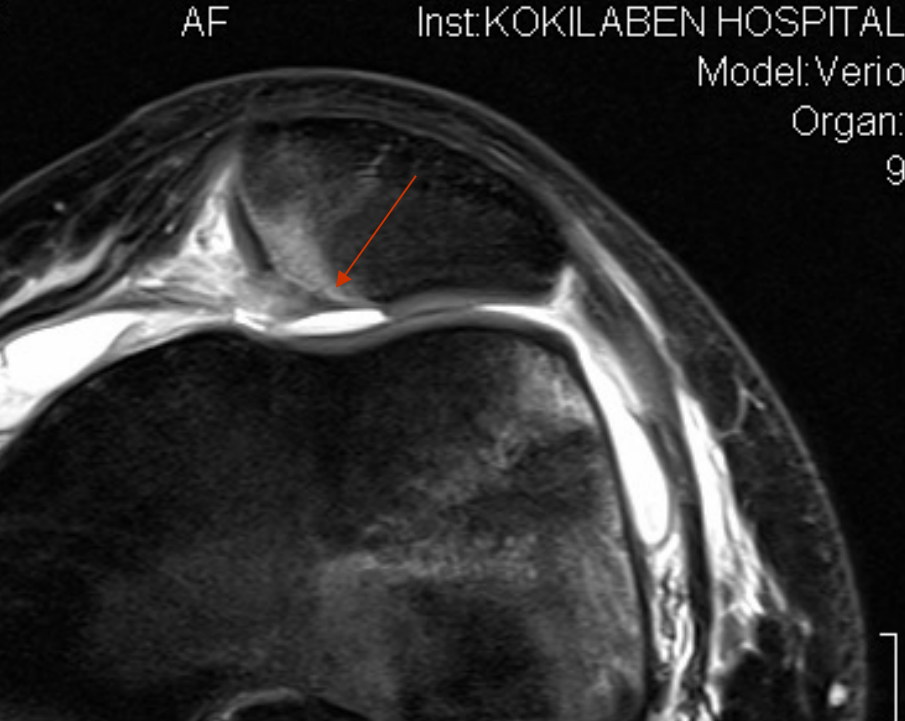


Open ACI 6 weeks later (stage 2)
shows debrided osteochondral lesion

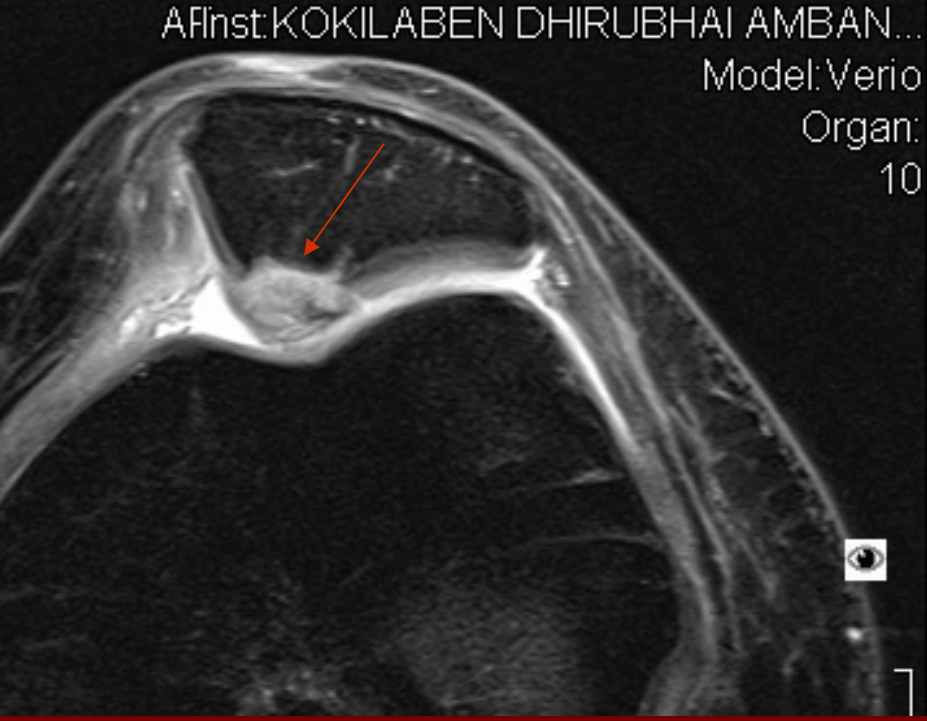

Harvested chondrocytes were filled into the defect
which was covered with a periosteal flap

Diagnosis: Complication of first generation ACI: Periosteal Hypertrophy requiring repeat arthroscopic debridement



Pre operative 07.10.2010



Post ACI 22.06.2011