

MICOD -14/03/24

Case contributor – Dr. Sonal Saran

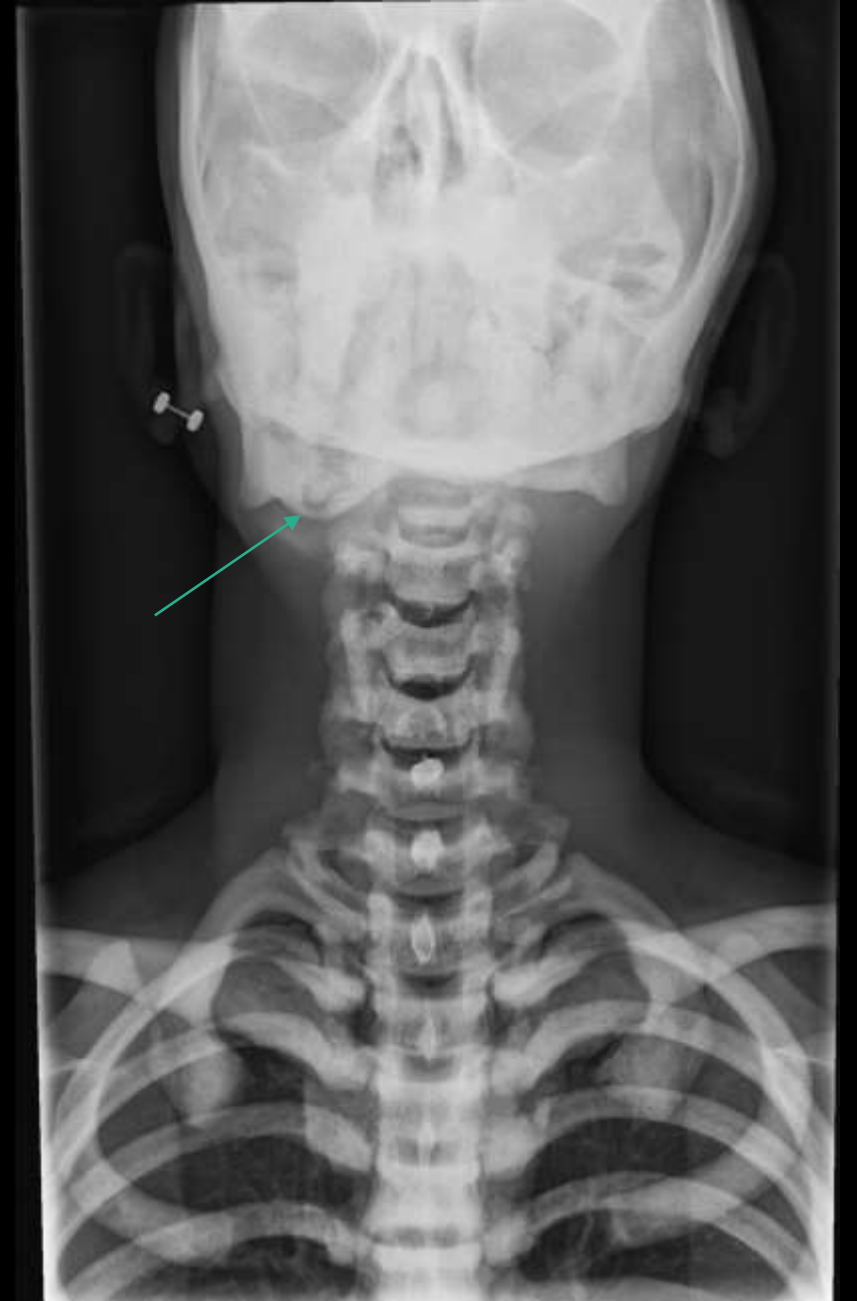
MI-COD

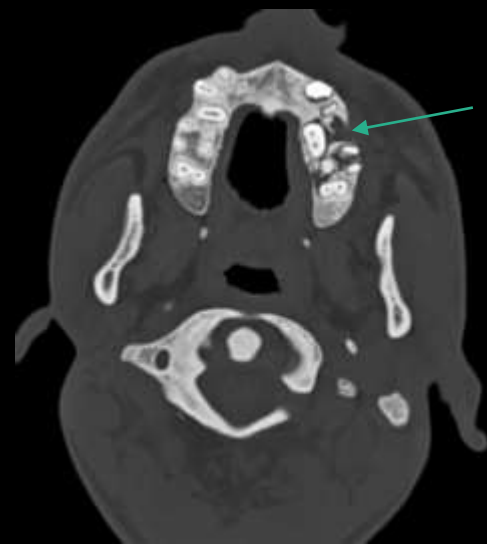
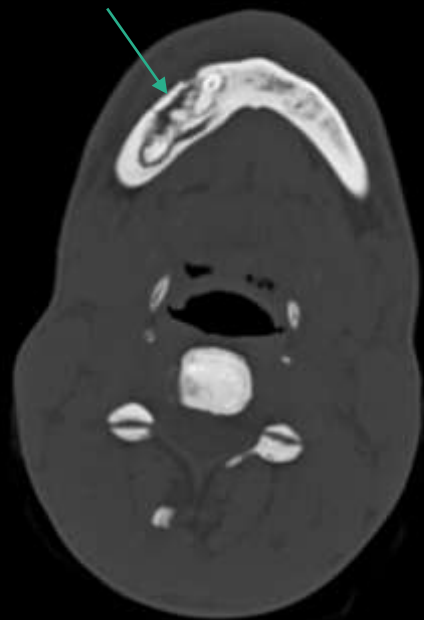
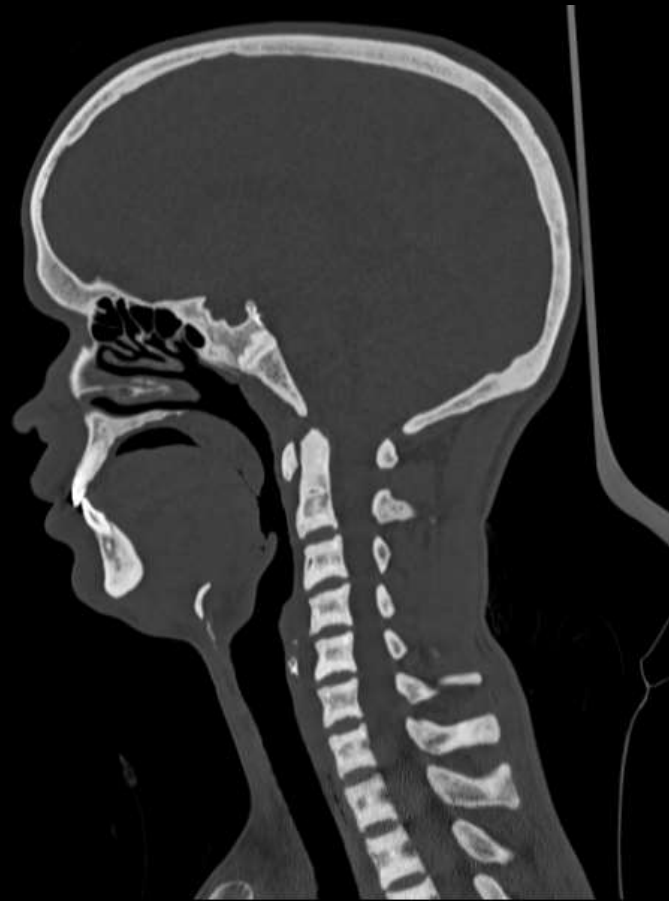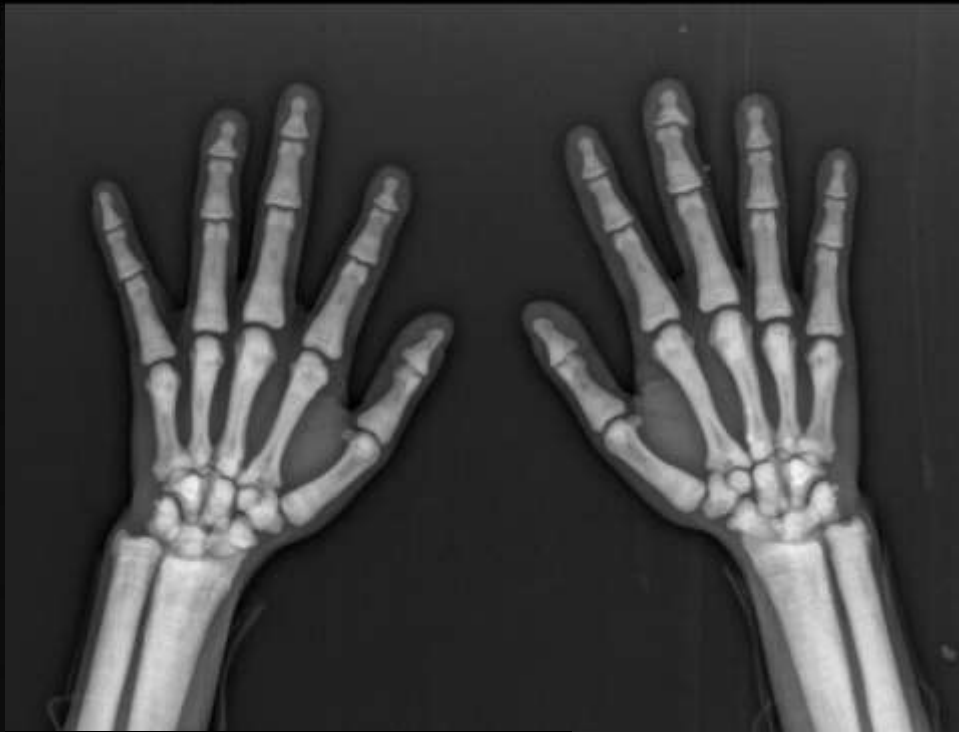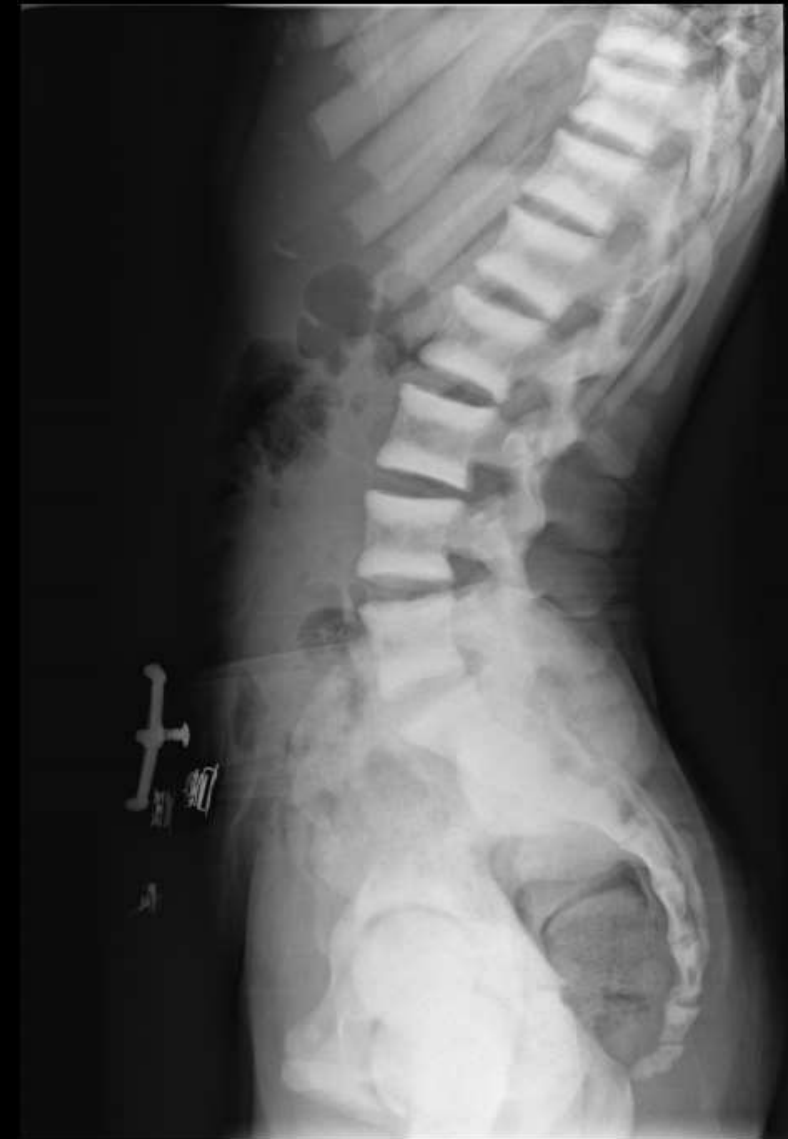MSS INDIA- Case Of the Day



18 year old male
presented with pain and
swelling in jaw with sinus
formation.

Past history of # tibia and
fibula 3 years back





Osteopetrosis with mandibular
osteomyelitis