


MICOD – 29/02/2024

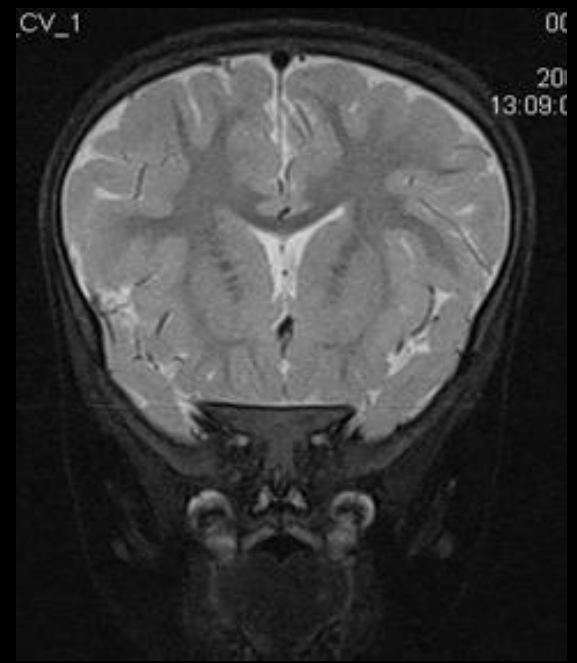
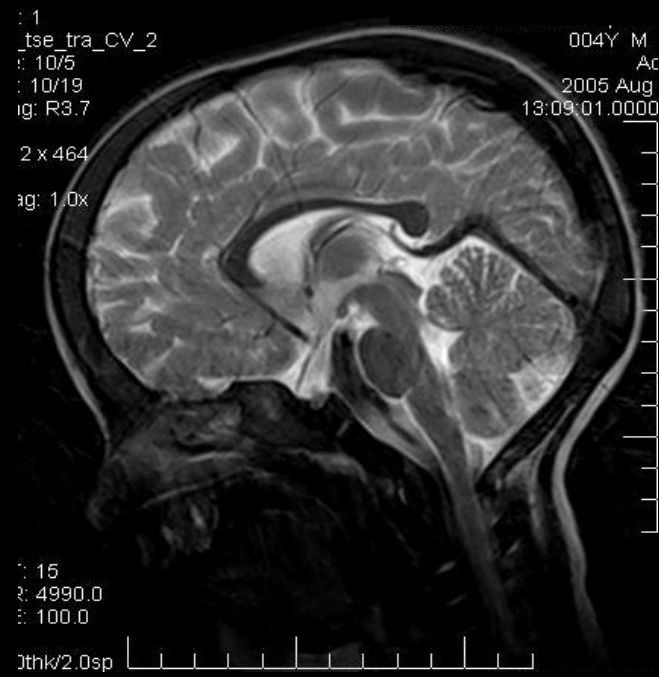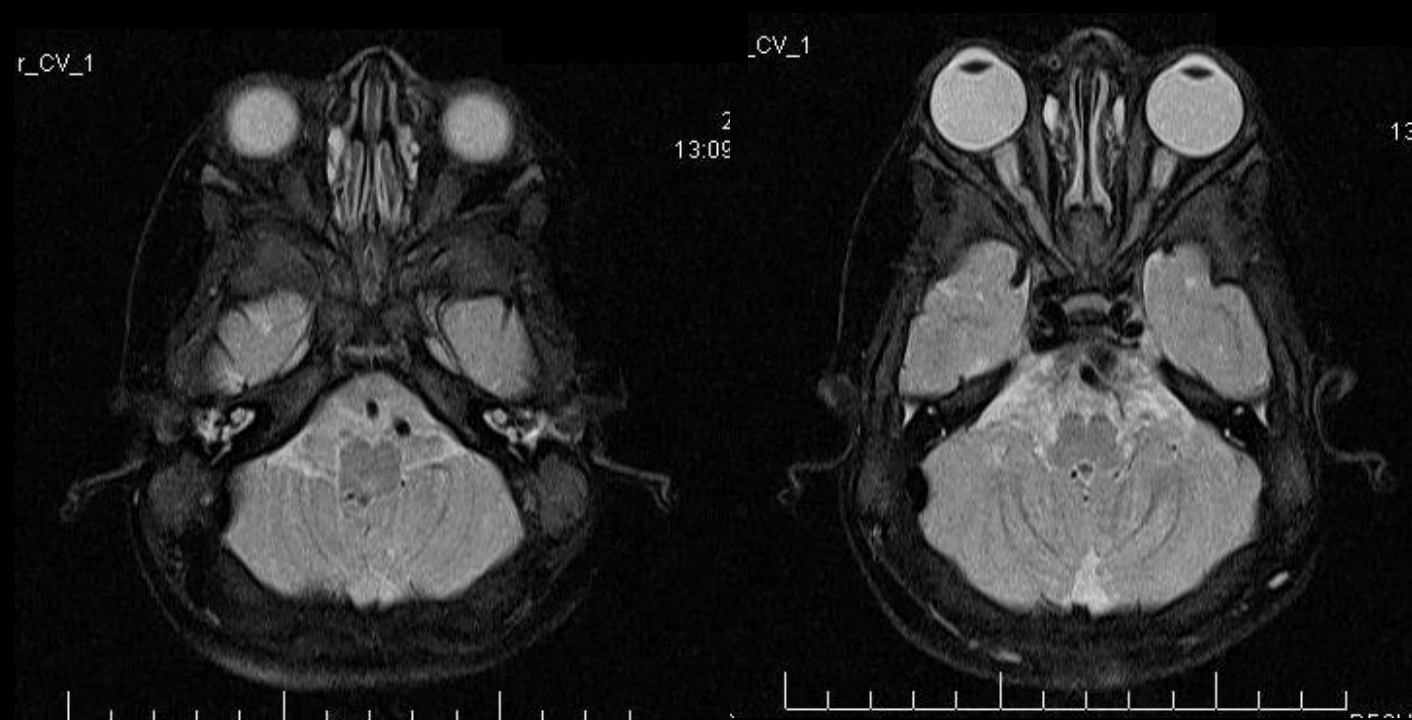
Case contributor – DR. VIJINDER ARORA

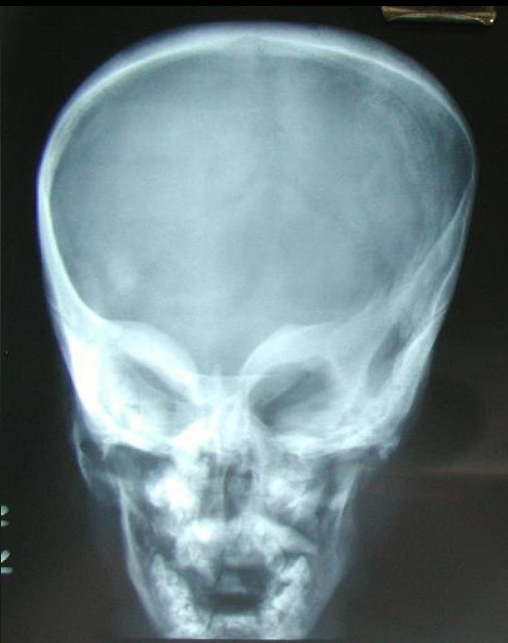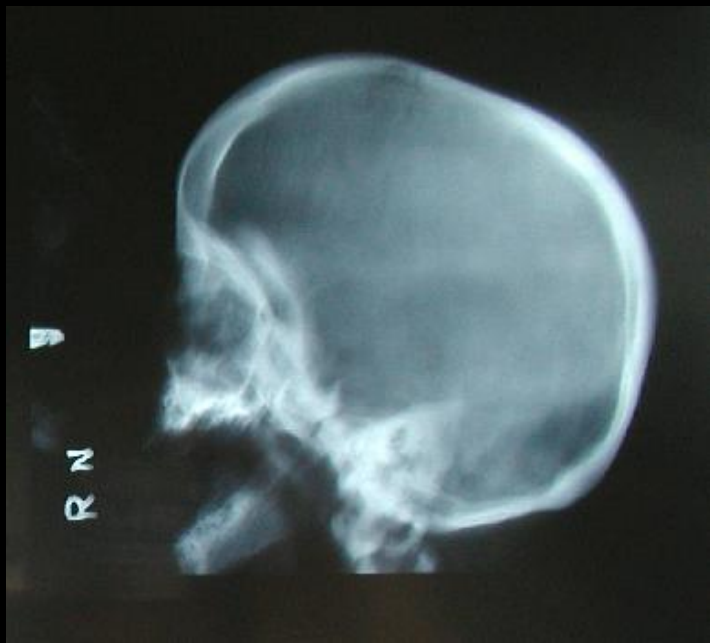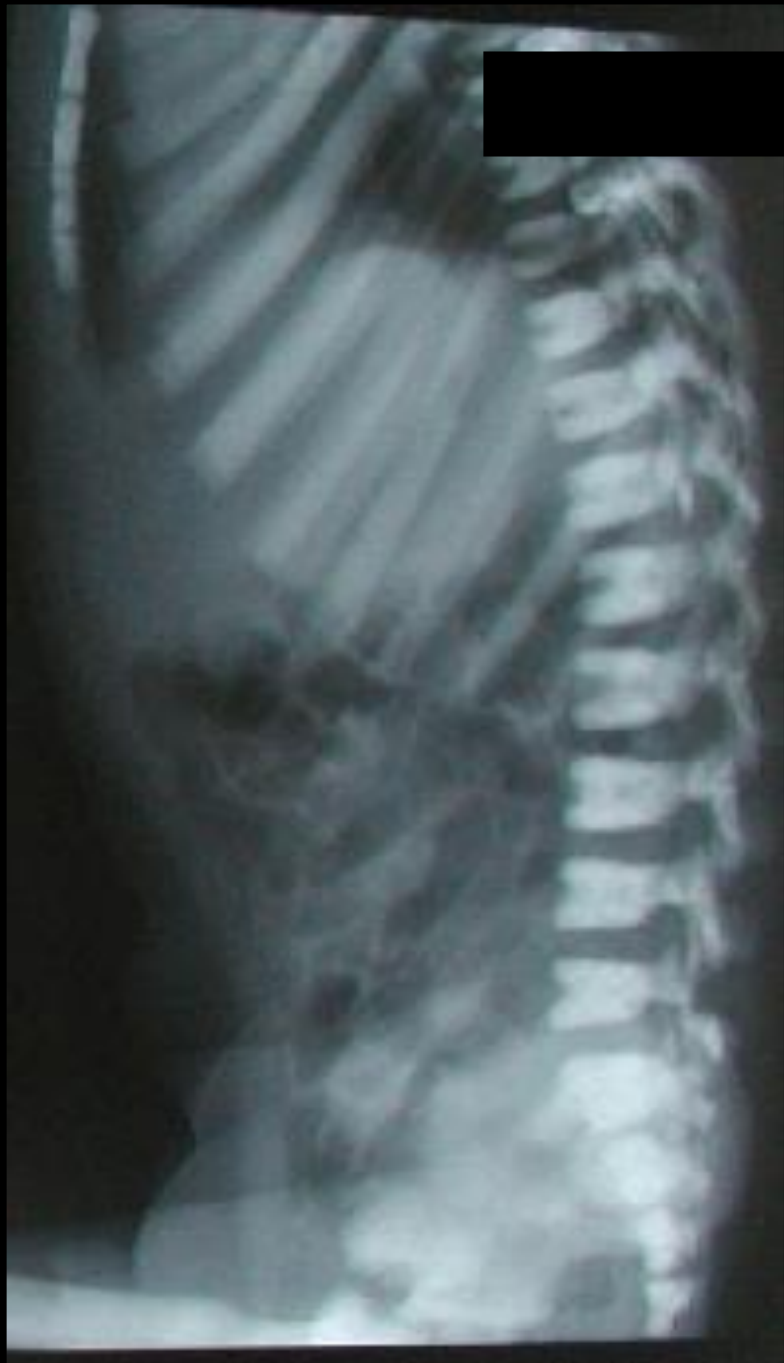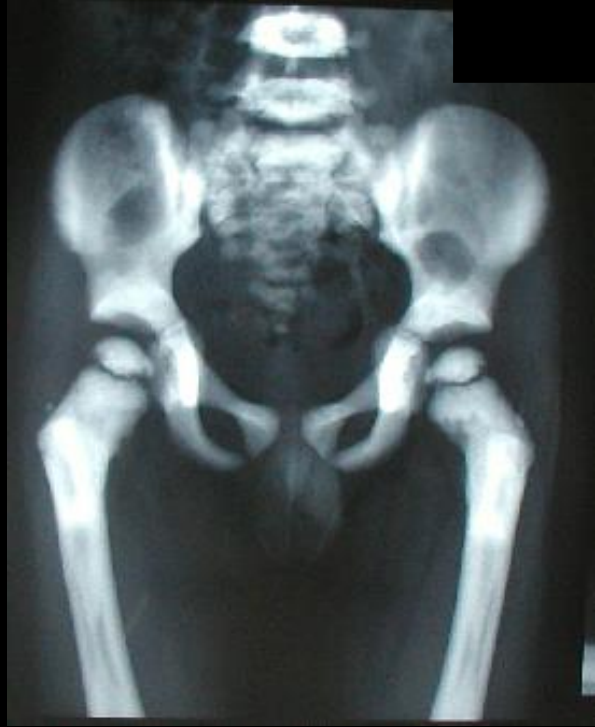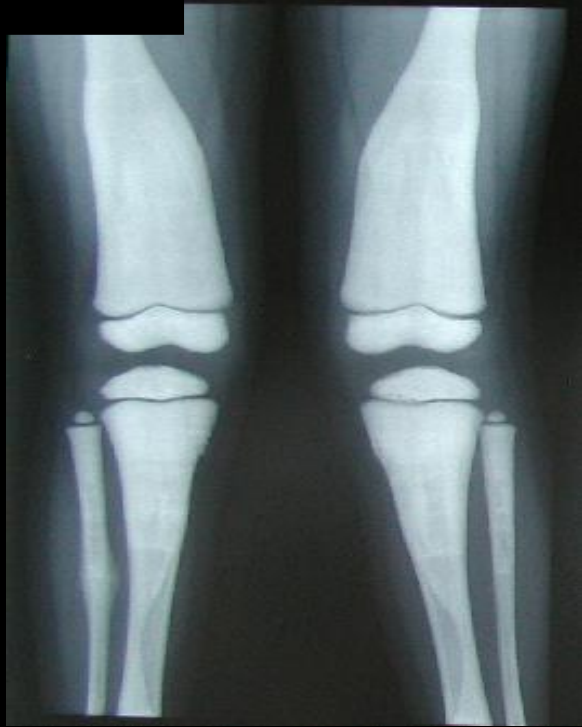MI-COD

MSS INDIA- Case Of the Day



4.5-year-old boy
presenting with
blindness





Osteopetrosis

- The most common ophthalmic complication is compressive optic nerve neuropathy leading to atrophy, and subsequently blindness, due to the narrowing of the surrounding optic foramen.
- Other causes of diminution of vision include progressive chorioretinal degeneration and obstructive hydrocephalus
- Proptosis may result from shallow orbits caused by the thickening of the orbital bones

Mukherjee B, Agrawal A, Noronha OV. Blindness as the presenting sign of osteopetrosis in a child. *Oman J Ophthalmol.* 2022 Mar 2;15(1):117-118. doi: 10.4103/ojo.ojo_113_21. PMID: 35388255; PMCID: PMC8979376.