


MICOD – 27/02/2024

Case contributor – DR. VIJINDER ARORA

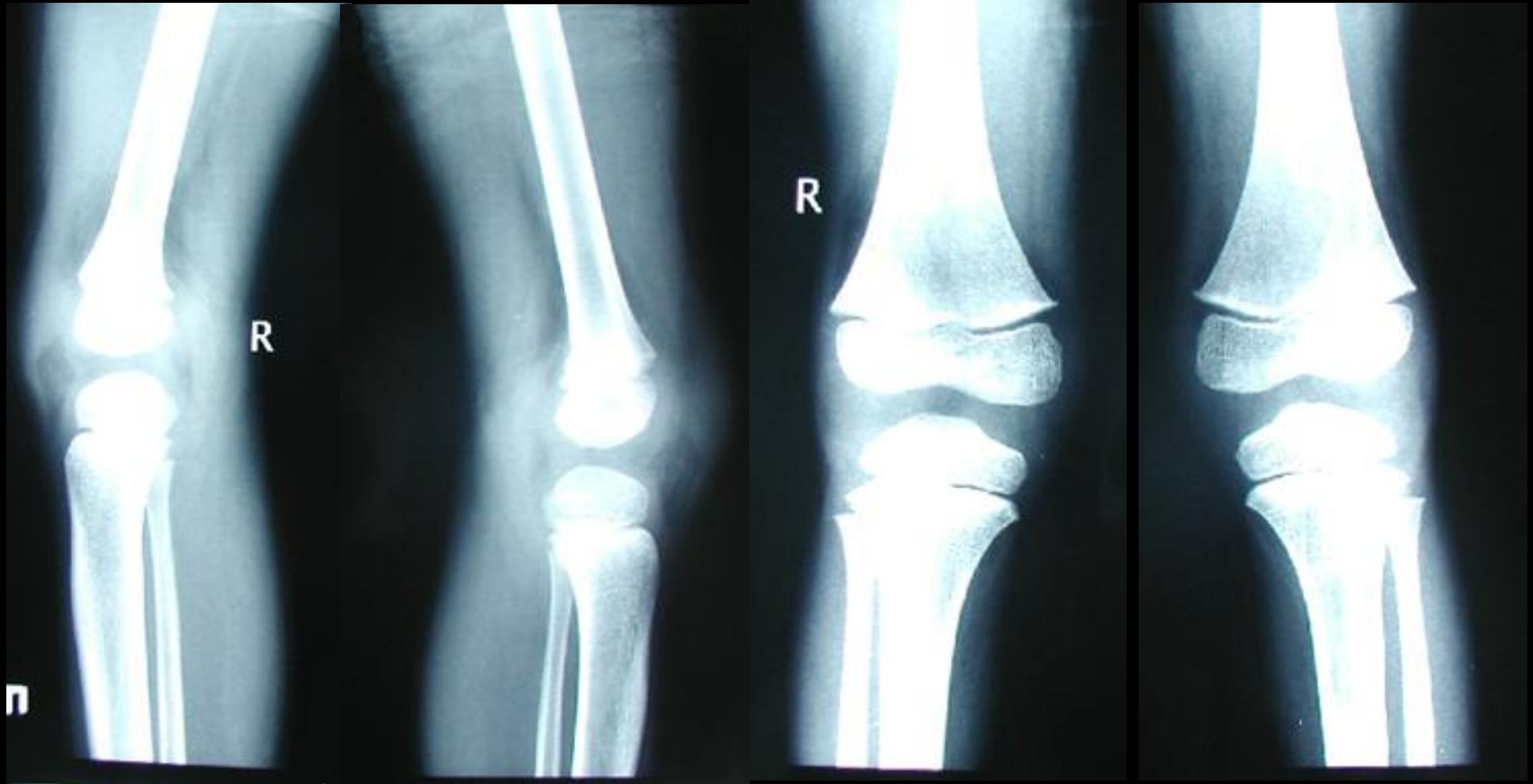
MI-COD

MSS INDIA- Case Of the Day

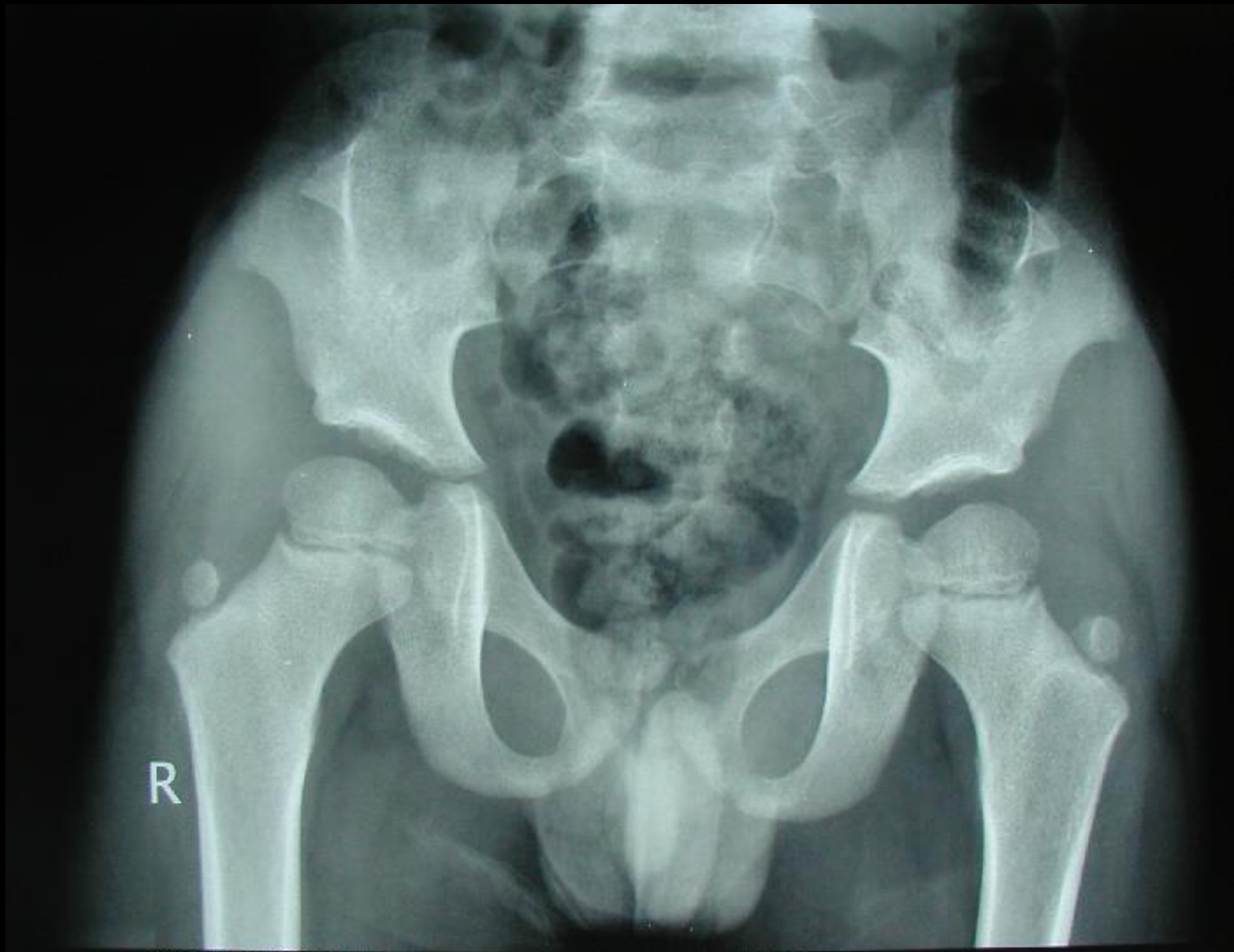


Case 1a

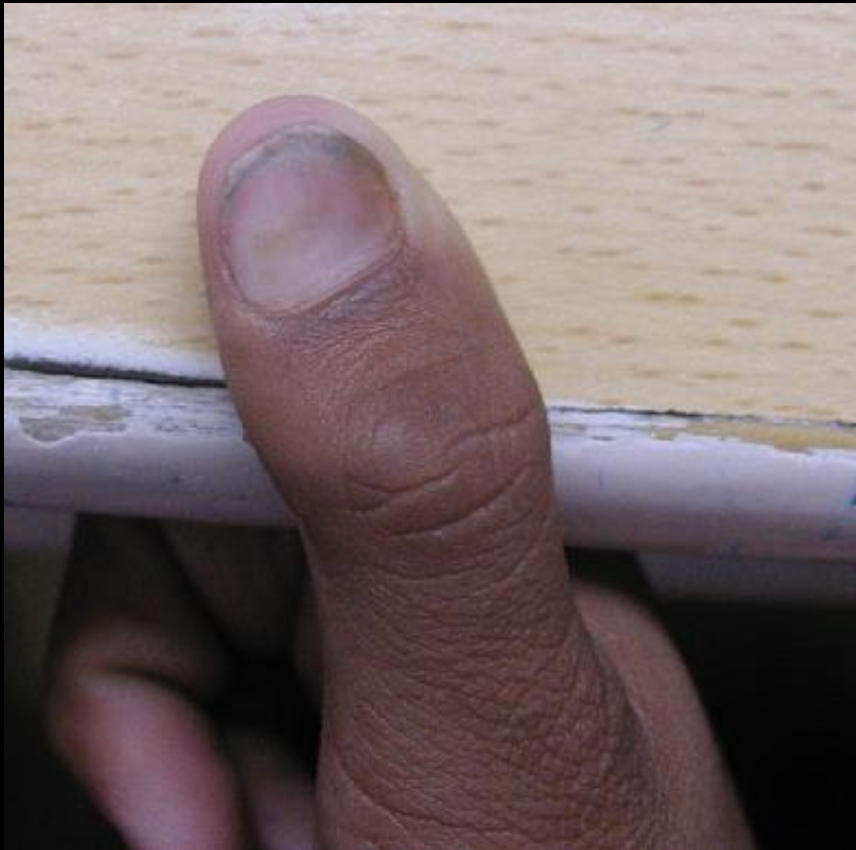12-year-old boy with feeling of instability while walking



Case 1b



NAIL-PATELLA SYNDROME



- A rare autosomal dominant condition which results from a symmetrical meso & ectodermal abnormality.
- Dysplasia of the fingernails and toenails;
- Aplasia and/or hypoplasia of the patellae
- Elbow abnormalities may include cubitus valgus; and antecubital pterygia.
- Bilateral posterior iliac horns due to exostoses arising from the posterior aspect of the iliac bones are present in as many as 80% of patients; this finding is considered pathognomonic for the syndrome.