


MICOD – 26/02/2024

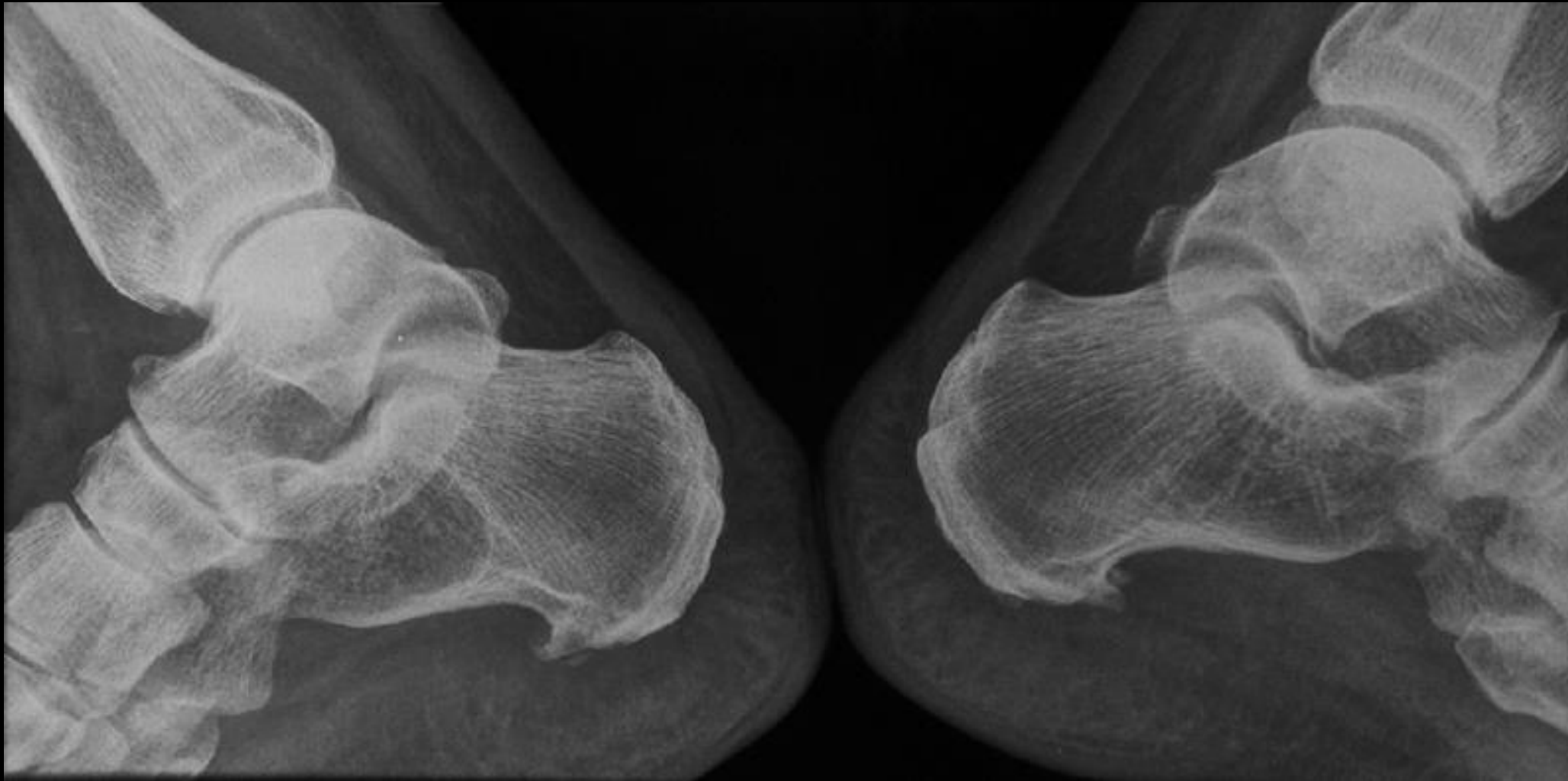
Case contributor – DR. VIJINDER ARORA

MI-COD

MSS INDIA- Case Of the Day



49yrs lady presenting with pain on brisk walking



Intraosseous lipoma in right calcaneus

- Rare lesions (0.1% of primary bone tumors) and 10 to 15% are within the calcaneus.
- localised at the junction of anterior & middle thirds of the bone under the subtalar joint.
- Many of those lipomas (50%) present calcifications or central ossifications which are secondary to fat necrosis.
- They are usually entirely asymptomatic. However pain may be present especially in cases of acute fat necrosis