

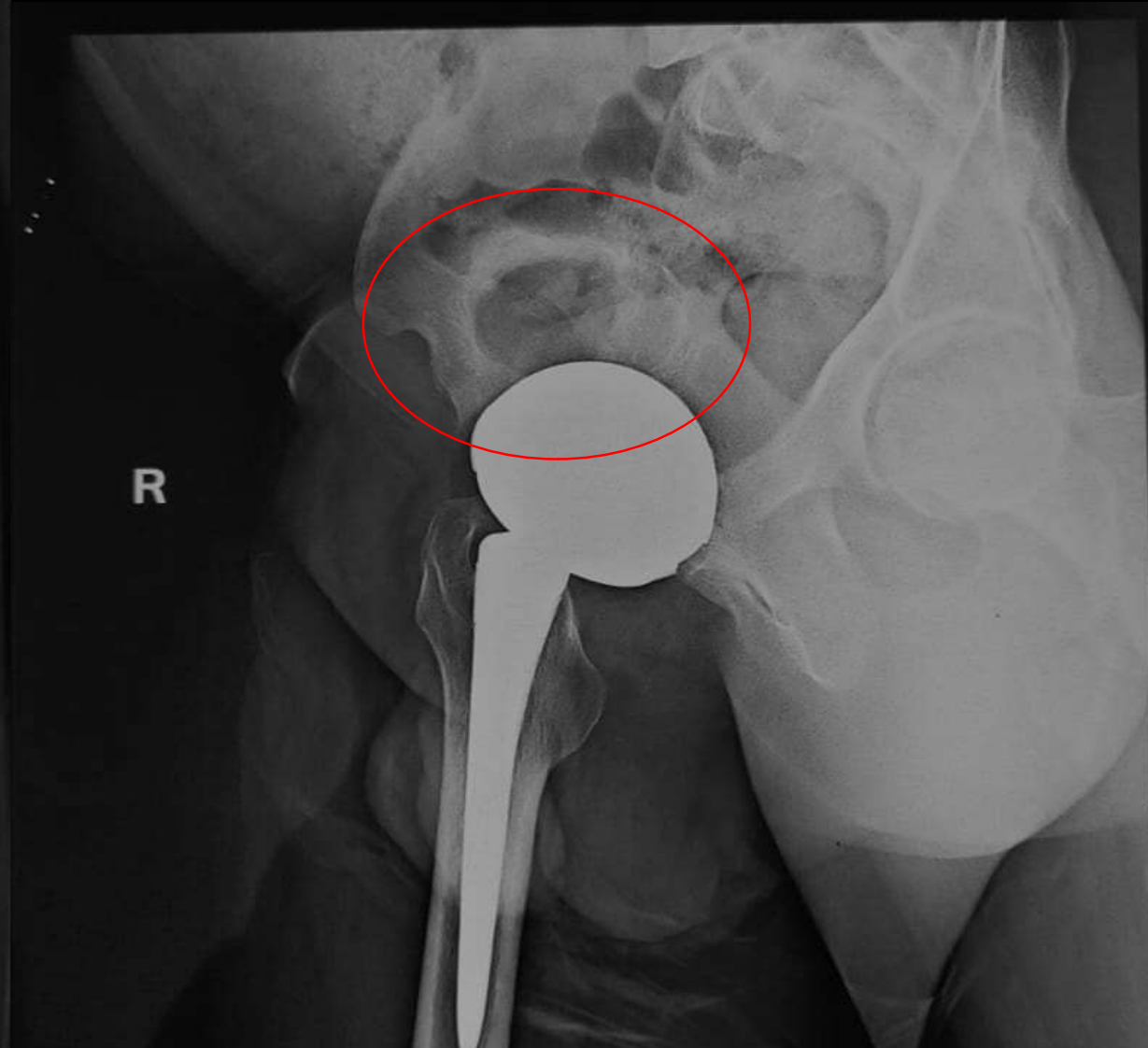
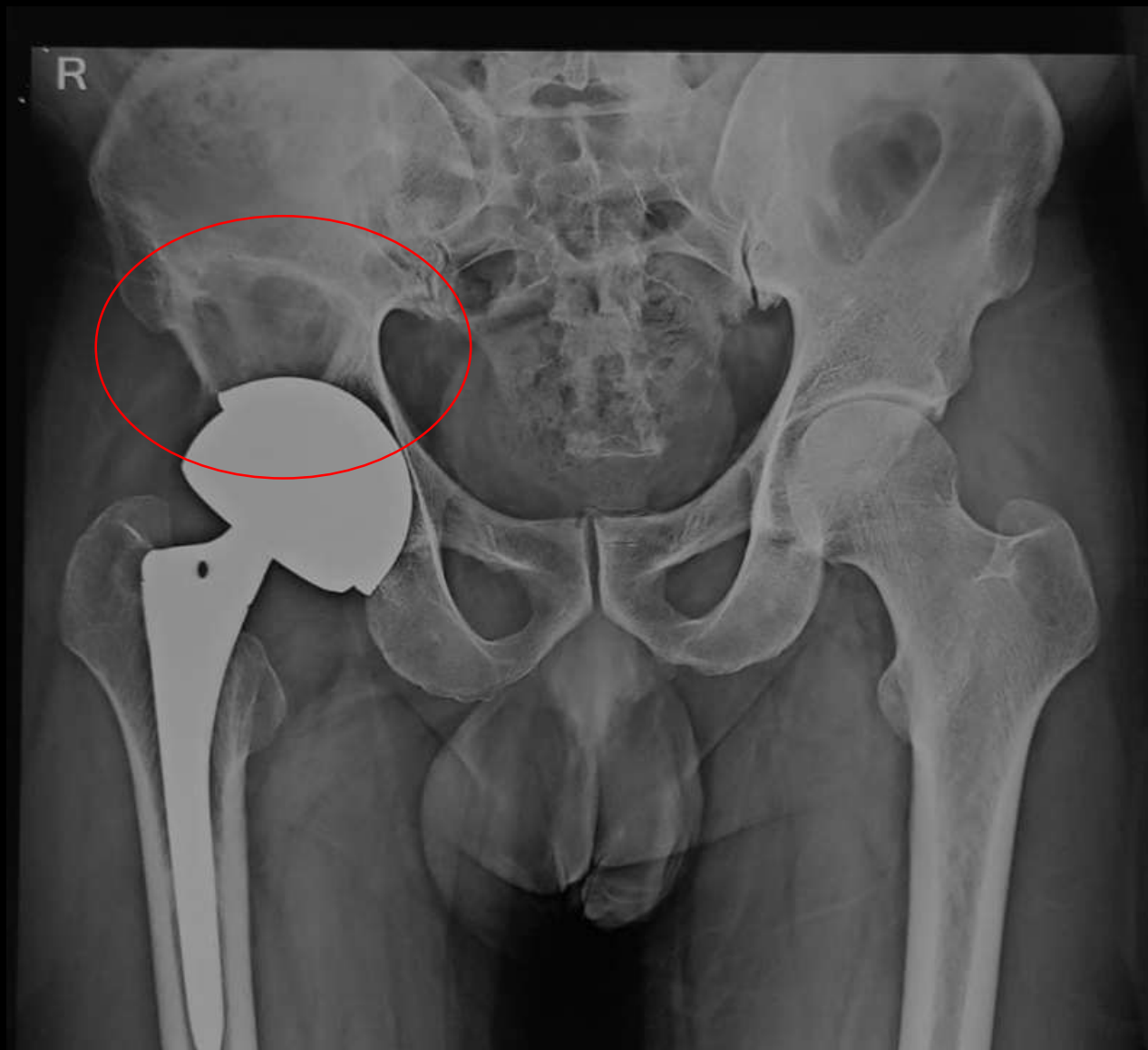MICOD -
Case contributor – Dr. Sonal Saran

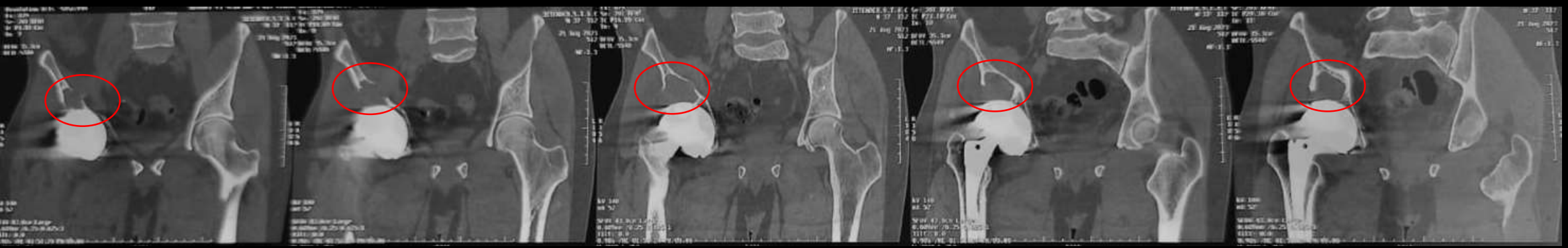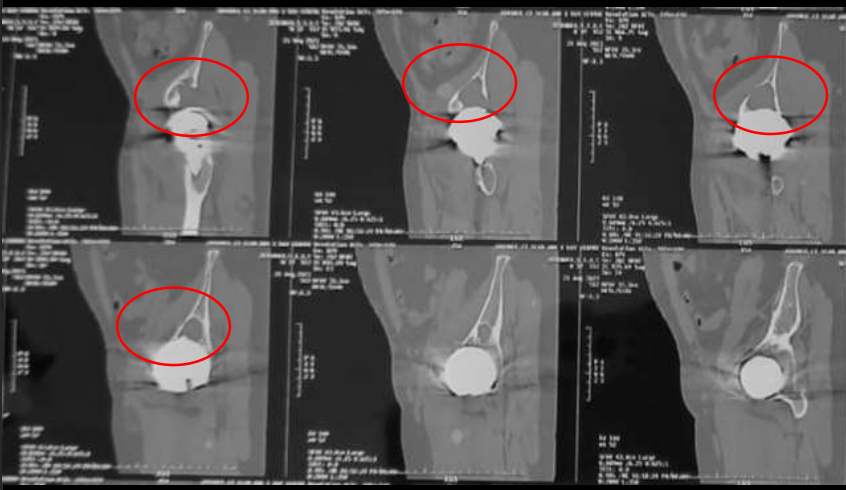
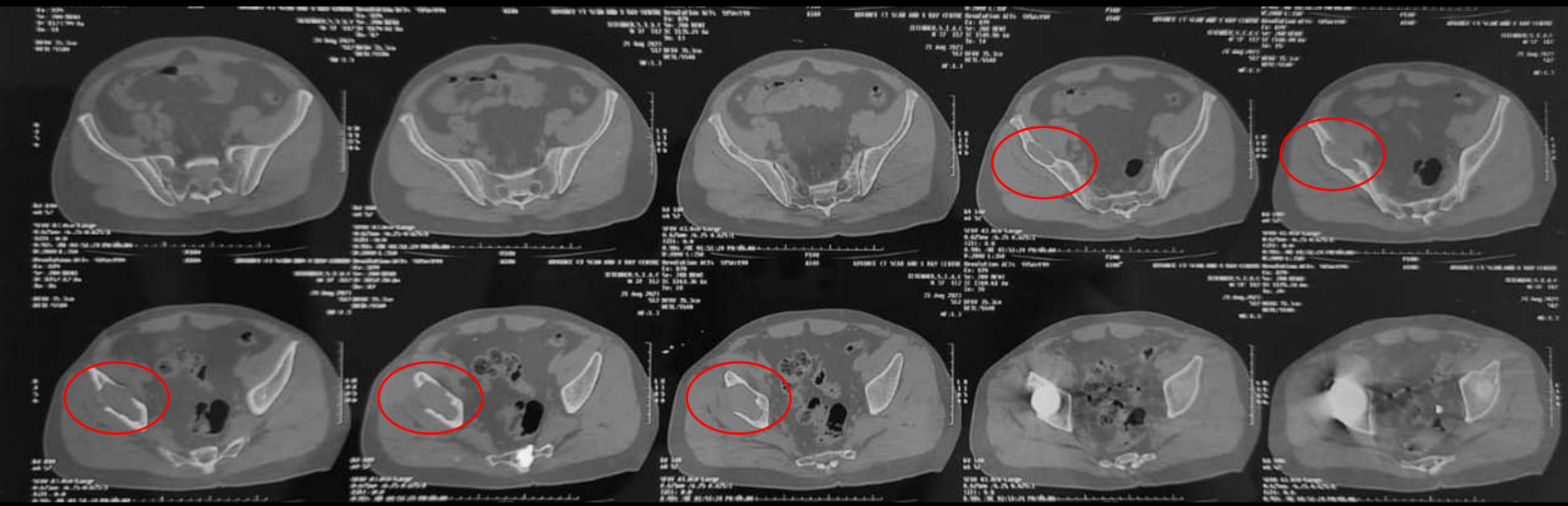
MI-COD

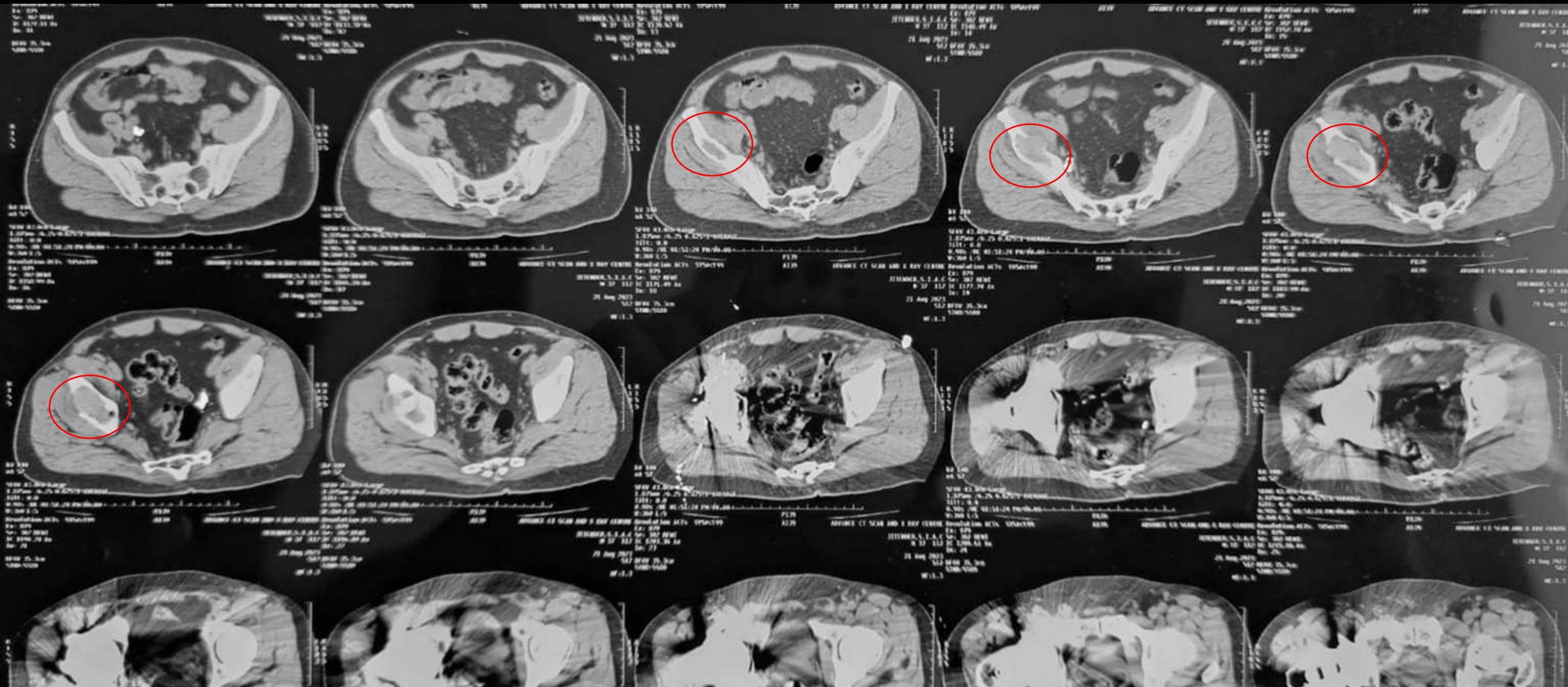
MSS INDIA- Case Of the Day

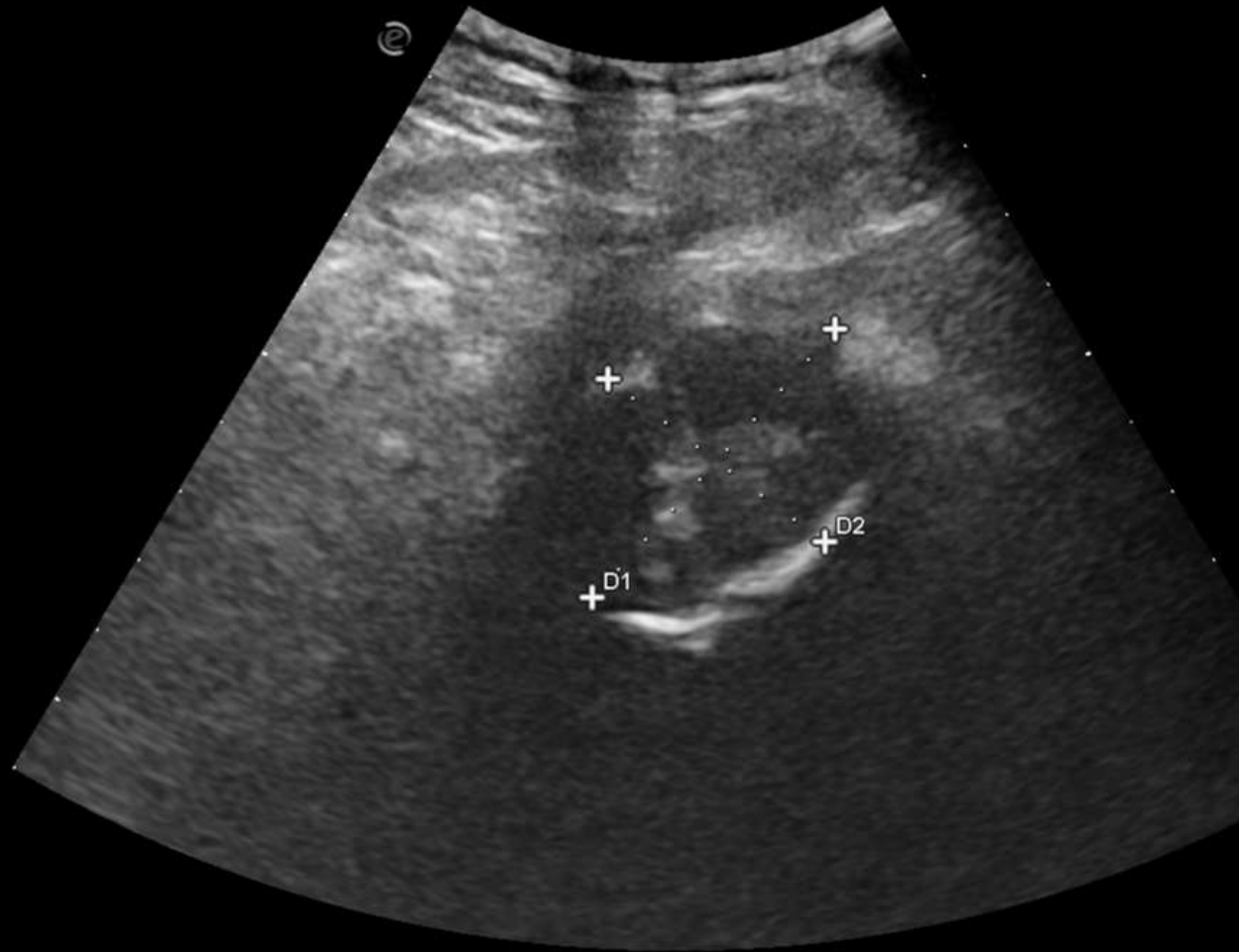

A 45 year old male with hip surgery in 2009









D1 44.9 mm
D2 33.7 mm

Aseptic loosening of hip joint replacement with Pseudotumor

- **Aseptic loosening** is usually considered a long-term complication and is often considered as the most common complication of metal-on-metal bearings.
- Adverse reaction to metal is associated with the development of cystic or solid periprosthetic pseudotumors.
- Classically, a pseudotumor is defined as a non-neoplastic and non-infectious mass resulting from a circumscribed fibrous exudate of inflammatory origin, fluid accumulation, or other cause.