

MICOD – 20/02/2024

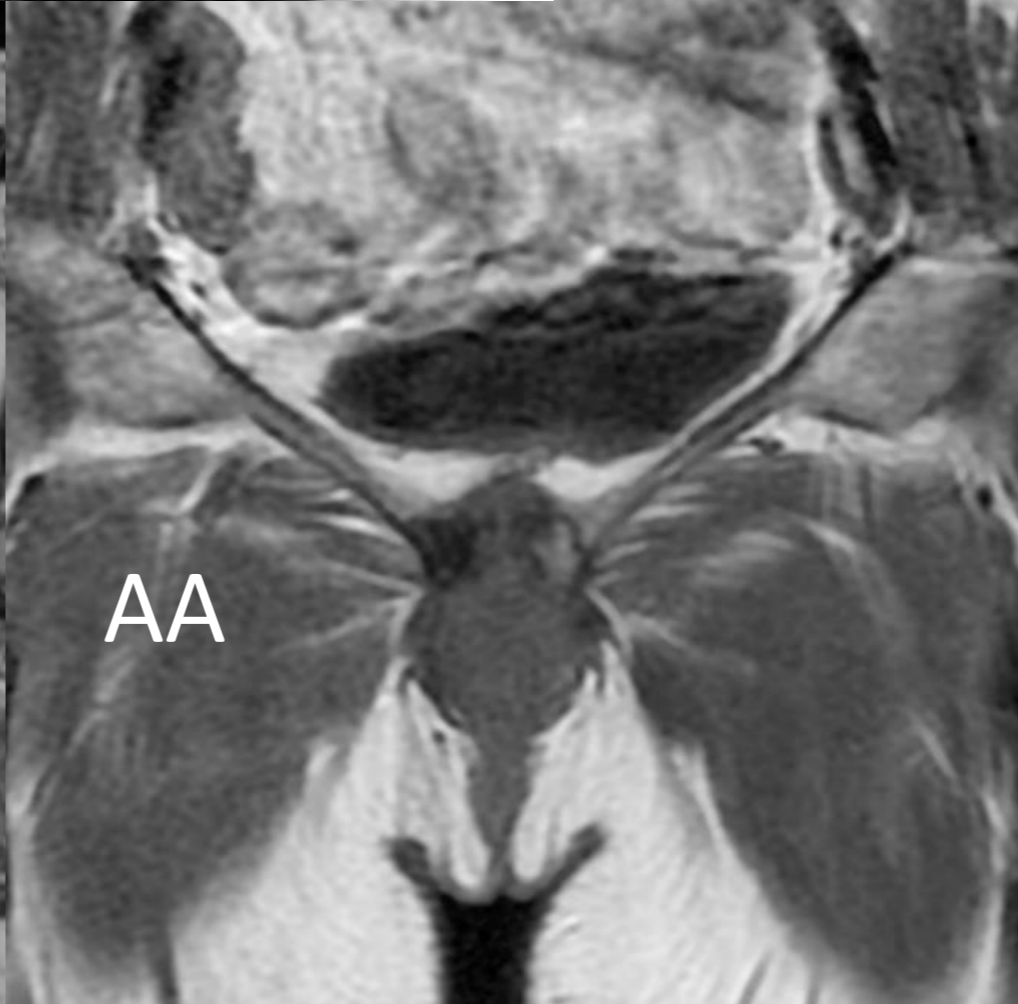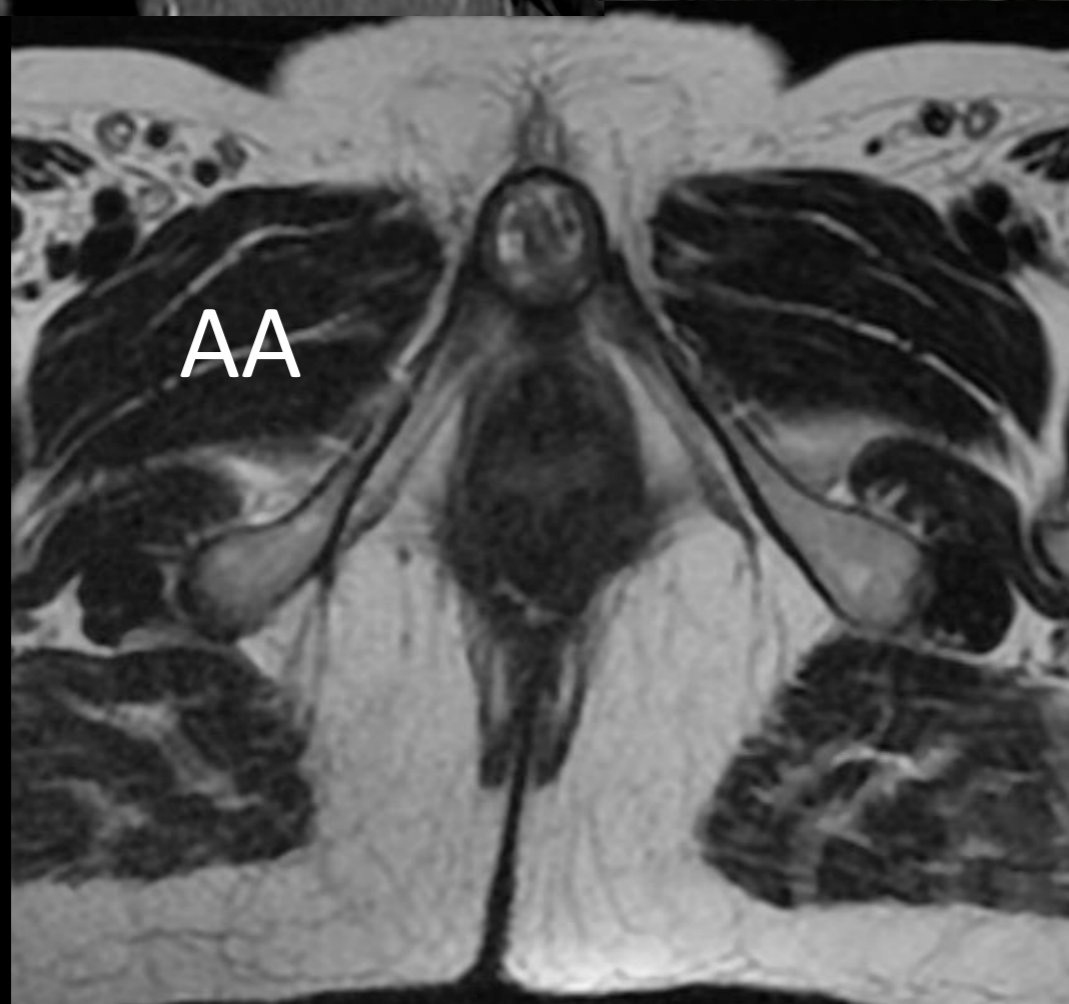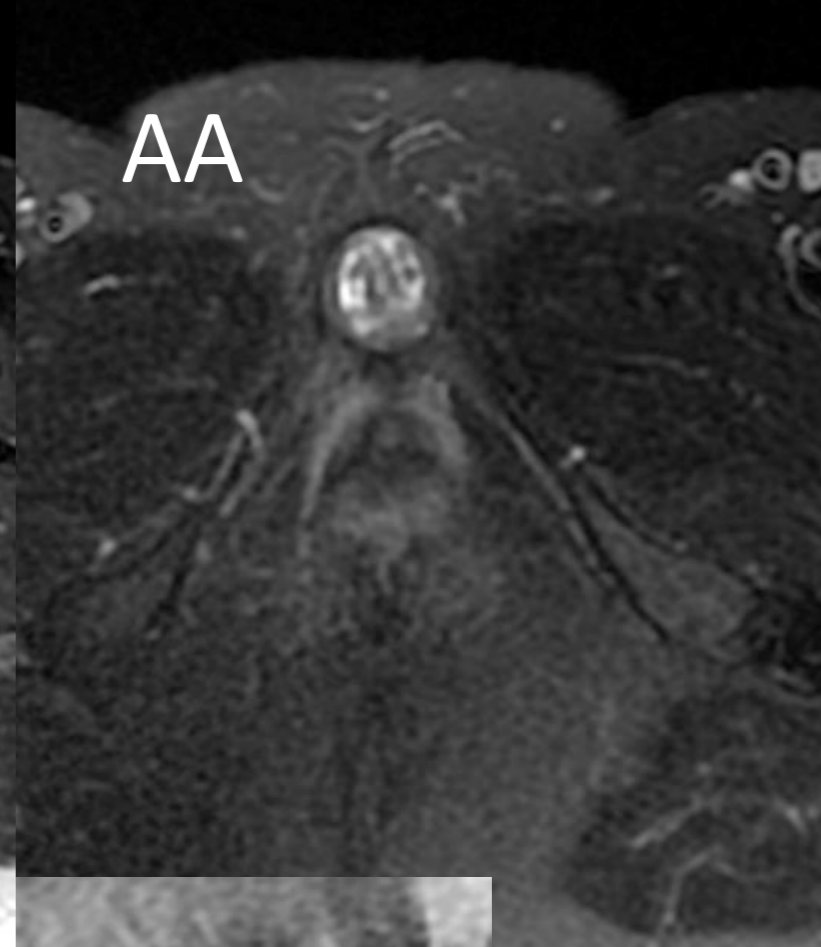
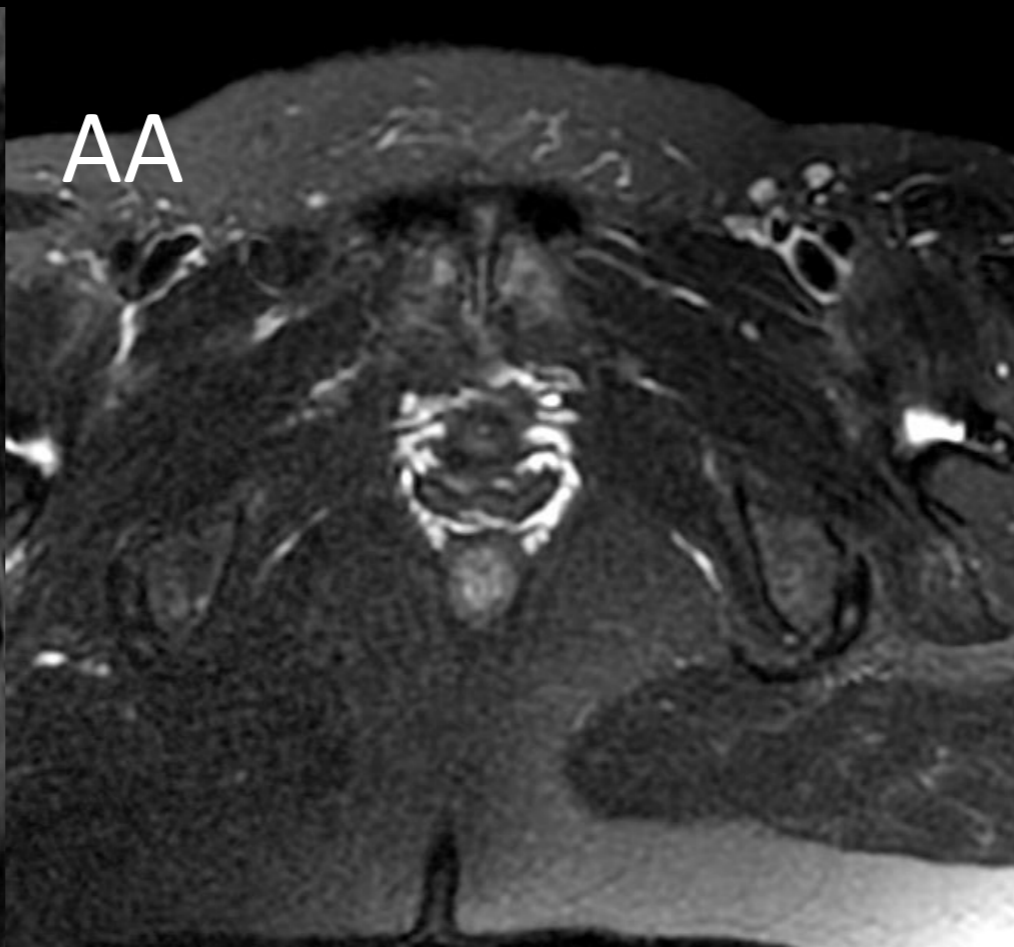
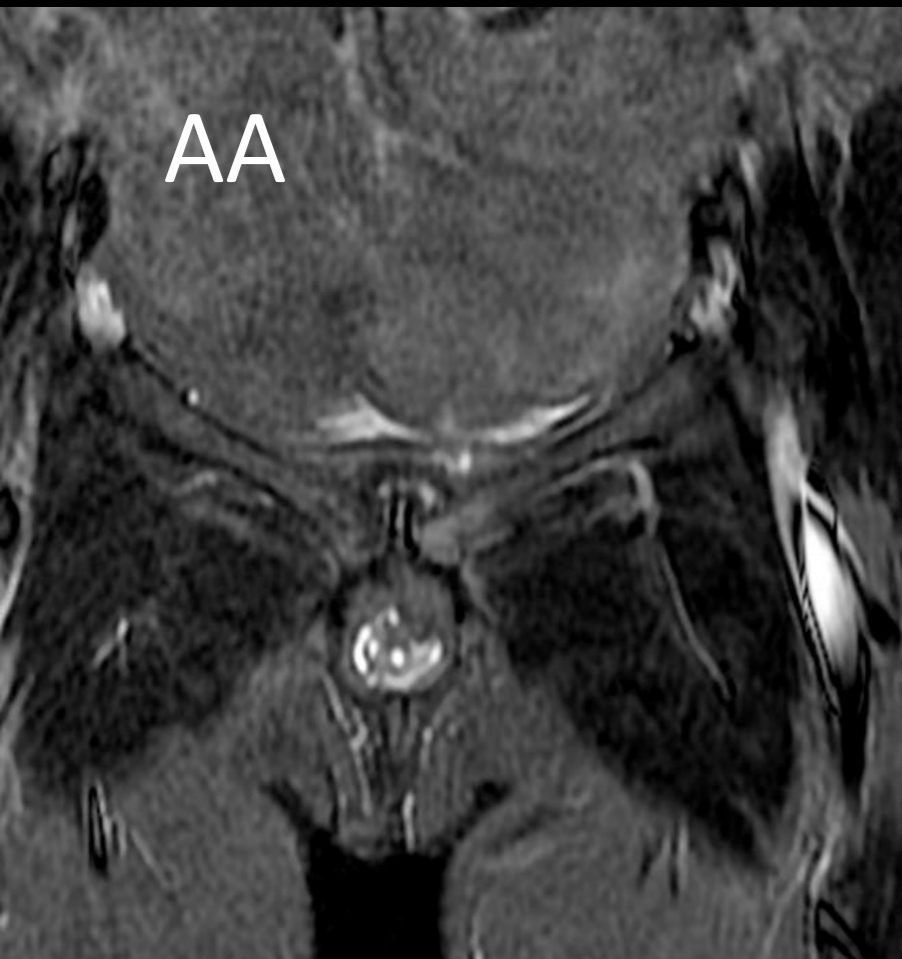Case contributor – Dr. Ankita Ahuja

MI-COD

MSS INDIA- Case Of the Day



- 65 year old female with pubic pain.



- What is your diagnosis?

Osteitis pubis with
subpubic/infrapubic
cartilaginous cyst

Findings :

- Capsulated infrapubic lesion with mixed signal intensity, accompanied by mild widening of the pubic symphysis, mild parasymphyseal marrow edema, and degenerative changes.

- Osteitis pubis is an outcome of long standing stress or wear and tear. There is cartilaginous wear and tear with joint fluid extending into the cartilaginous cyst which extends into the space of Retzius.
- These cysts can be suprapubic, retropubic or sub/infrapubic. Subpubic cyst extends posteroinferiorly at the level of vagina leading to dyspareunia or lower urinary tract symptoms or acute urinary retention. Retropubic or suprapubic cyst can have a mass effect on the urinary bladder with stress incontinence