

MICOD – 09/02/2024

Case contributor – Dr. Sonal Saran

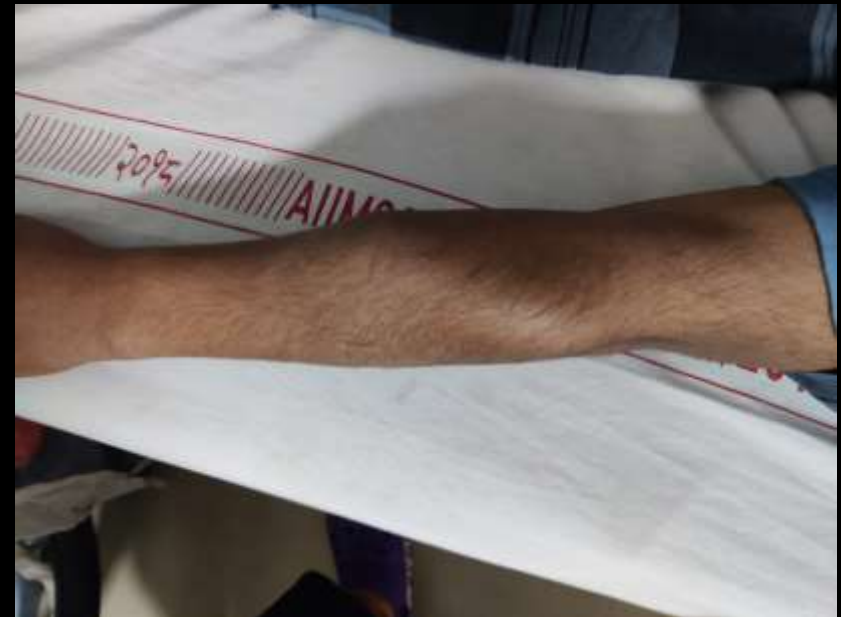# MI-COD

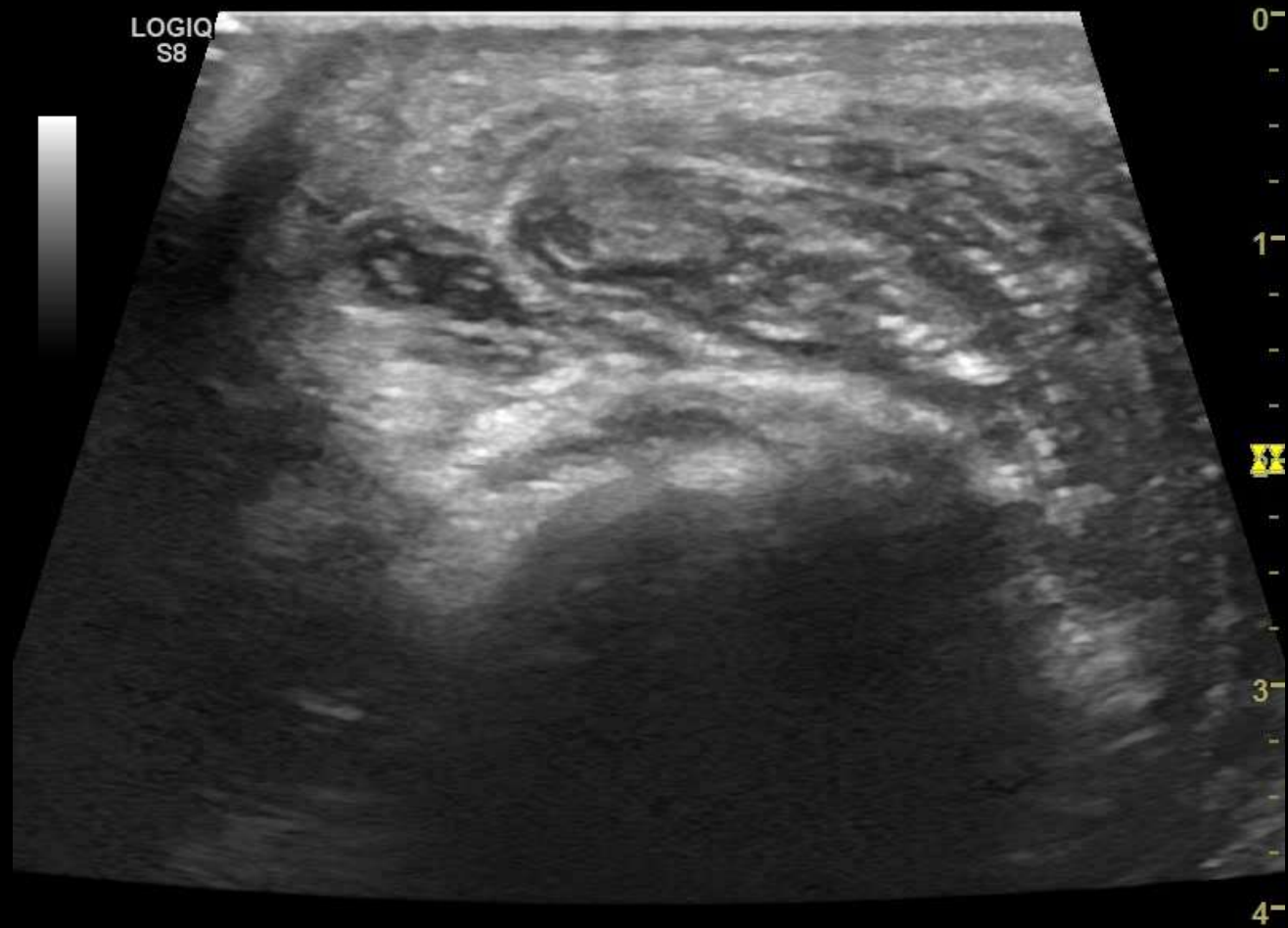
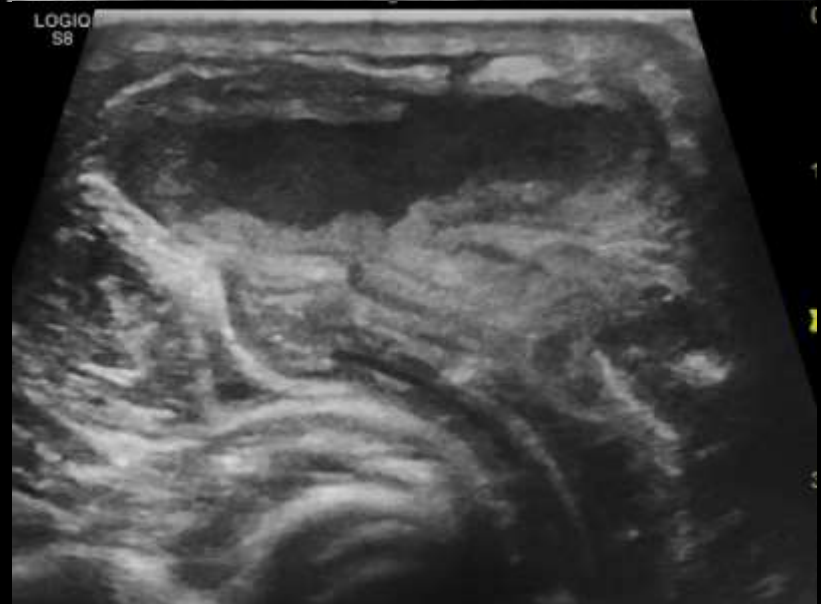
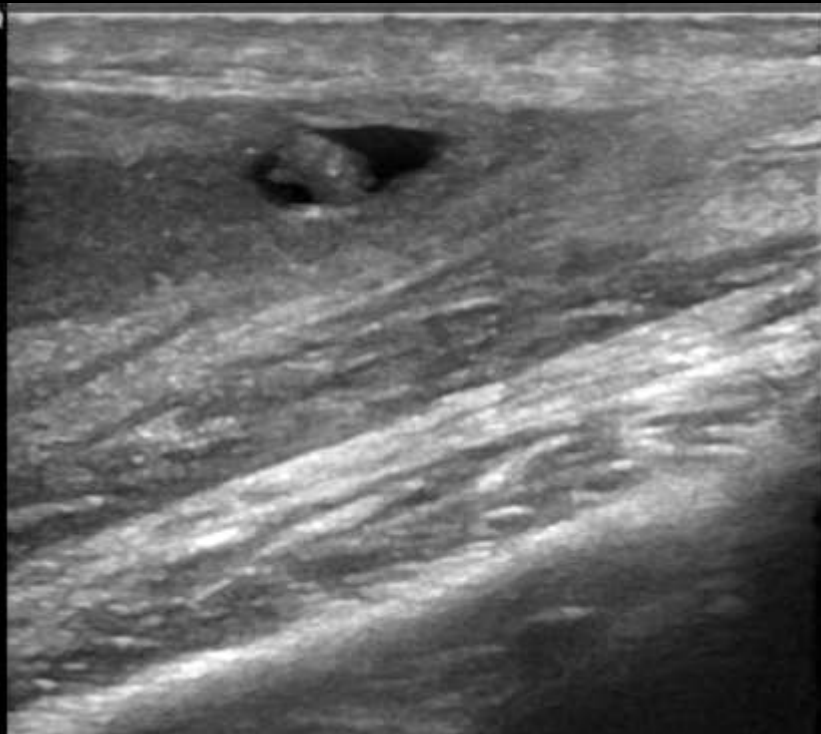
MSS INDIA- Case Of the Day



25 year old male presented with swelling in forearm

What would you do next?





Atypical presentation of a common entity

**Myocysticercosis with abscess**