

MICOD – 06/02/2024

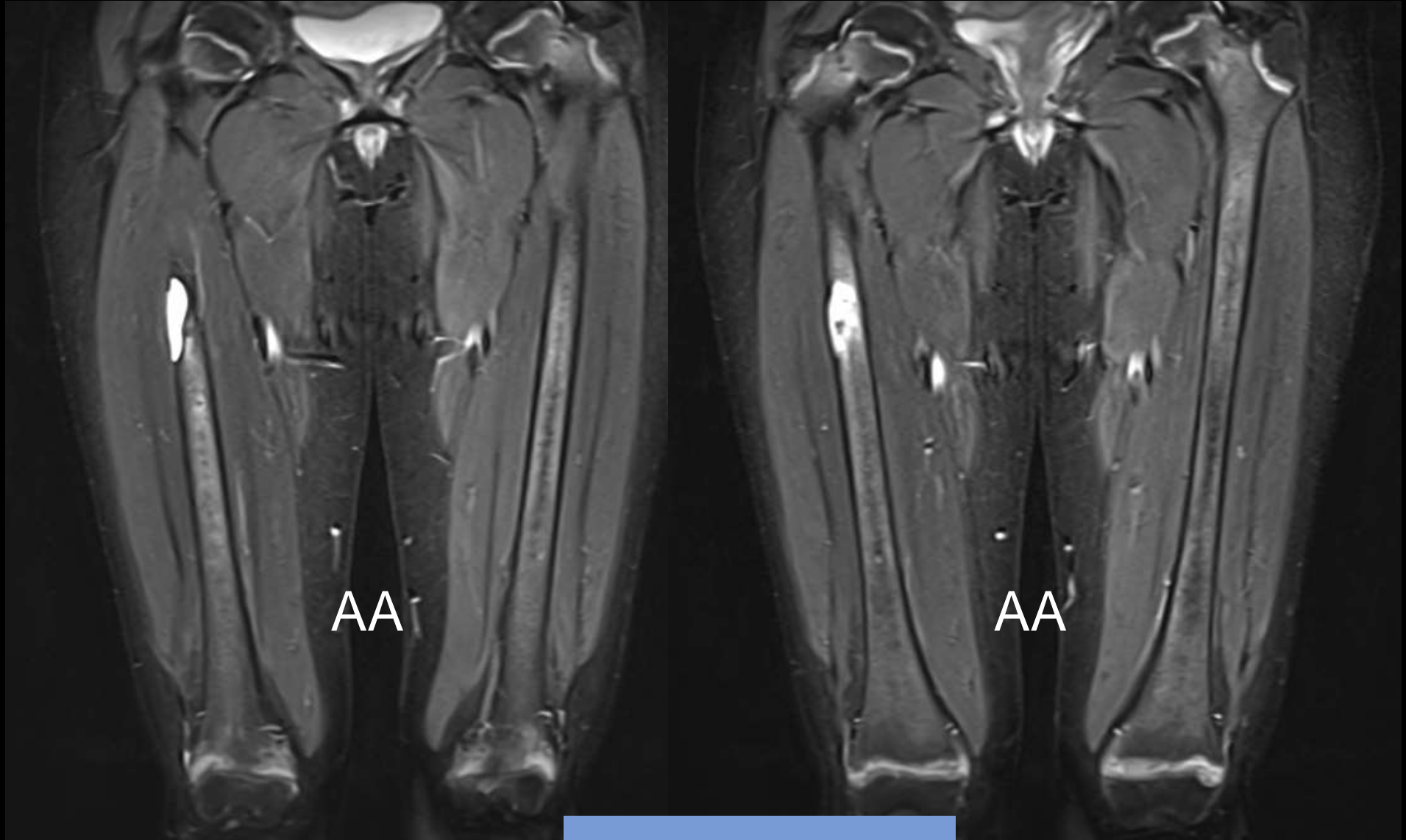
Case contributor – Dr. Ankita Ahuja

MI-COD

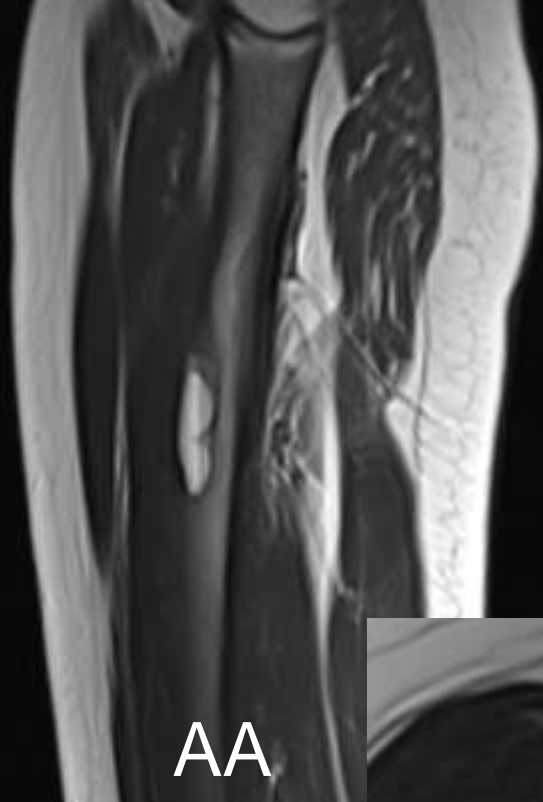
MSS INDIA- Case Of the Day



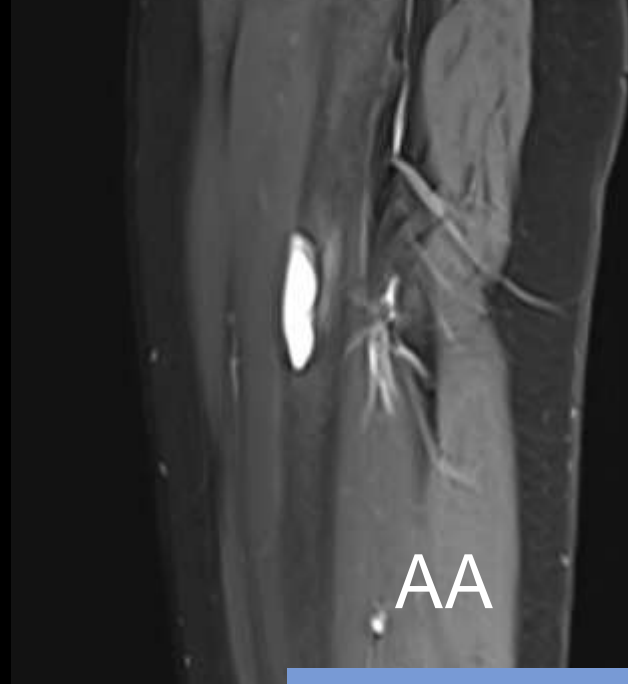
A young female with pain in right thigh.



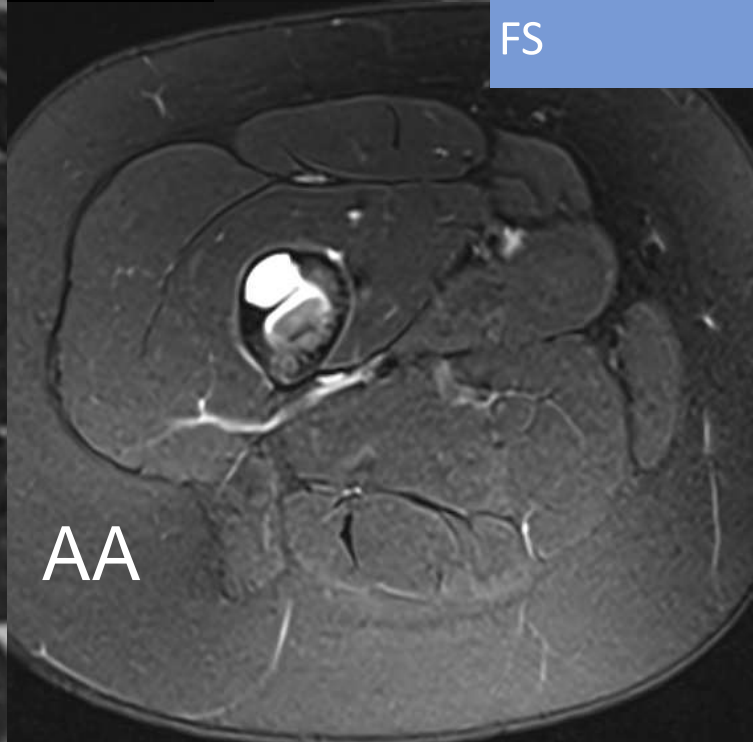
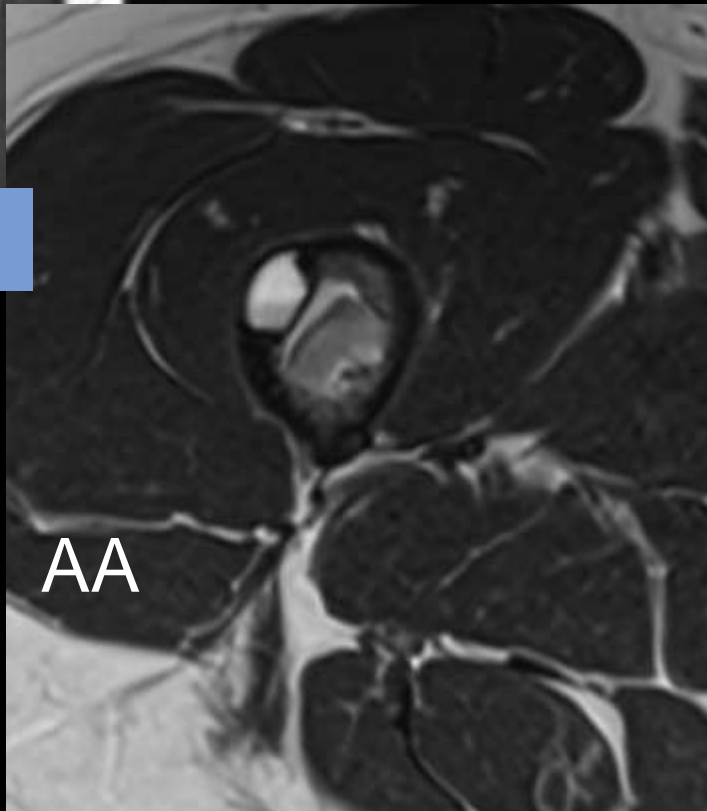
STIR Coronal

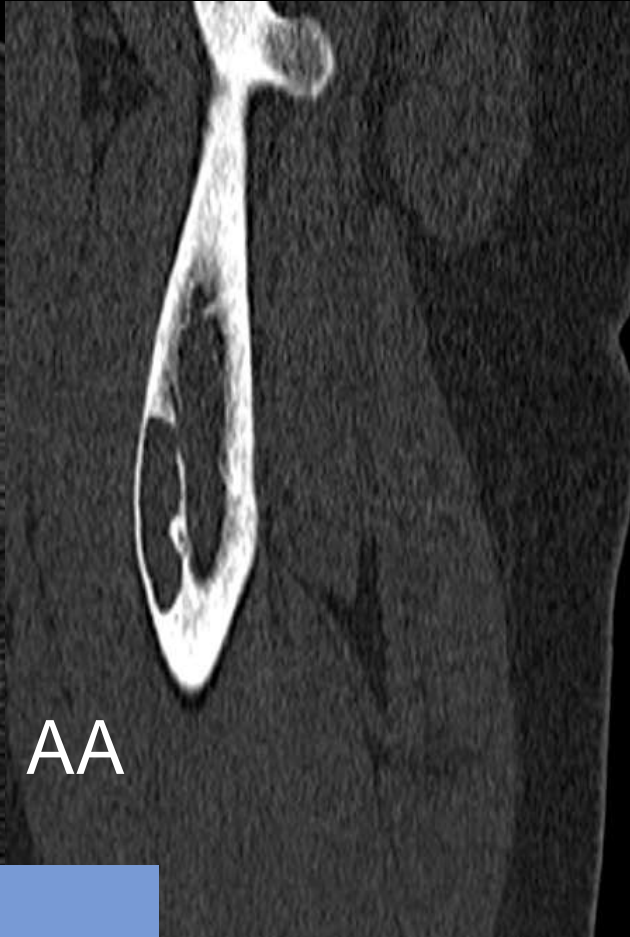
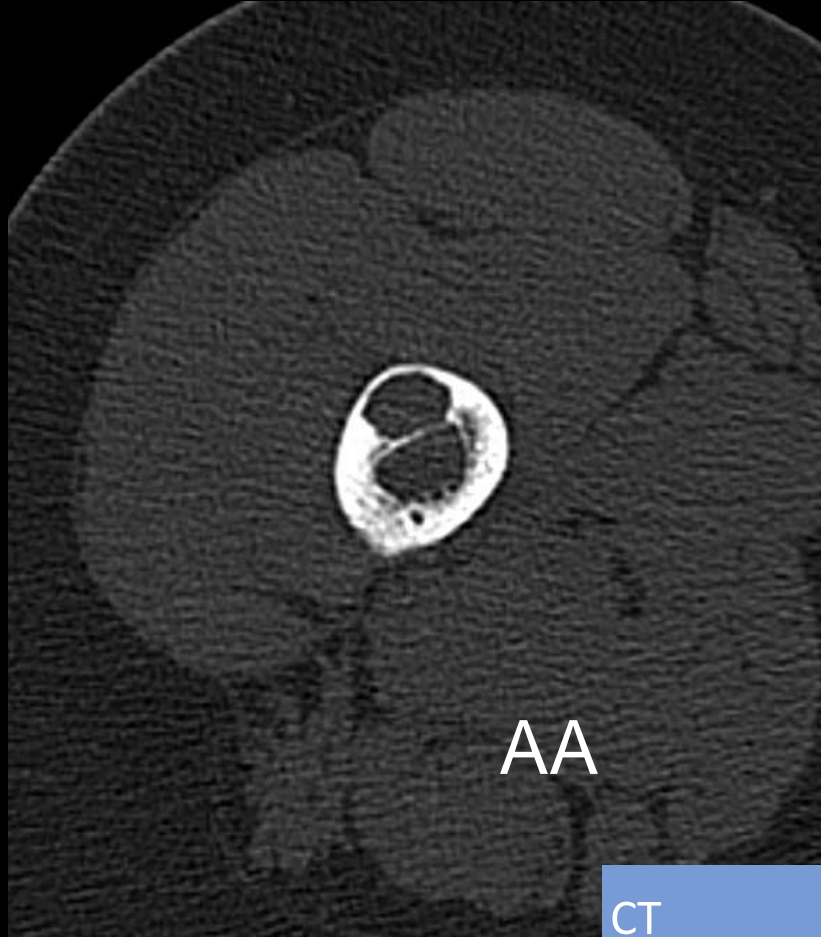


T2



FS





CT

- **What are the findings?**
- **What further investigation you would suggest?**
- **What is your diagnosis?**

Answer

- **Widening of the physis, concerning for rickets**
- **Medial neck femoral fractures.**
- **Anterior cortical lytic lesion, in this picture depicts brown's tumor.**

- **S. Parathormone level – was raised**

Rickets with Brown's tumor
(secondary
hyperparathyroidism)

Case Reports > [Eur J Pediatr.](#) 2000 Jan-Feb;159(1-2):70-3. doi: 10.1007/pl00013807.

Brown tumour as a complication of secondary hyperparathyroidism in severe long-lasting vitamin D deficiency rickets

A Bereket ¹, Y Casur, P Firat, N Yordam

Affiliations + expand

PMID: 10653333 DOI: [10.1007/pl00013807](#)

[Brown Tumor as an Index Presentation of Severe Vitamin D Deficiency in a Teenage Girl.](#)

Goyal A, Boro H, Khadgawat R.

[Cureus.](#) 2018 May 31;10(5):e2722. doi: 10.7759/cureus.2722.

PMID: 30079288 [Free PMC article.](#)