

MICOD – 035/02/2024

Case contributor – Dr. Mahesh Kumar Verma

# MI-COD

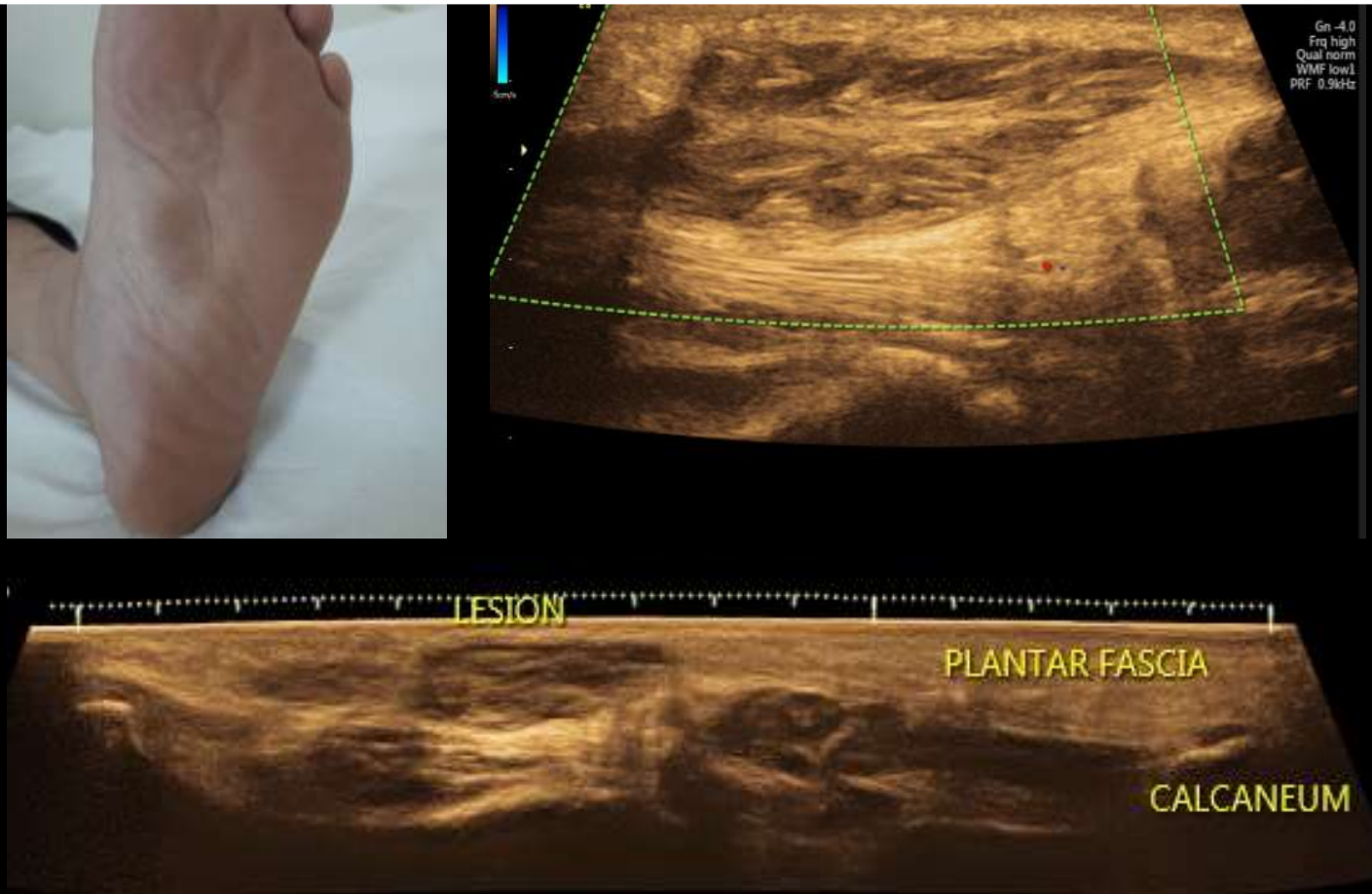
MSS INDIA- Case Of the Day

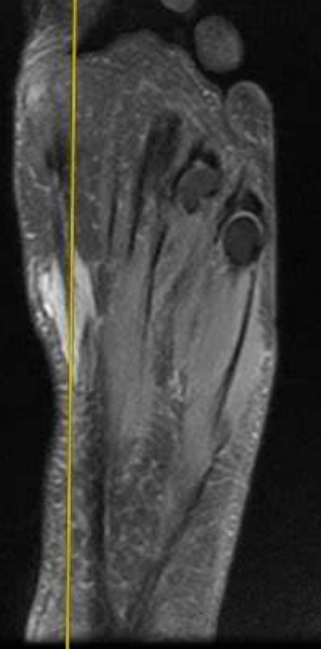
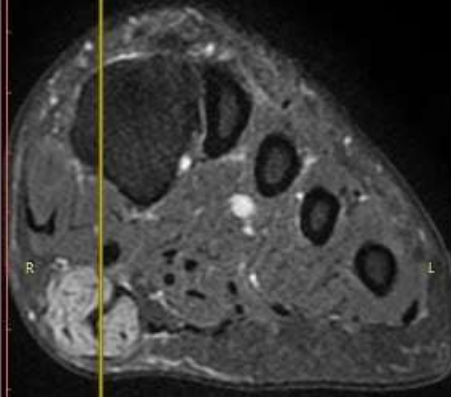
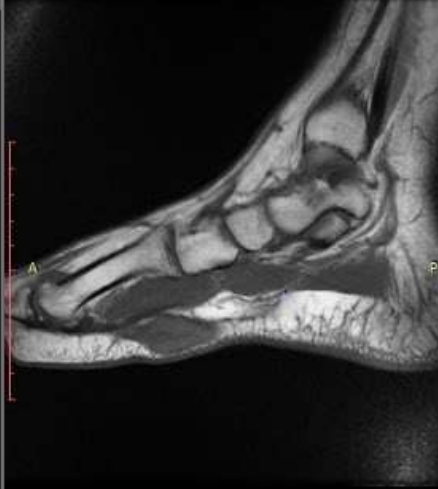
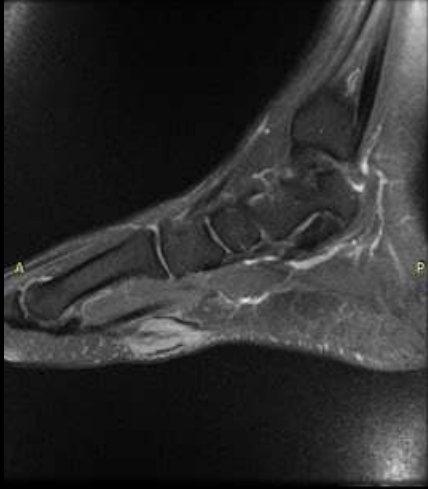
Patient presented with slowly progressive lump over plantar aspect of foot.

USG reveals : Discrete fusiform hypoechoic nodular lesion with in the medial bands of the plantar fascia without internal vascularity on colour doppler imaging.

Diagnosis ?





## Plantar fibroma

Benign fibroblastic proliferation of the plantar fascia .

Multiple plantar fibromas known as fibromatosis or Ledderhose disease.