

MICOD – 01/02/2024

Case contributor – Dr. Rohit Sharma

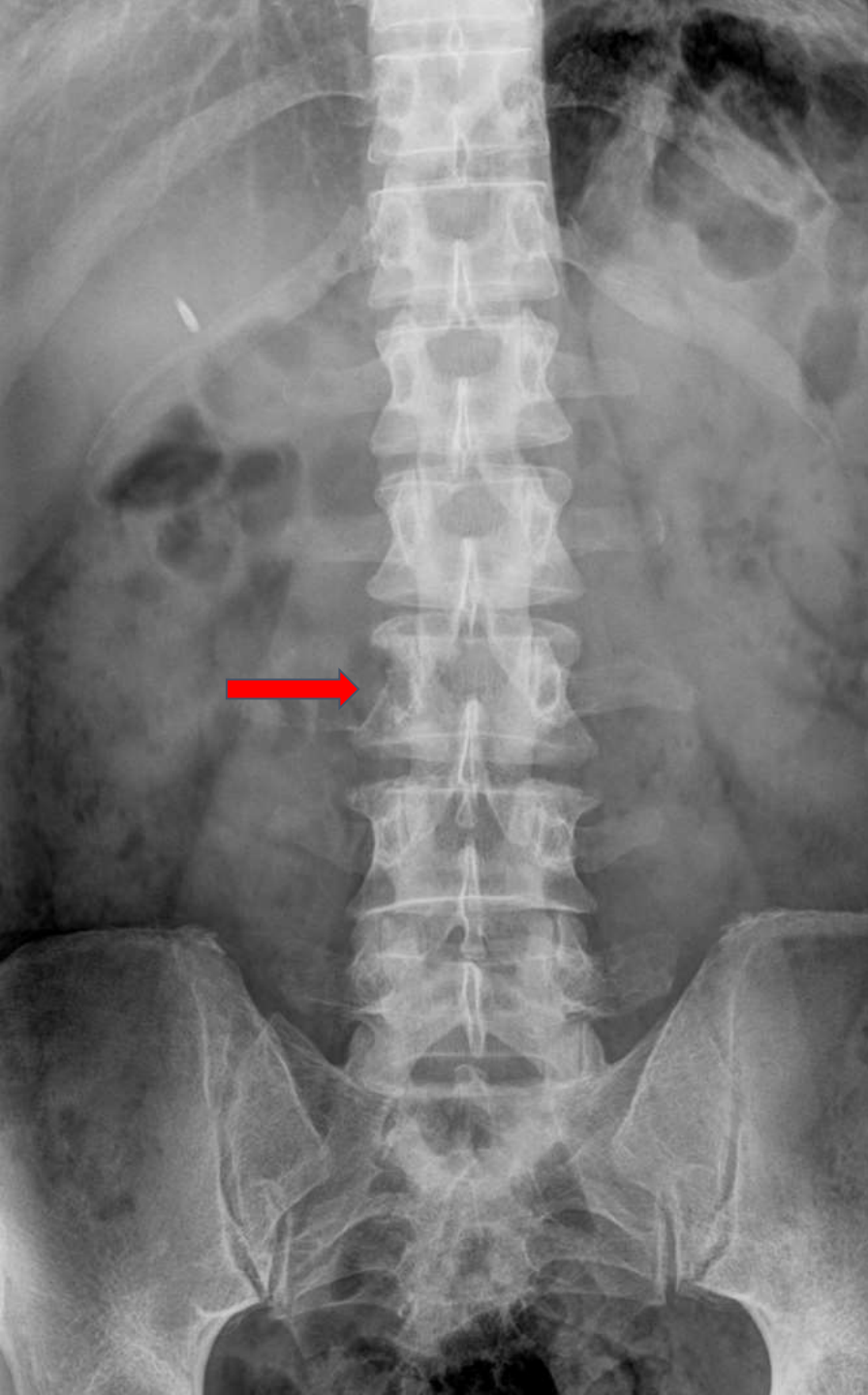
# MI-COD

MSS INDIA- Case Of the Day

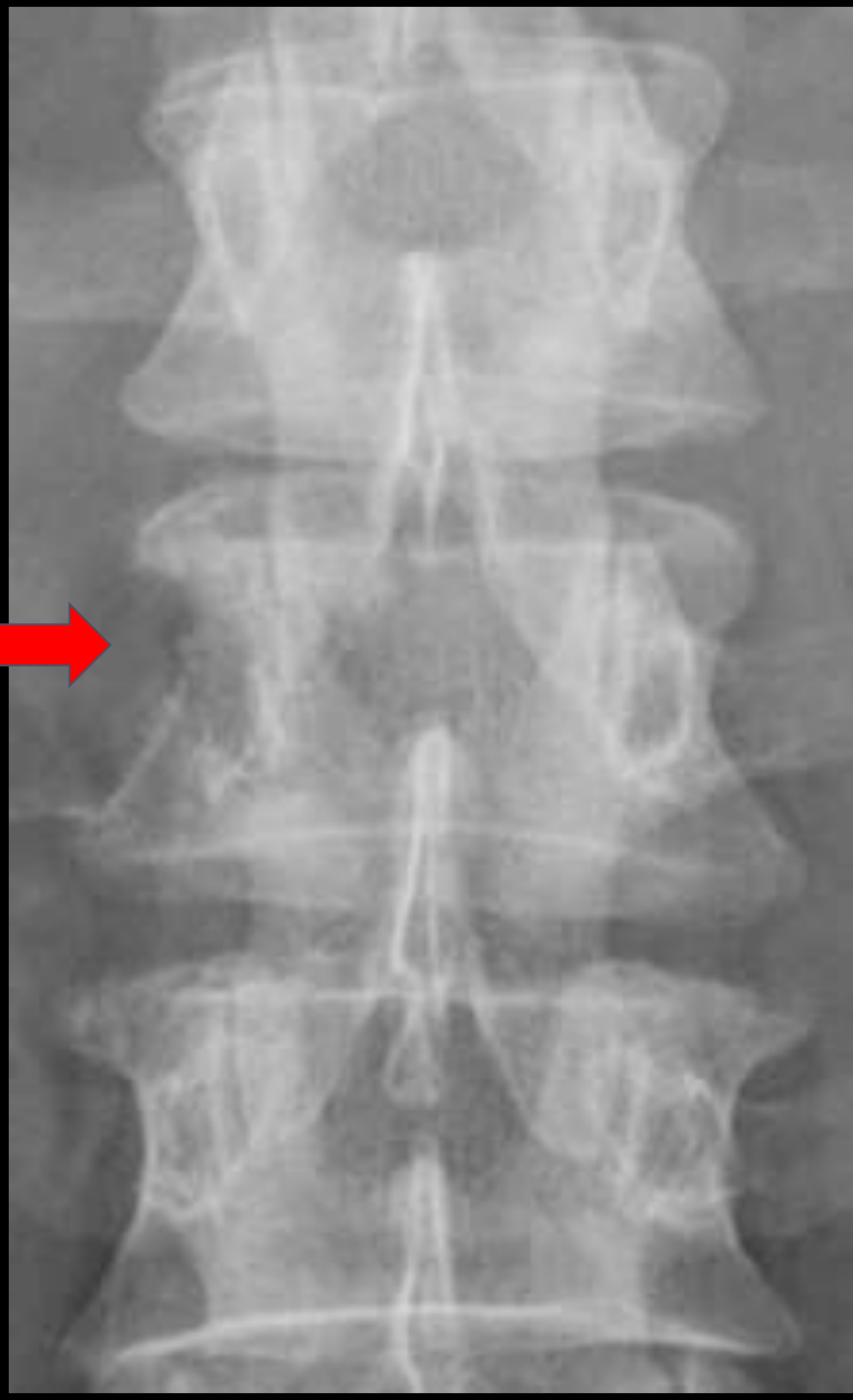

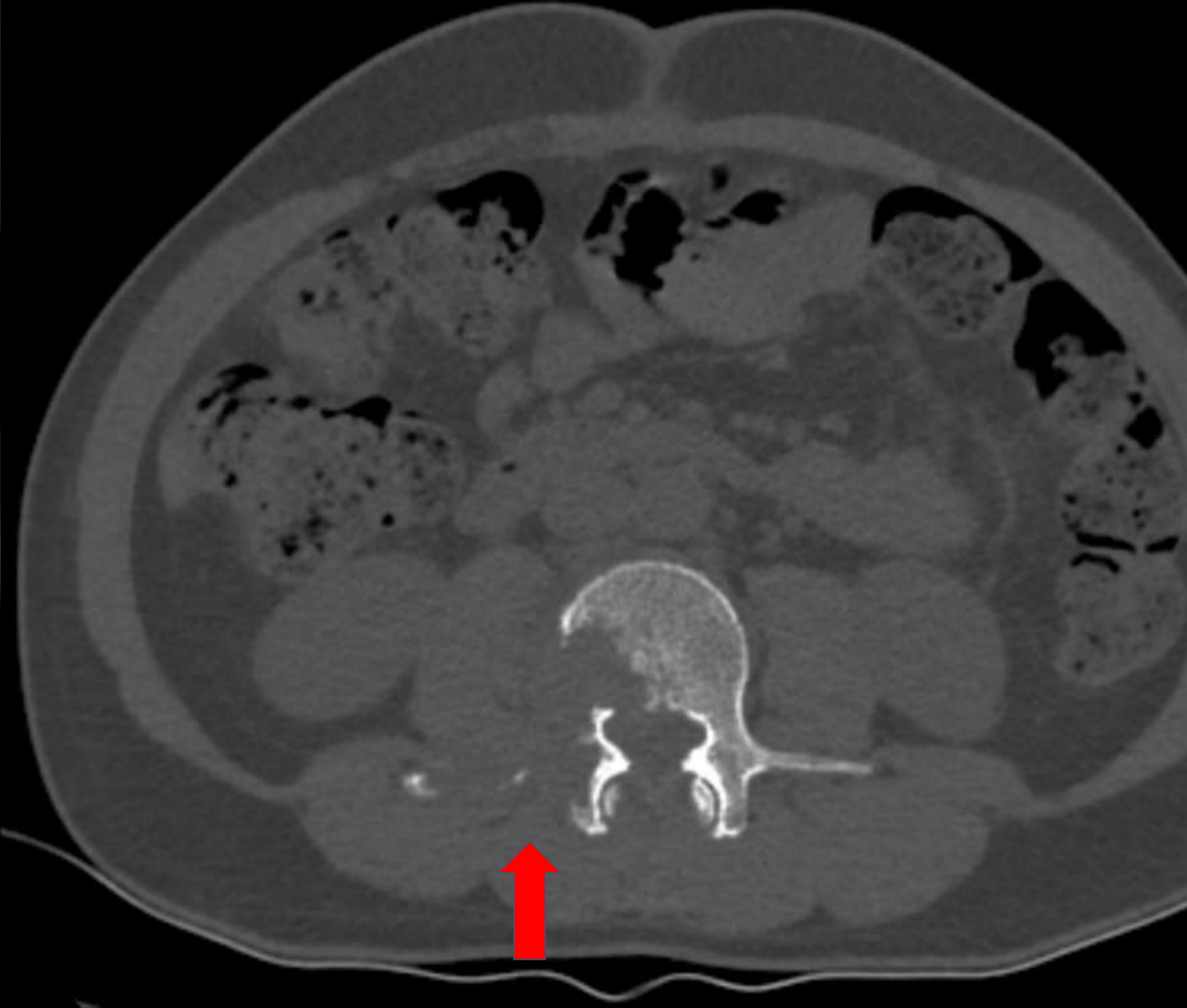
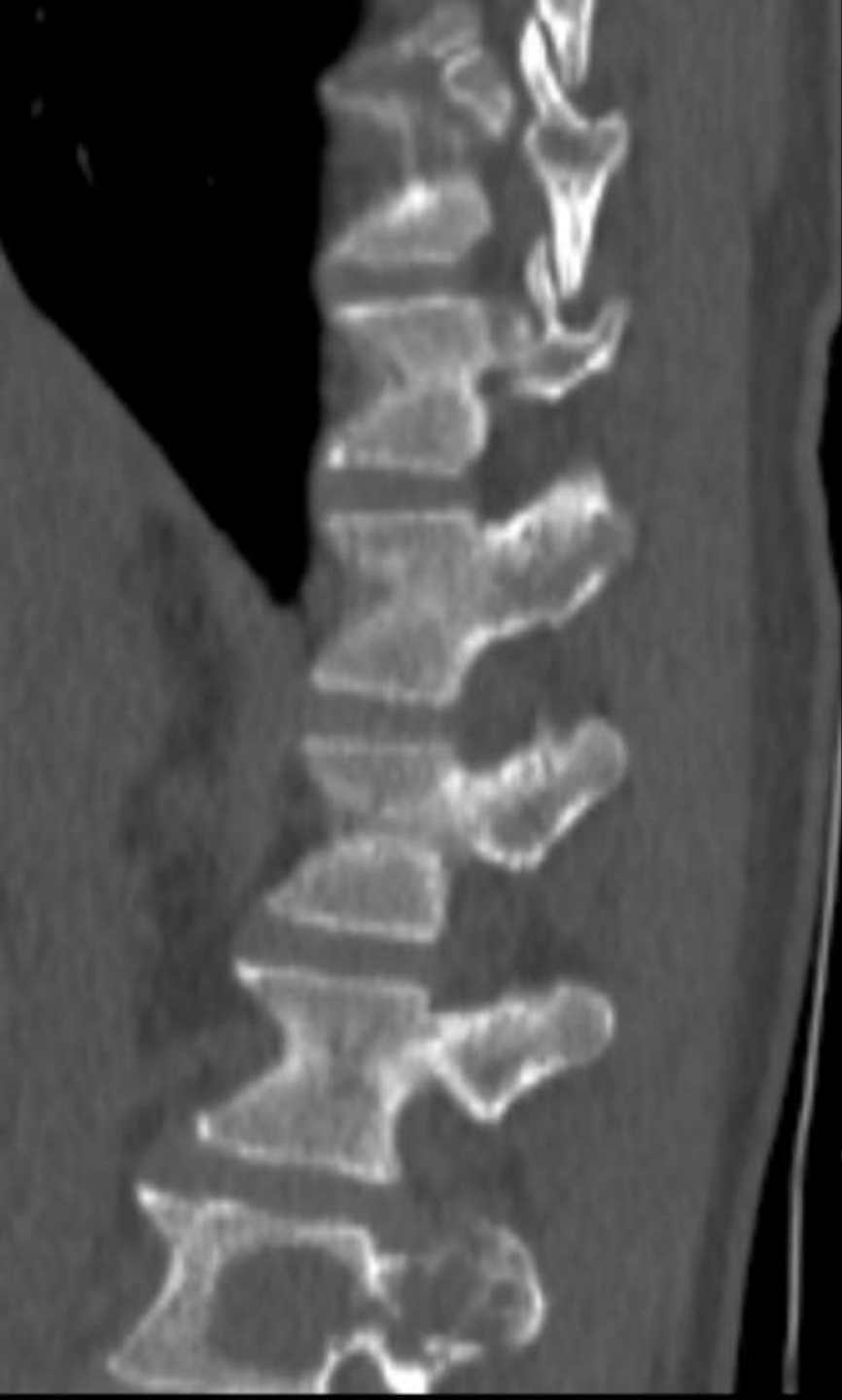# HISTORY

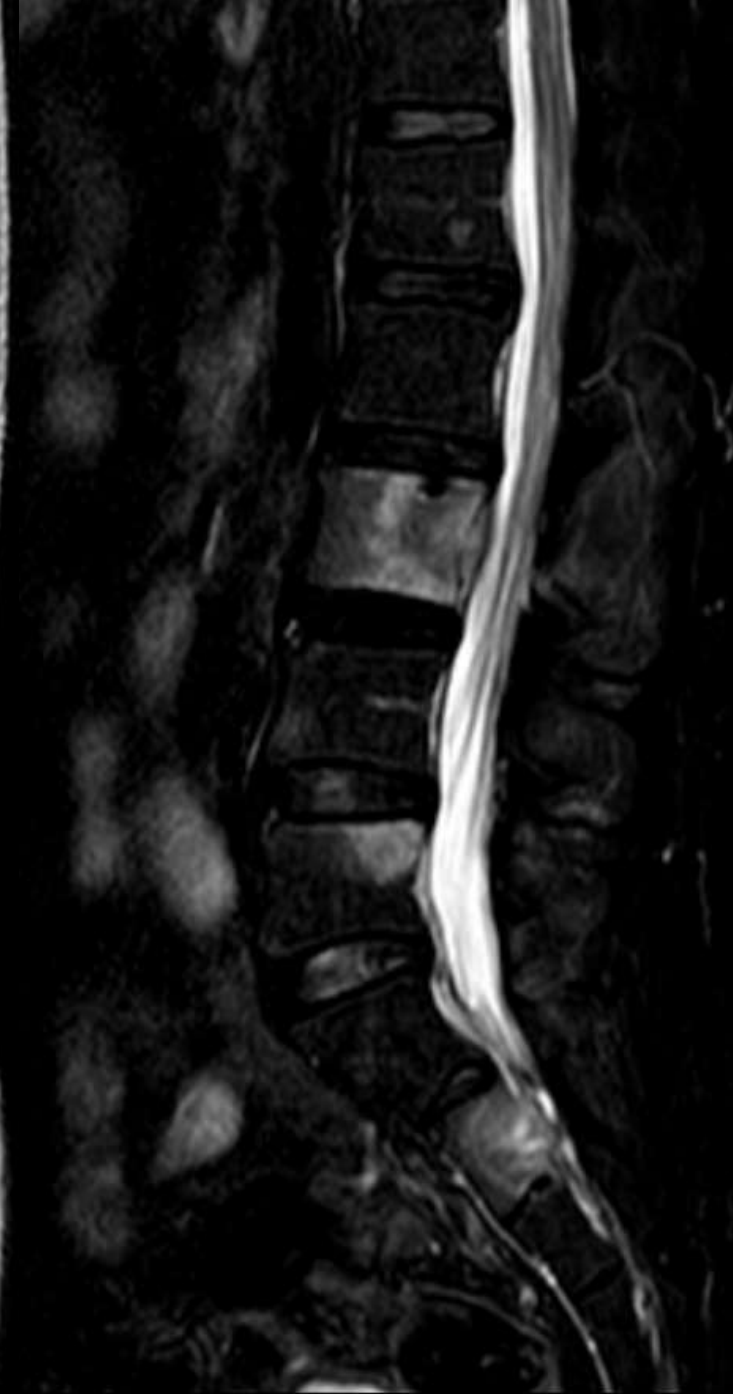
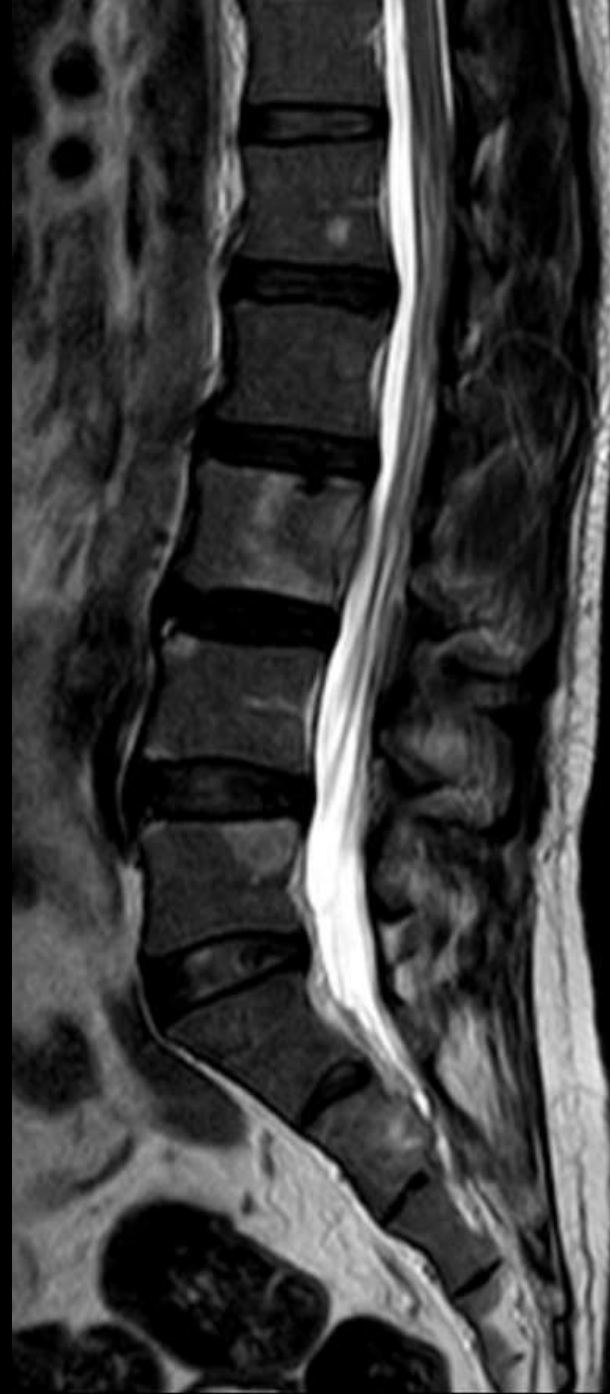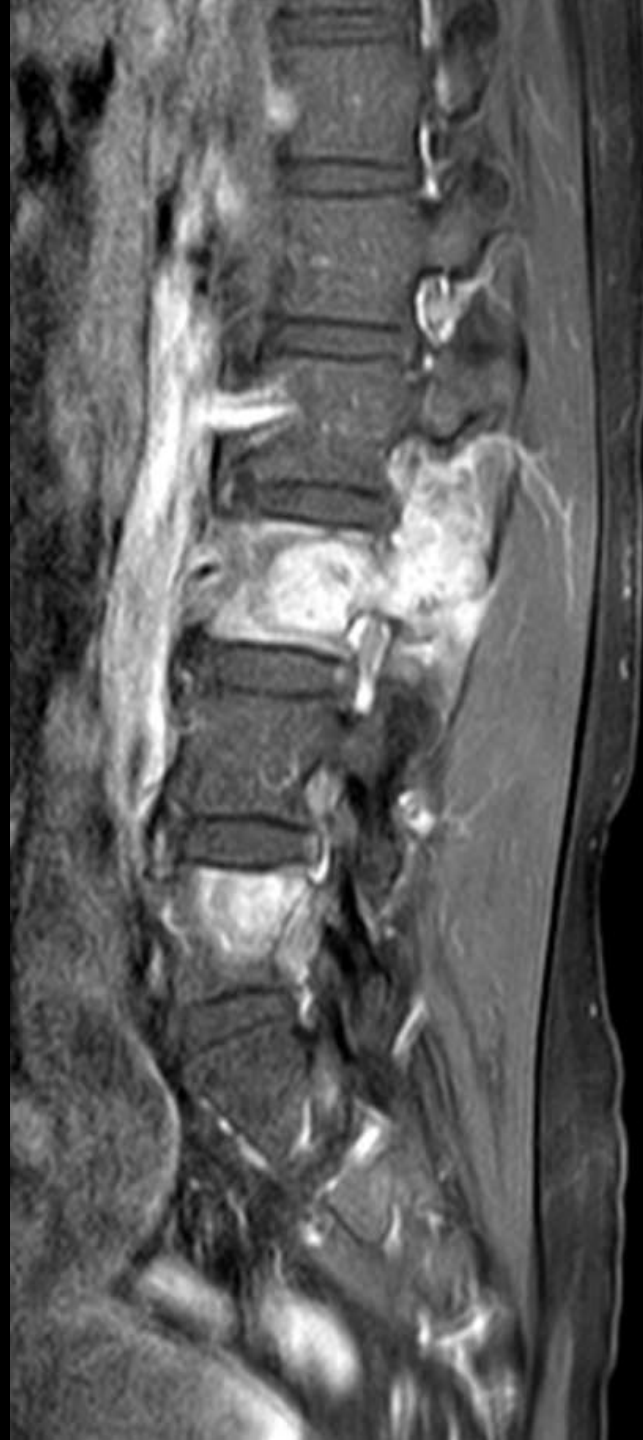60 YEAR OLD MALE WITH LOW BACKACHE

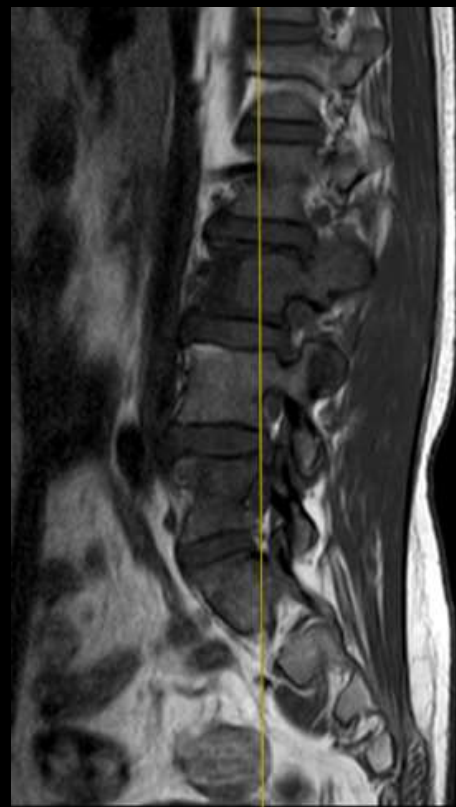

Absent Pedicle/Winking owl sign L3



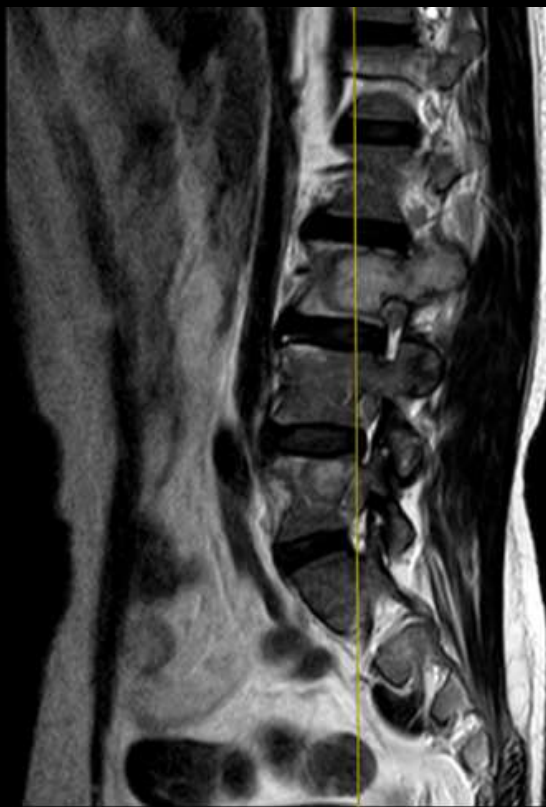





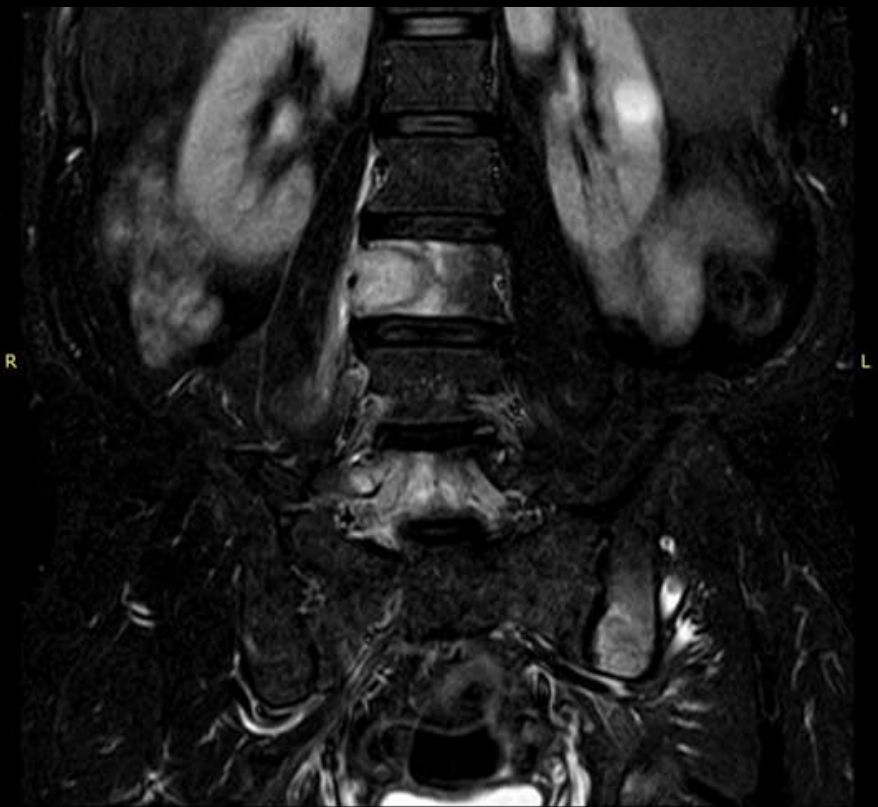
P

A



P

R



L

# Diagnosis

Vertebral metastases.