

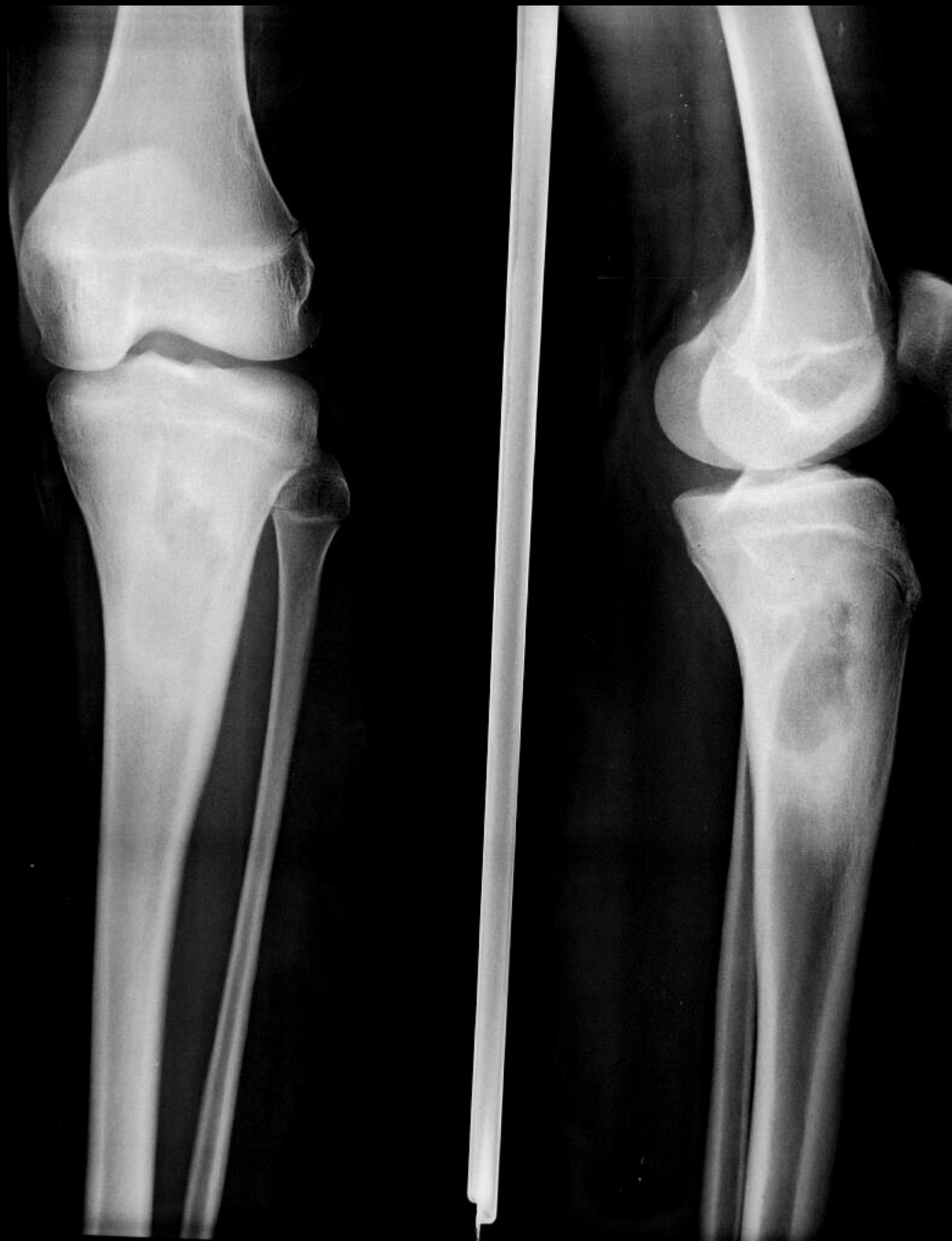
**MICOD - 31/01/2024**

**Case contributor – Dr. Vijinder Arora**

# MI-COD

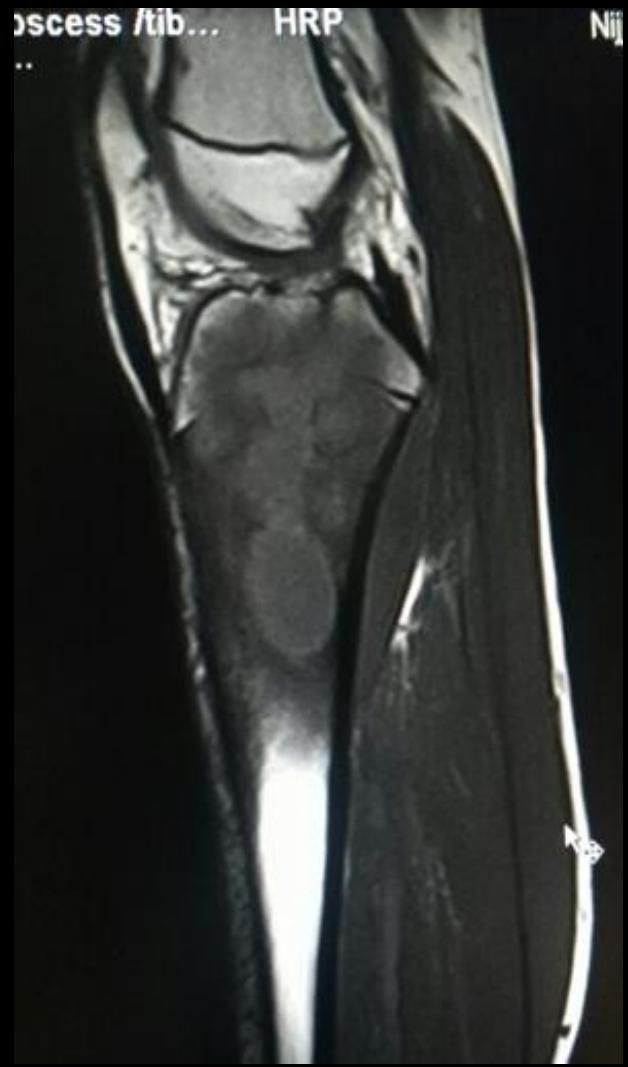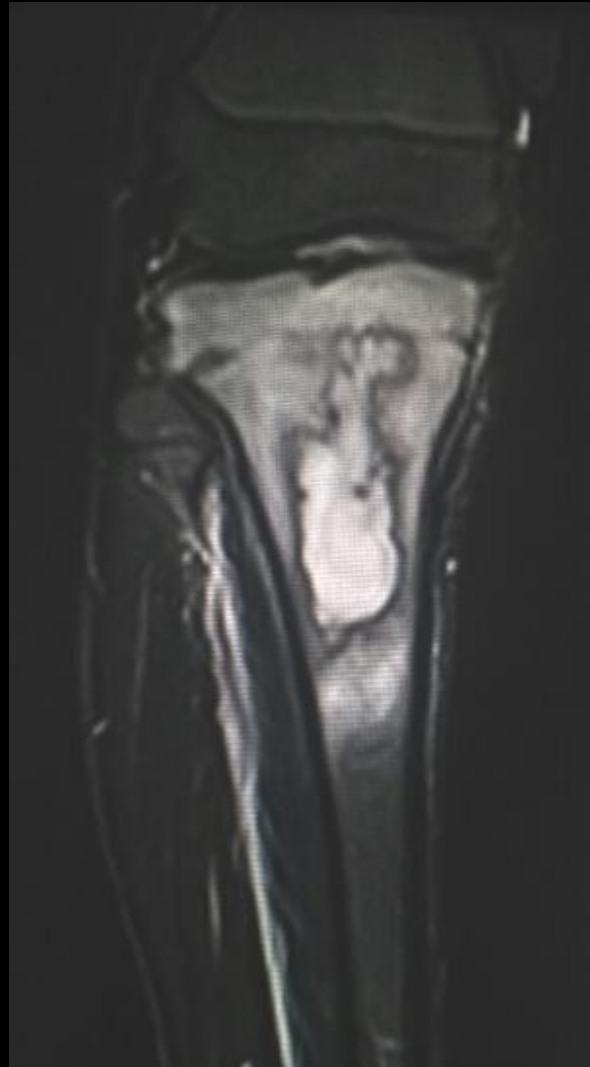MSS INDIA- Case Of the Day





CASE 5  
17 yrs old boy  
with h/o pain in  
leg for last two  
months

# BRODIE'S ABSCESS



# BRODIE'S ABSCESS

- Intraosseous abscess related to focus of subacute pyogenic osteomyelitis.
- Predilection for metaphysis of tubular bones, rarely traversing the open growth plate/ epiphysis (in children and infants).
- difficult to diagnose because characteristic signs and symptoms of the acute form of the disease are minimal and non-specific.

On X-ray - lytic lesion surrounded by thick dense rim of reactive sclerosis that fades imperceptibly into surrounding bone.

-lucent tortuous channel extending toward growth plate prior to physeal closure

-The “penumbra sign” on MRI is useful for discriminating subacute osteomyelitis from other bone lesions.

The penumbra sign is a rim lining of an abscess cavity with higher SI than that of the main abscess on T1w images