

MICOD - 29/01/2024

**Case contributor – Dr. Harun Gupta
(@mskteachingroom)**

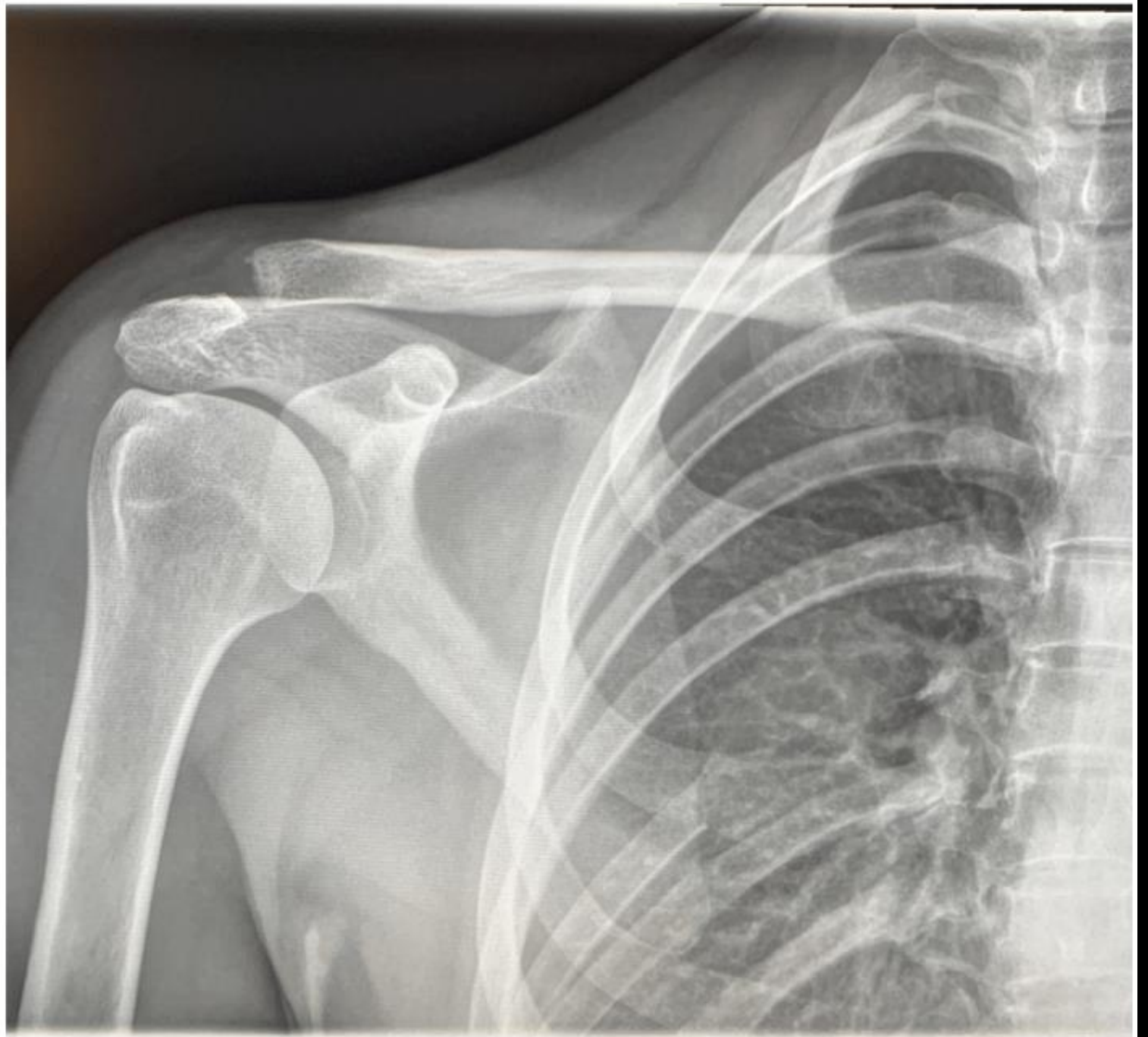
MI-COD

MSS INDIA- Case Of the Day



35 yr M

Skiing Injury



Answer

Rt posterior 7th rib lesion -
Osteosarcoma

Rt ACJ injury with post
traumatic osteolysis
changes lateral end
clavicle

Note -
Satisfaction of search

