

MICOD - 24/01/2024

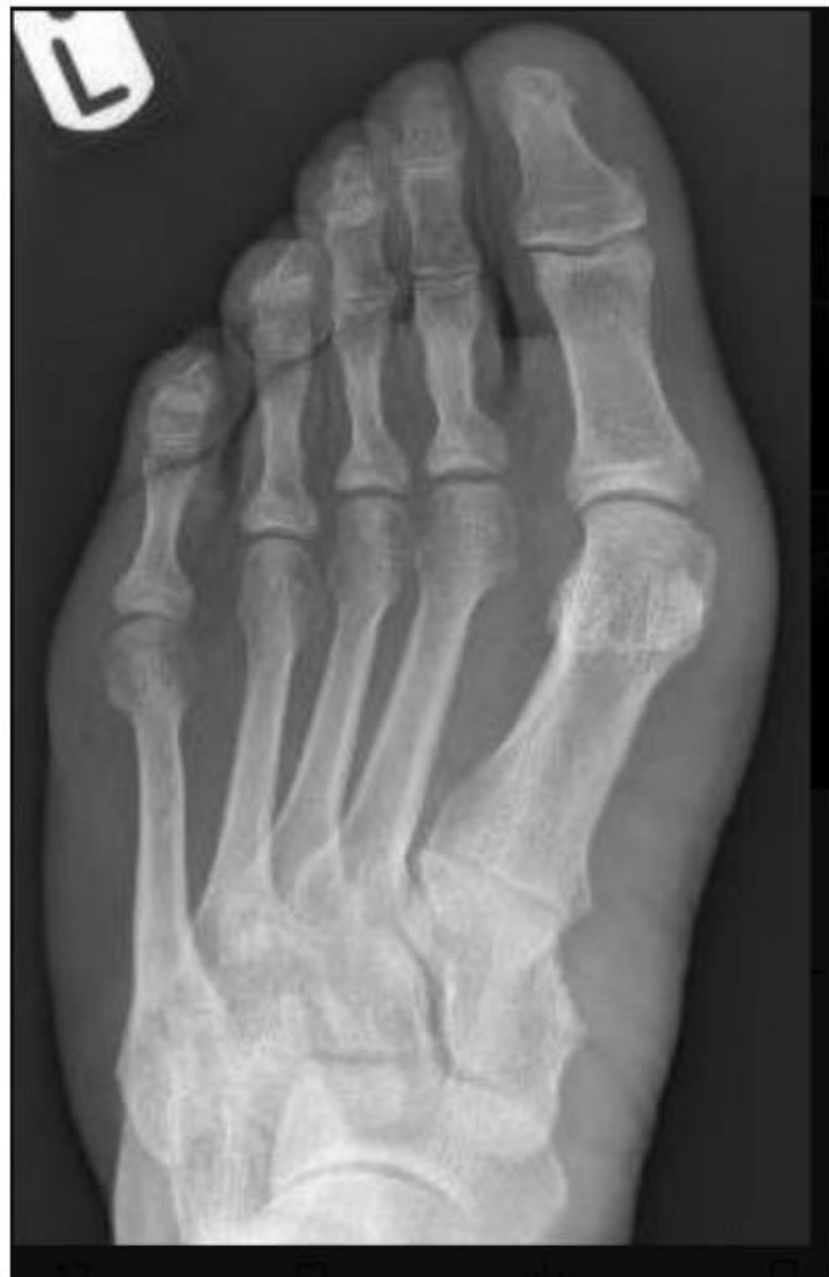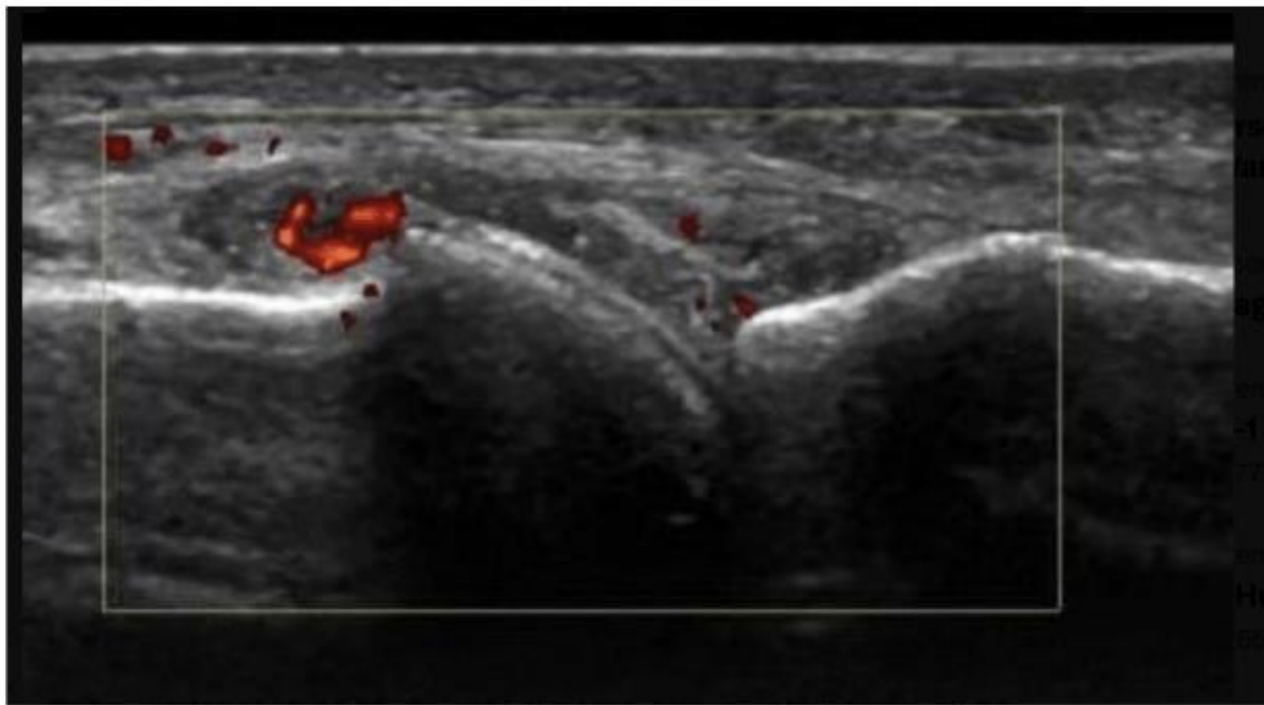
**Case contributor – Dr. Harun Gupta (MSK
Teaching Room)**

MI-COD

MSS INDIA- Case Of the Day



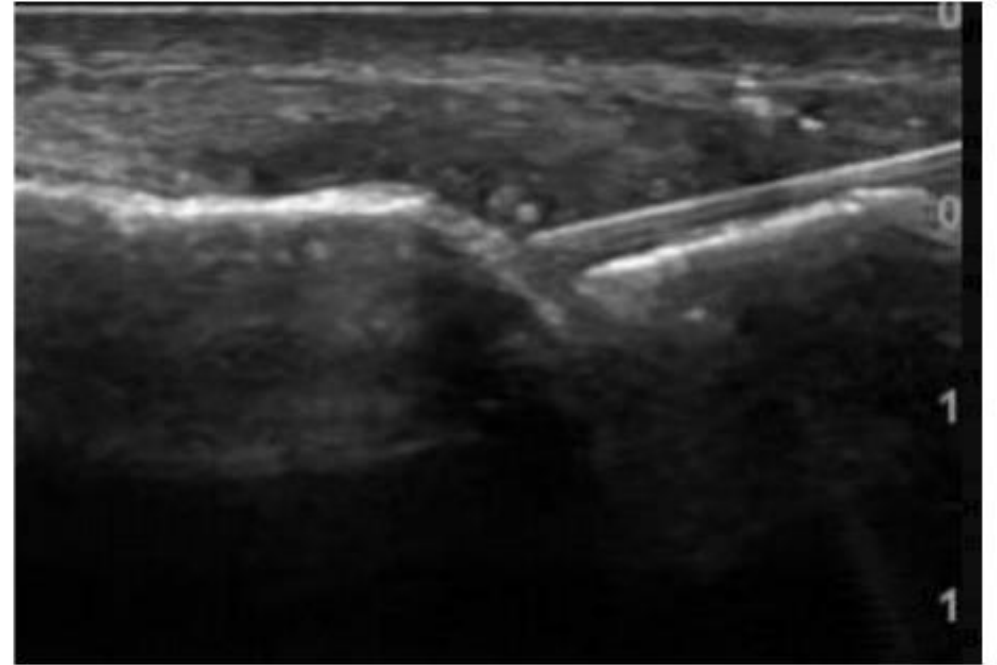
55 yr M great toe pain



Answer – Gout great toe MTPJ

X ray: Soft tissue swelling Great toe MTPJ

Ultrasound: Typical hyperechoic band over articular cartilage, echogenic synovitis in joint “snow storm” appearances



• Aspirated / injected

Gouty times !

