

MICOD – 23/01/2024

Case contributor – Dr. Chinmay P. Mehta

# MI-COD

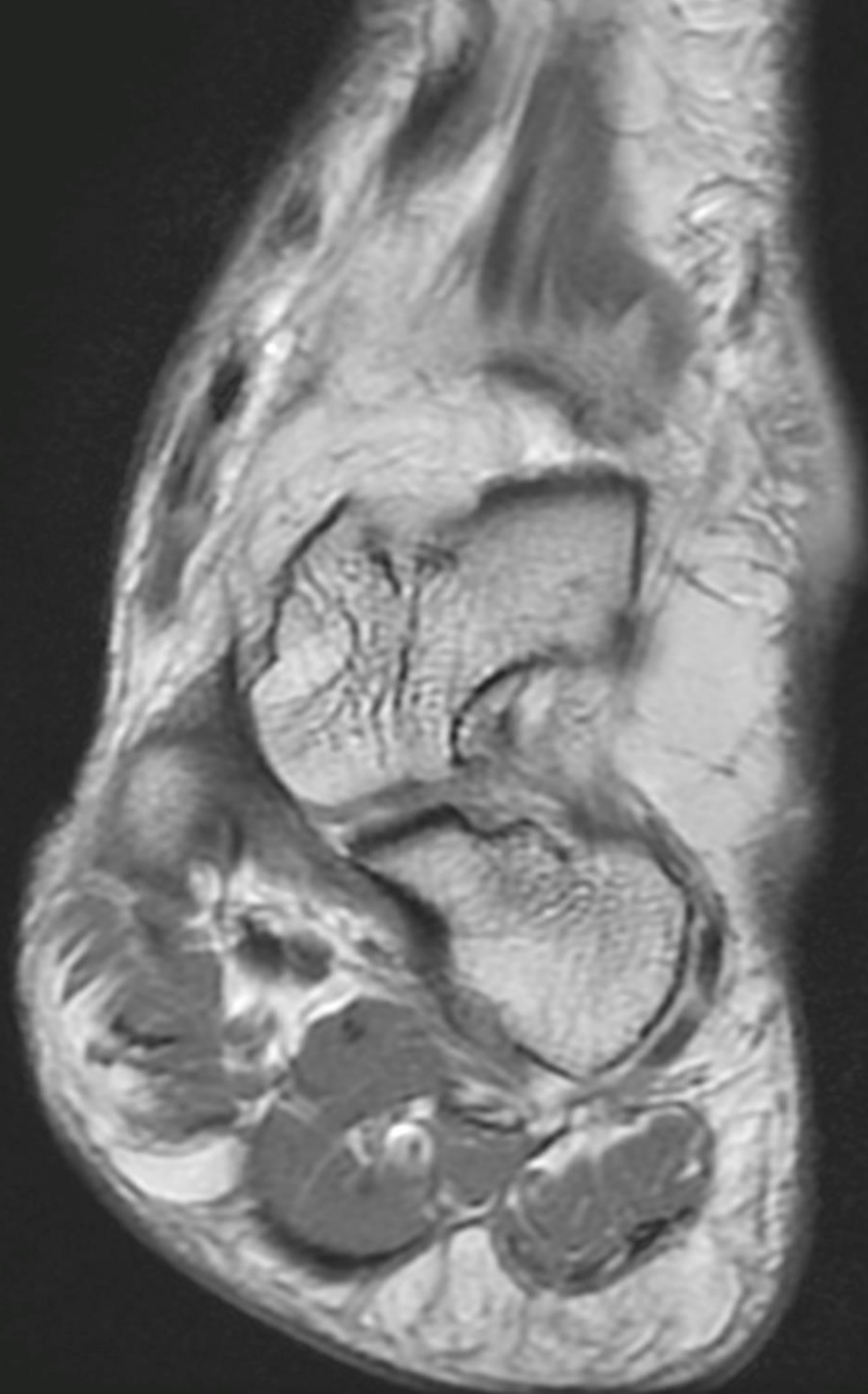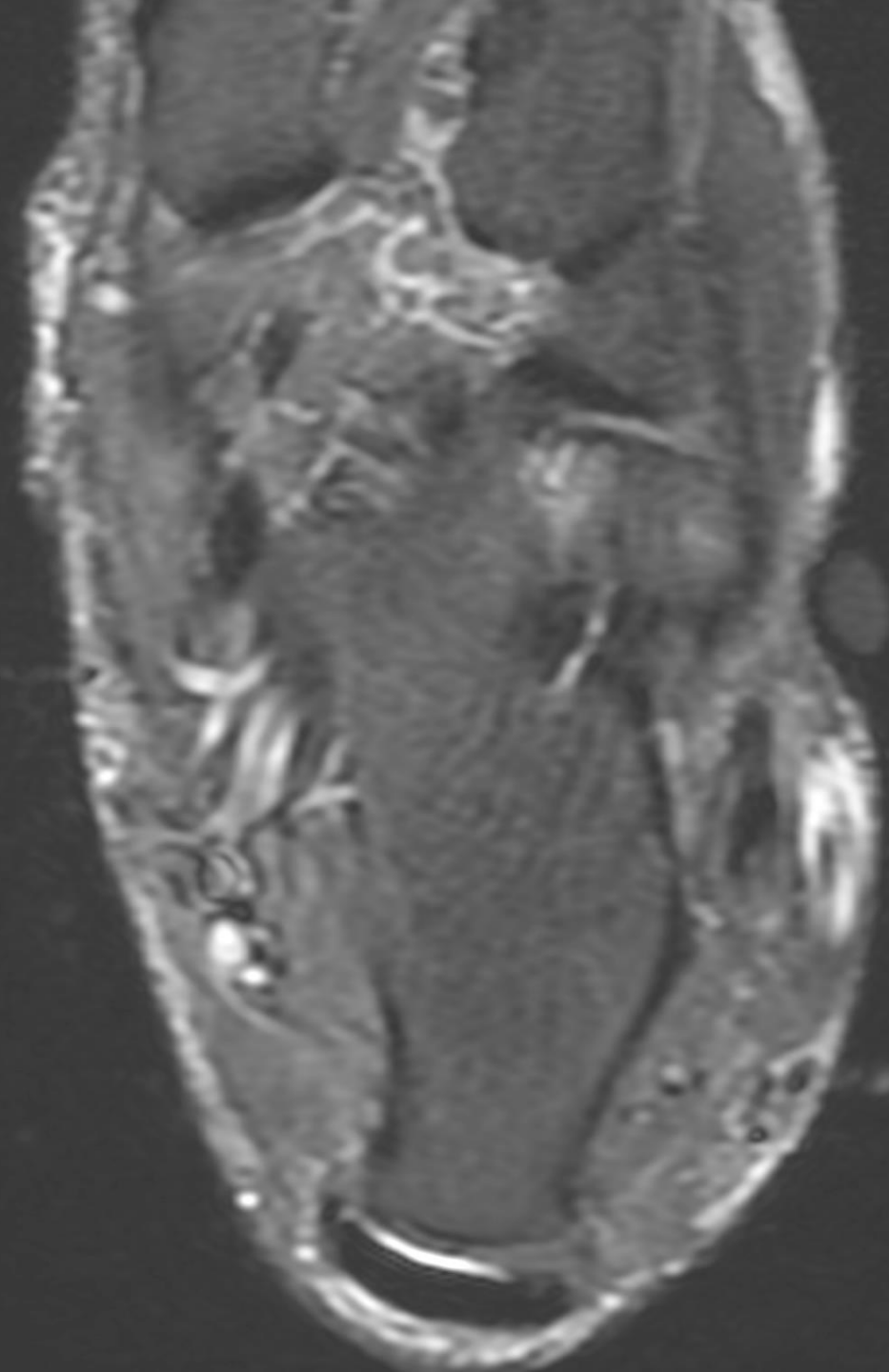
MSS INDIA- Case Of the Day

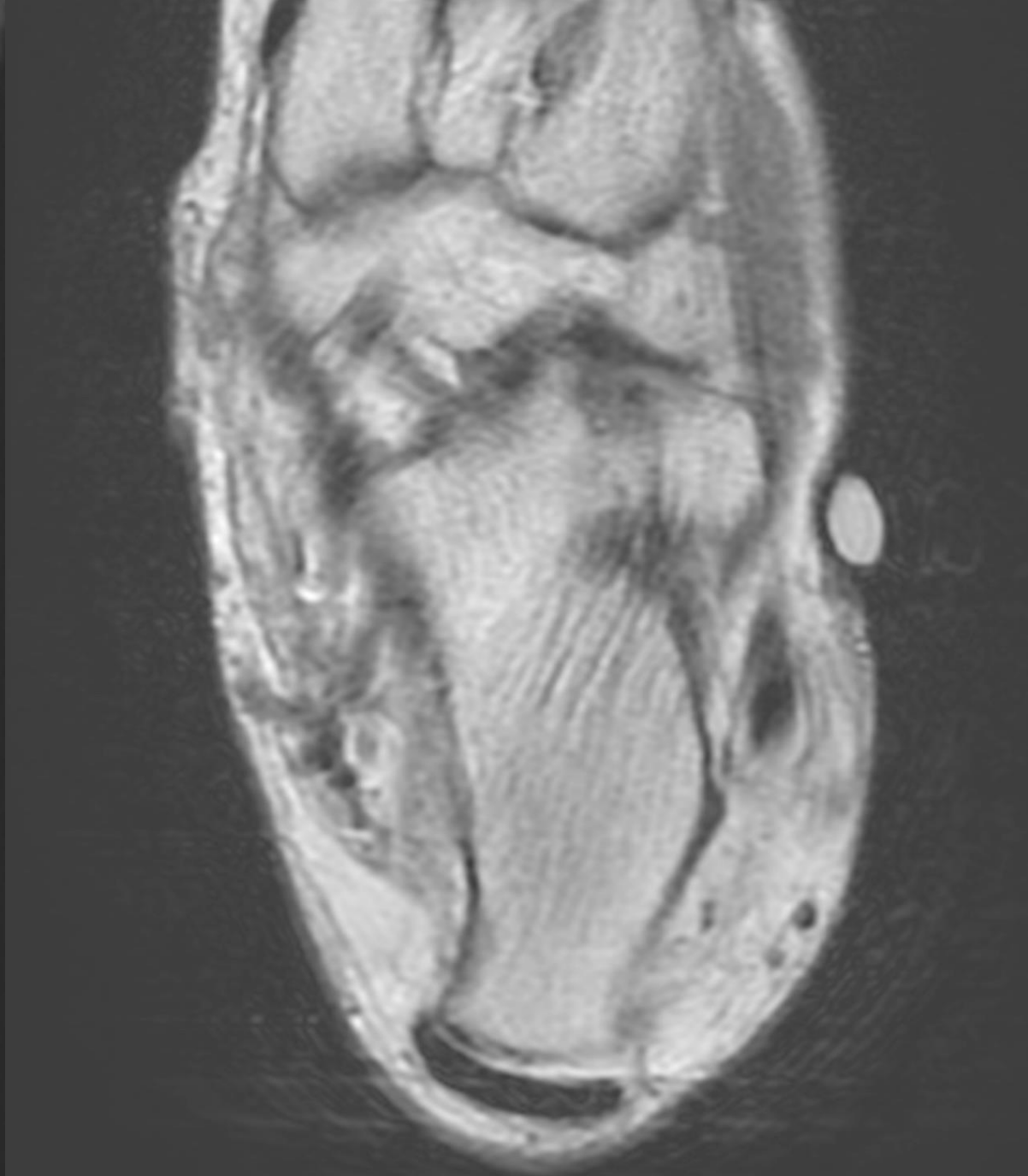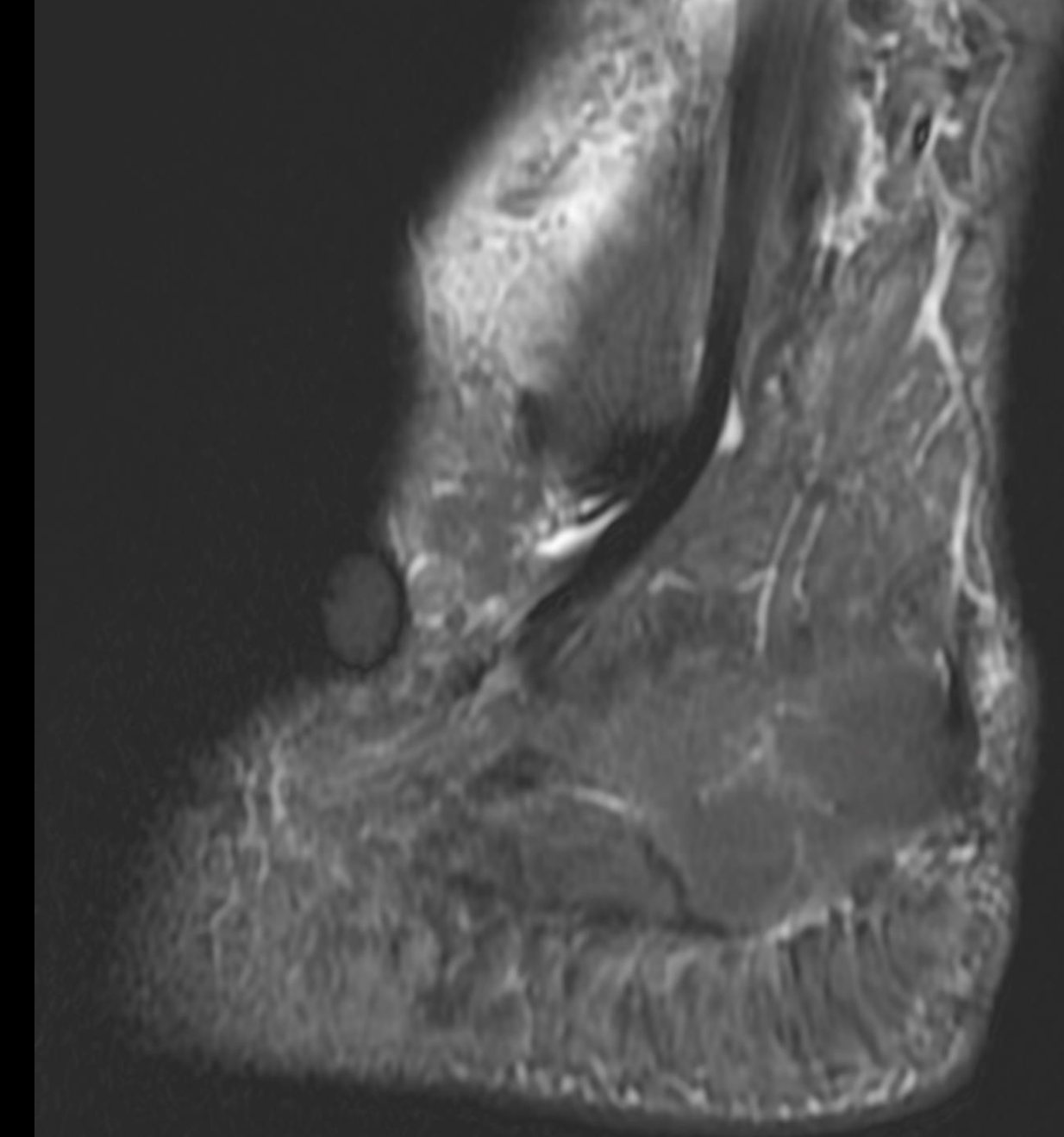


# CATCH ME IF YOU CAN!!

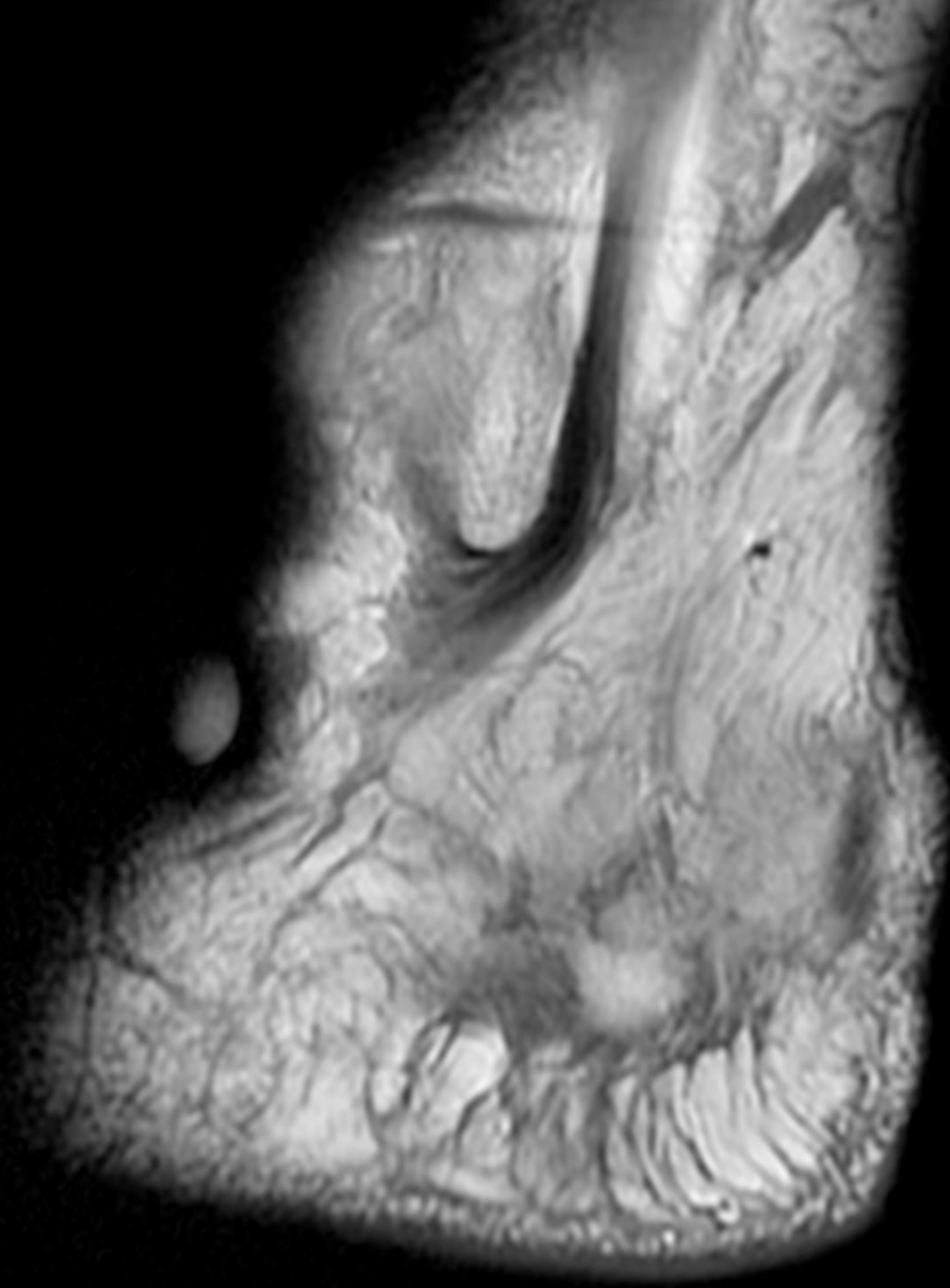
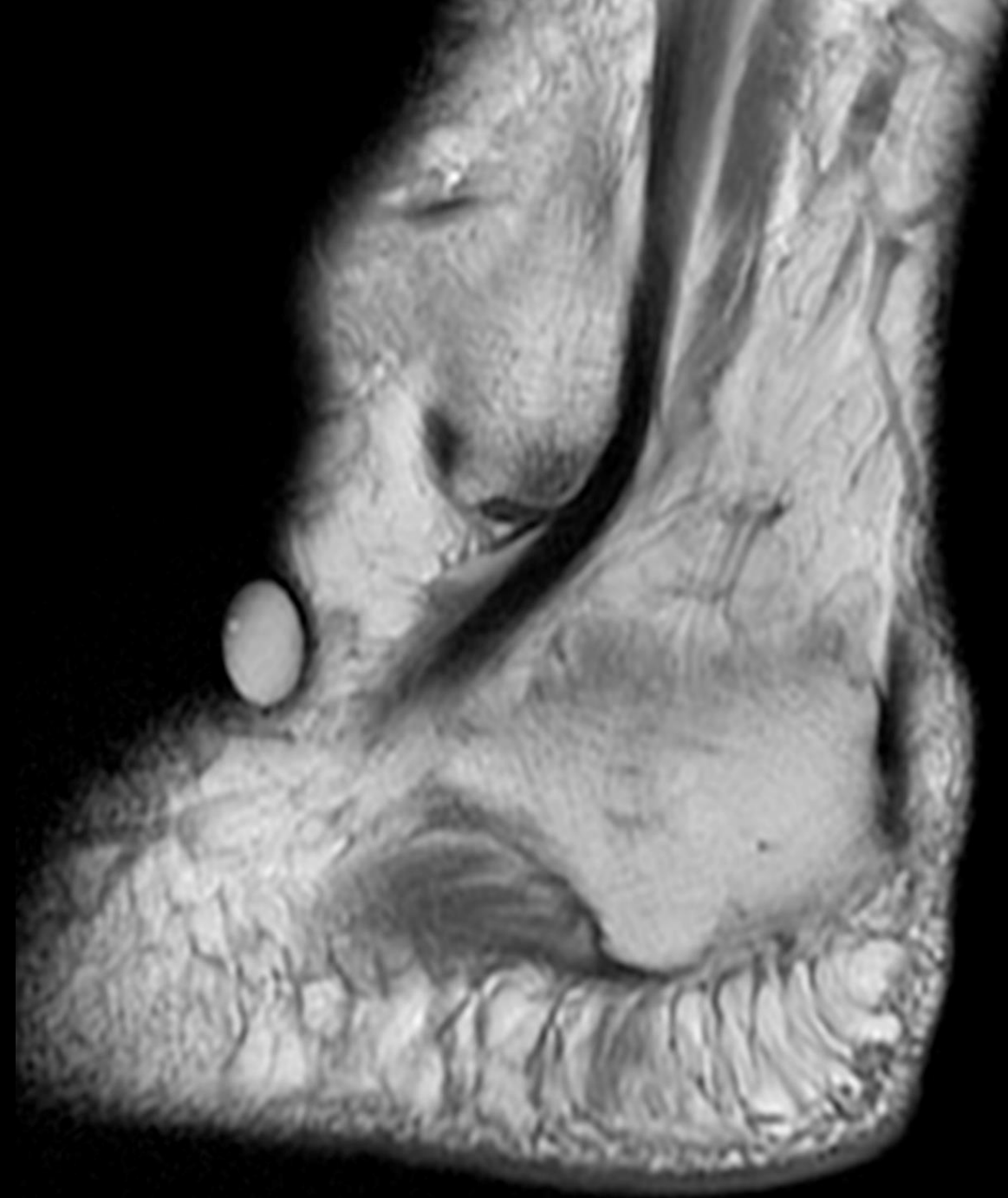- 46Yr. Patient presents with pain on the lateral aspect of the ankle. No trauma. Pain maker was kept at the site of tenderness.
- SPOT THE ABNORMALITY.





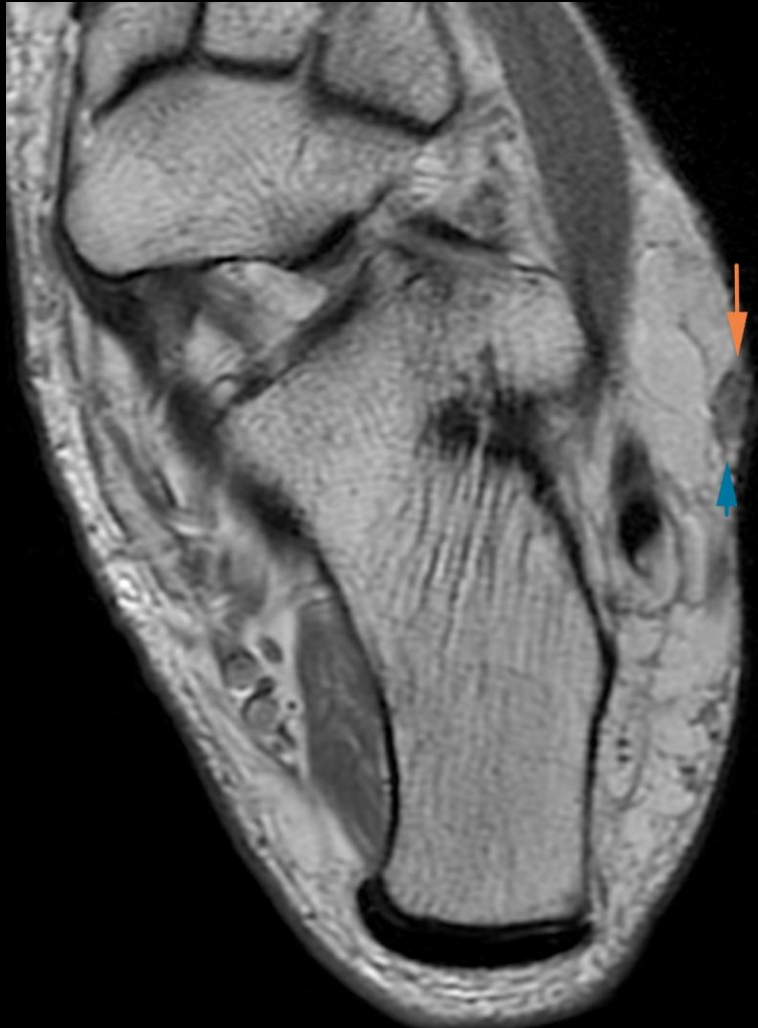




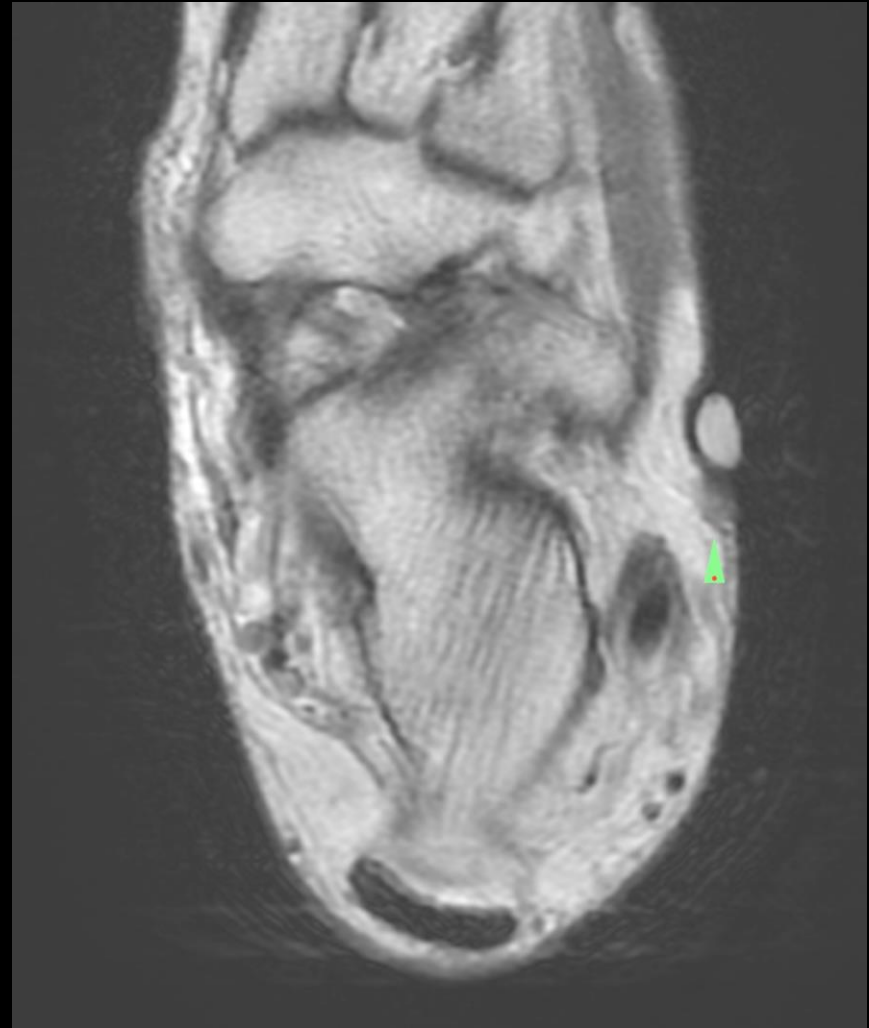
# ANSWER: NEUROMA

**IMAGE WITHOUT THE MARKER**



**IMAGE WITH THE MARKER**



# ANSWER: NEUROMA

IMAGE WITHOUT THE MARKER

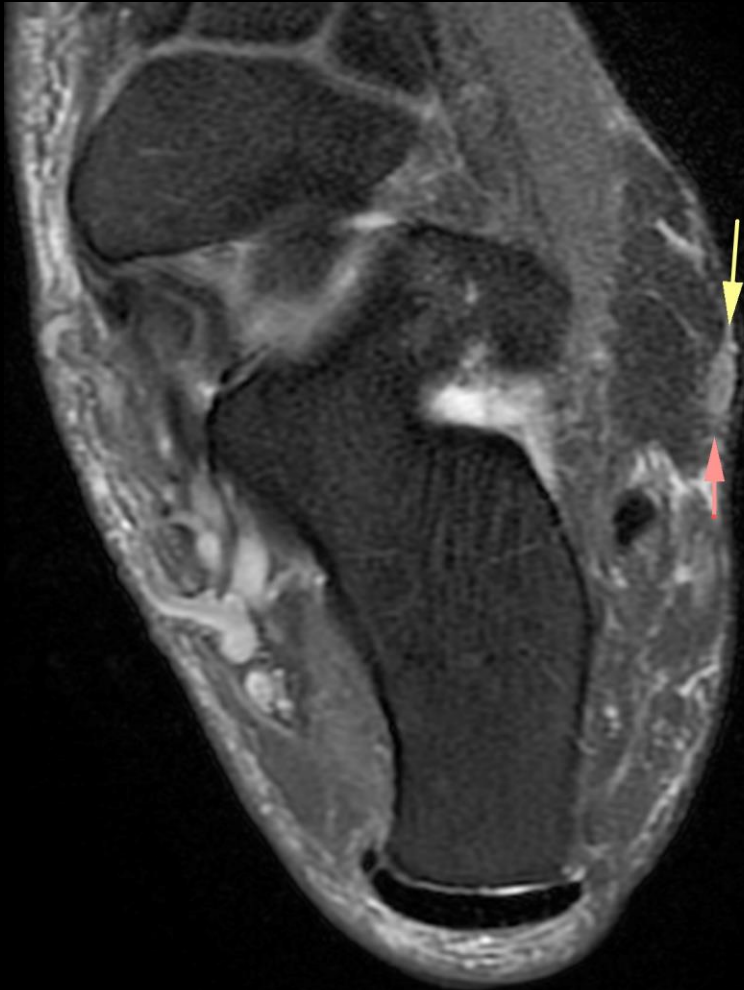
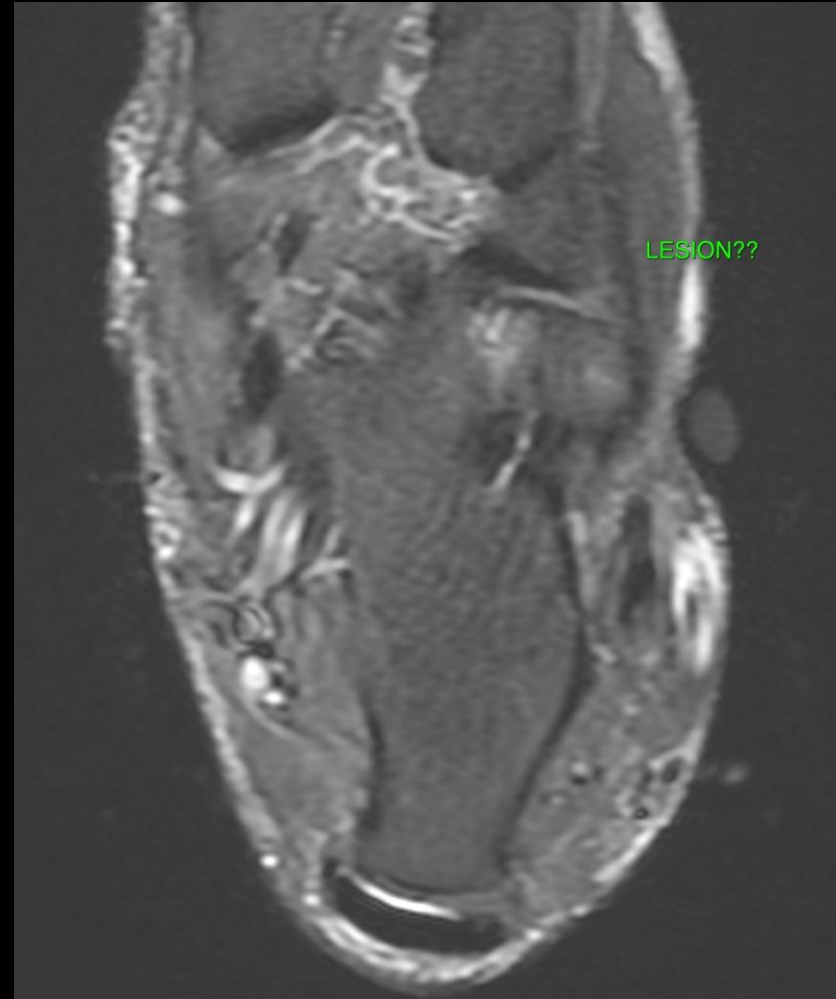


IMAGE WITH THE MARKER



# TAKE HOME POINT

- Pain markers are a must in small joint imaging.
- However, they should never be applied with pressure as it results in artifacts and obscuration of superficial pathologies.