


MICOD – 18/01/2024

Case contributor – Dr. (Prof.) Vijender Arora

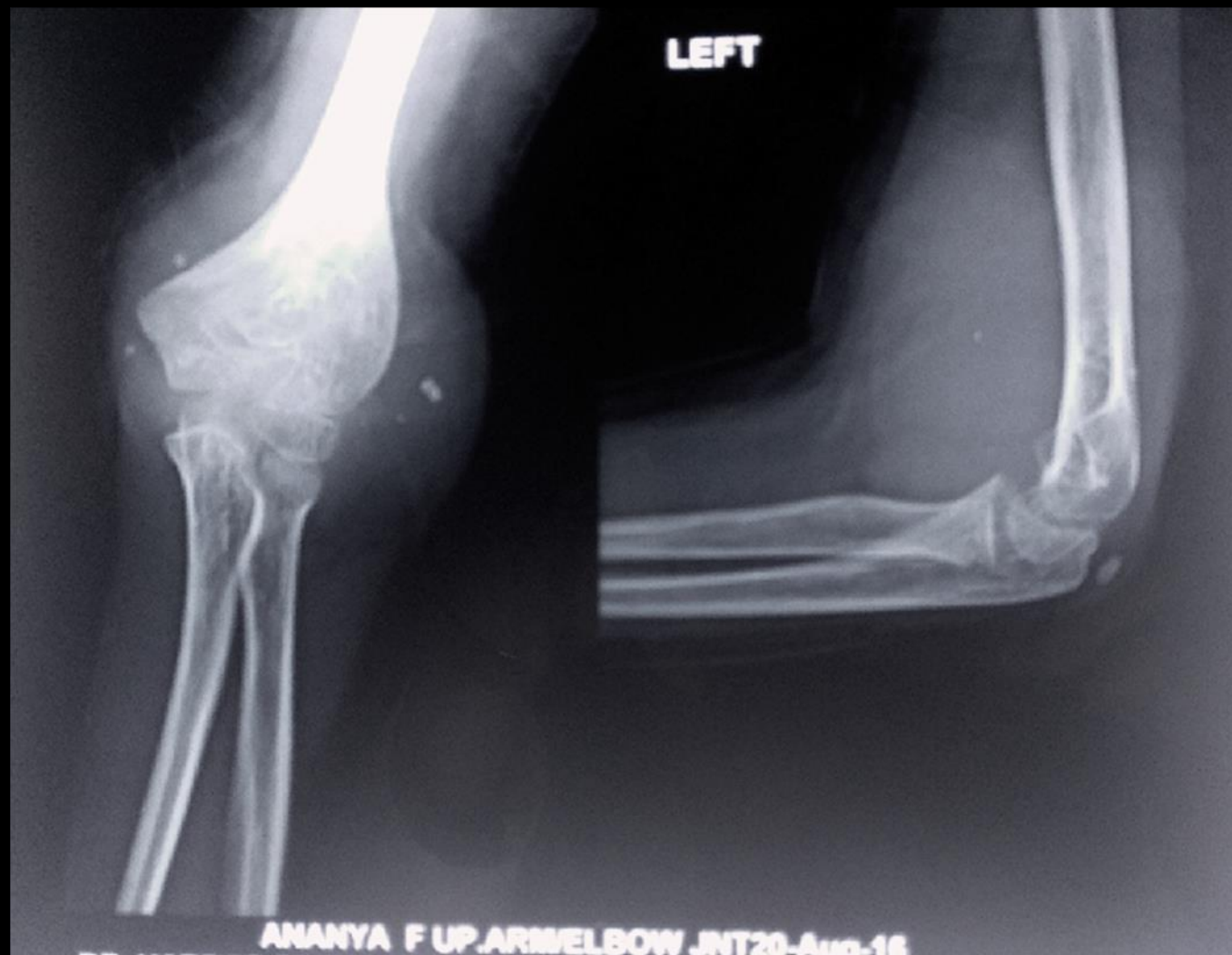
MI-COD

MSS INDIA- Case Of the Day



CASE 3

14 yrs old girl presenting with swelling of elbow for 1 yr;
now mild pain and restriction of movement



SYNOVIAL HAEMANGIOMA

- Benign vascular lesion arising from any structure lined by synovium including the intra-articular region, bursal spaces and tendon sheaths.
- Typically present in children and young adults.
- It is most commonly located in the knee, but it has also been reported in other joints including the elbow, ankle and wrist
- Occasionally patients can have recurrent haemarthroses.