


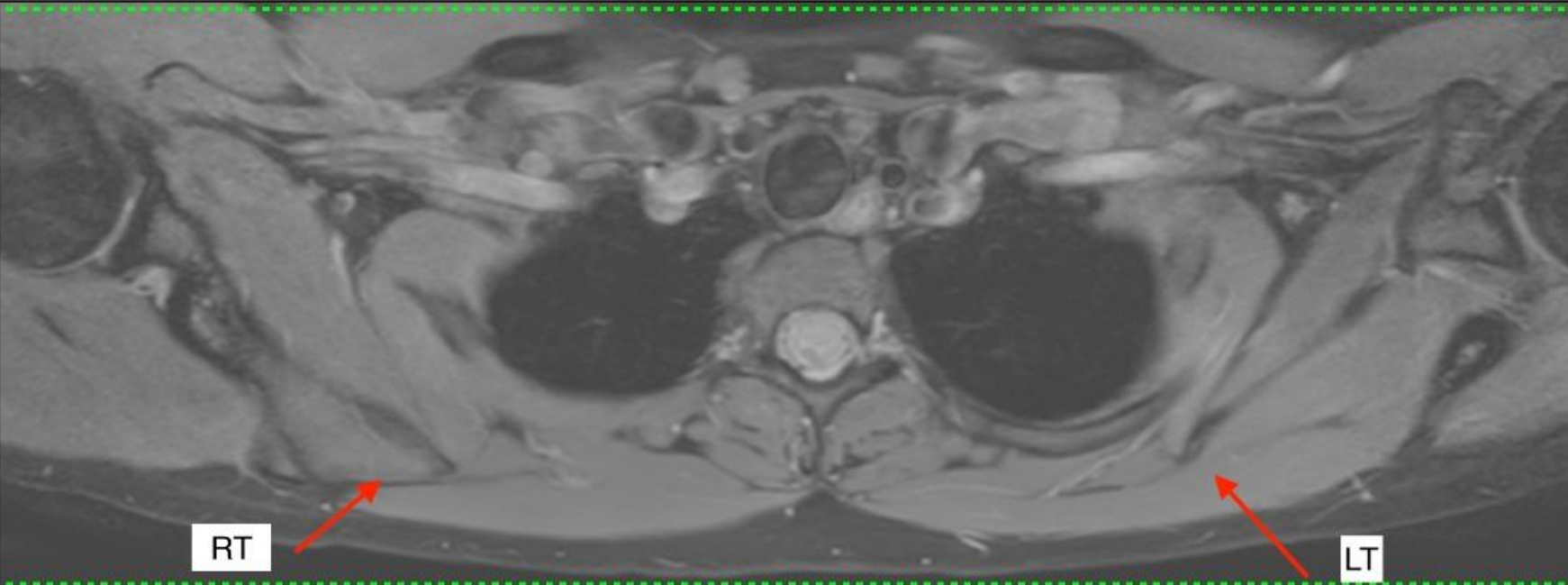
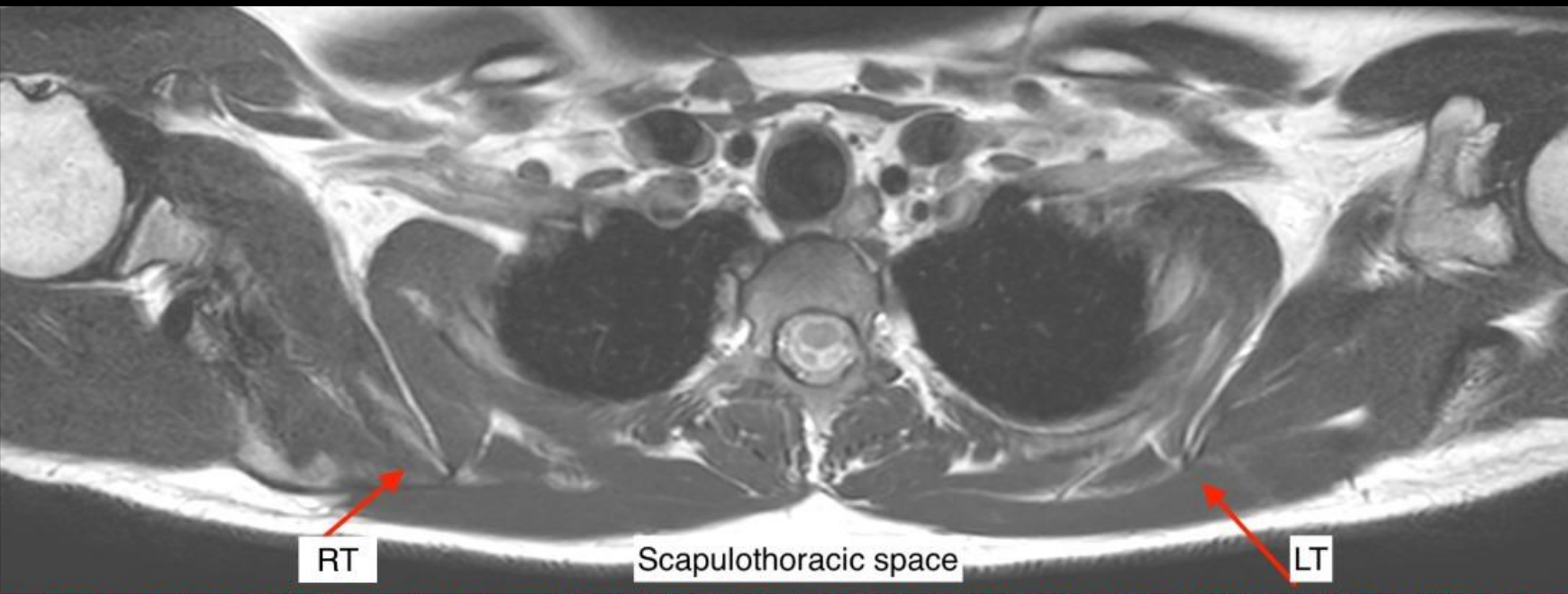
MICOD – 17/01/2024

Case contributor – Dr.Khushboo Pilonia

MI-COD

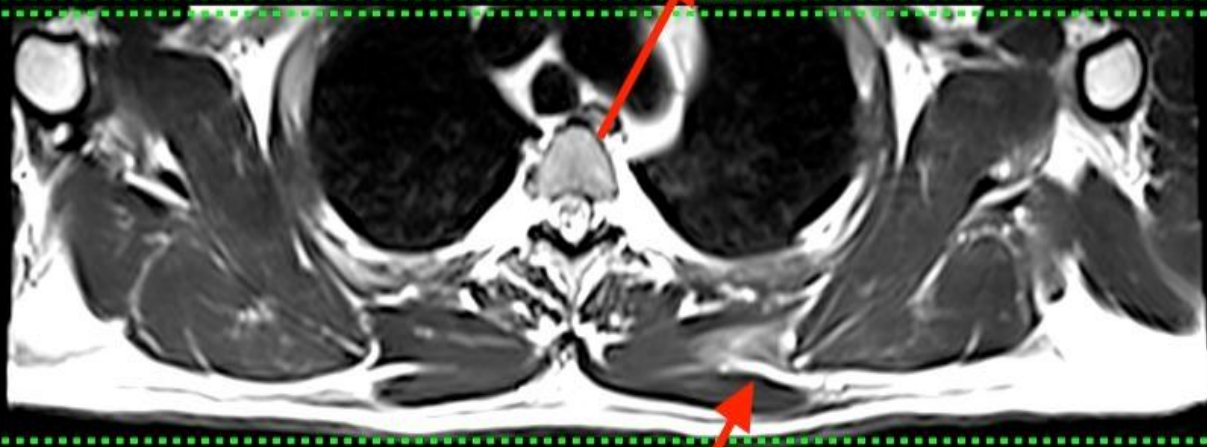
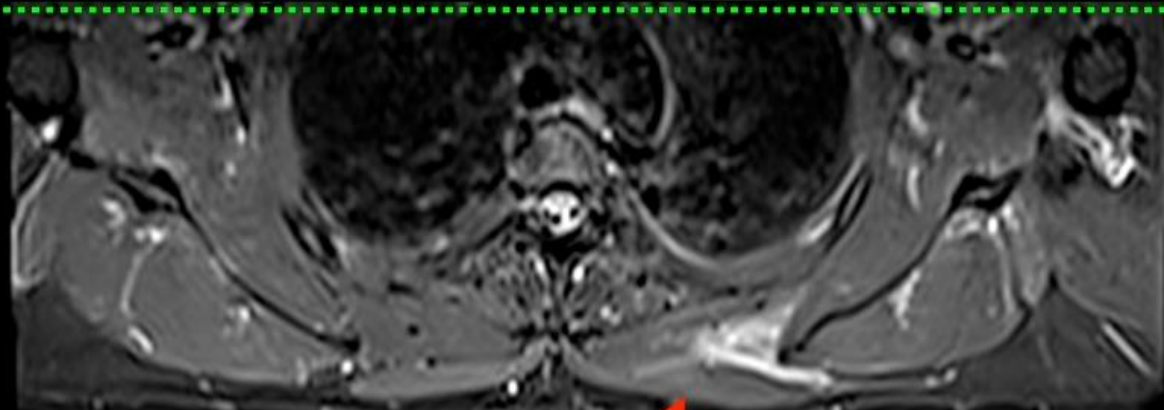
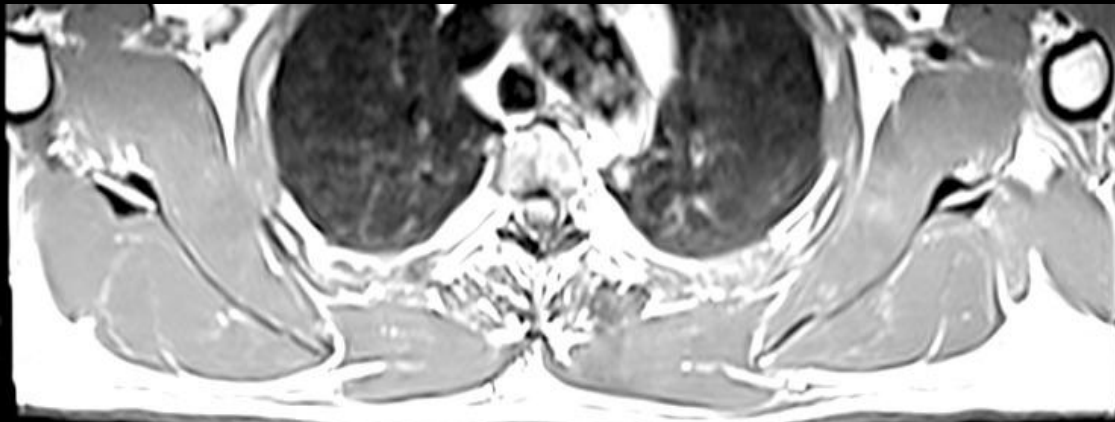
MSS INDIA- Case Of the Day





22 Year old male with left shoulder blade pain.

SCAPULOTHORACIC IMPINGEMENT



COMPANION CASE