

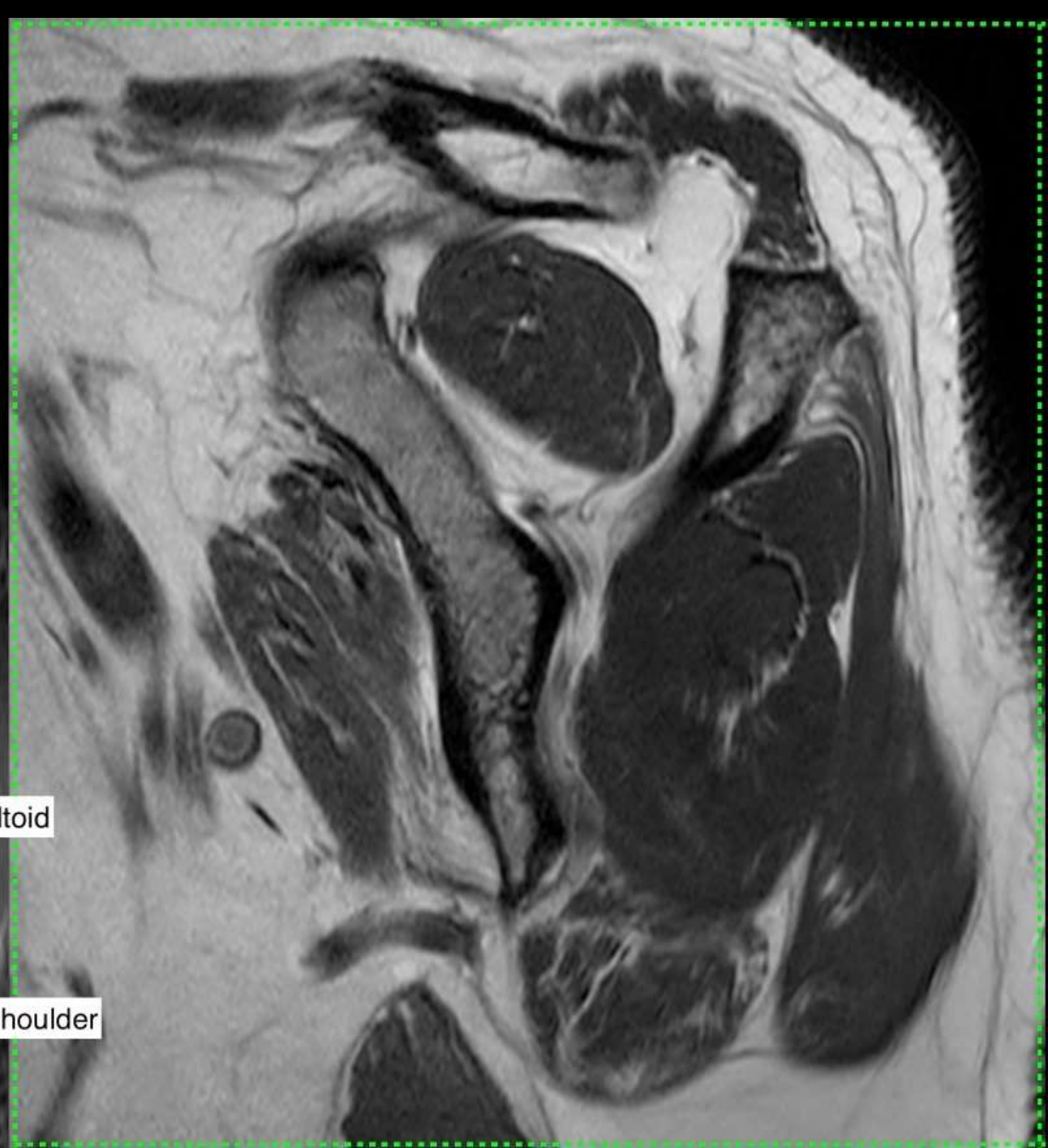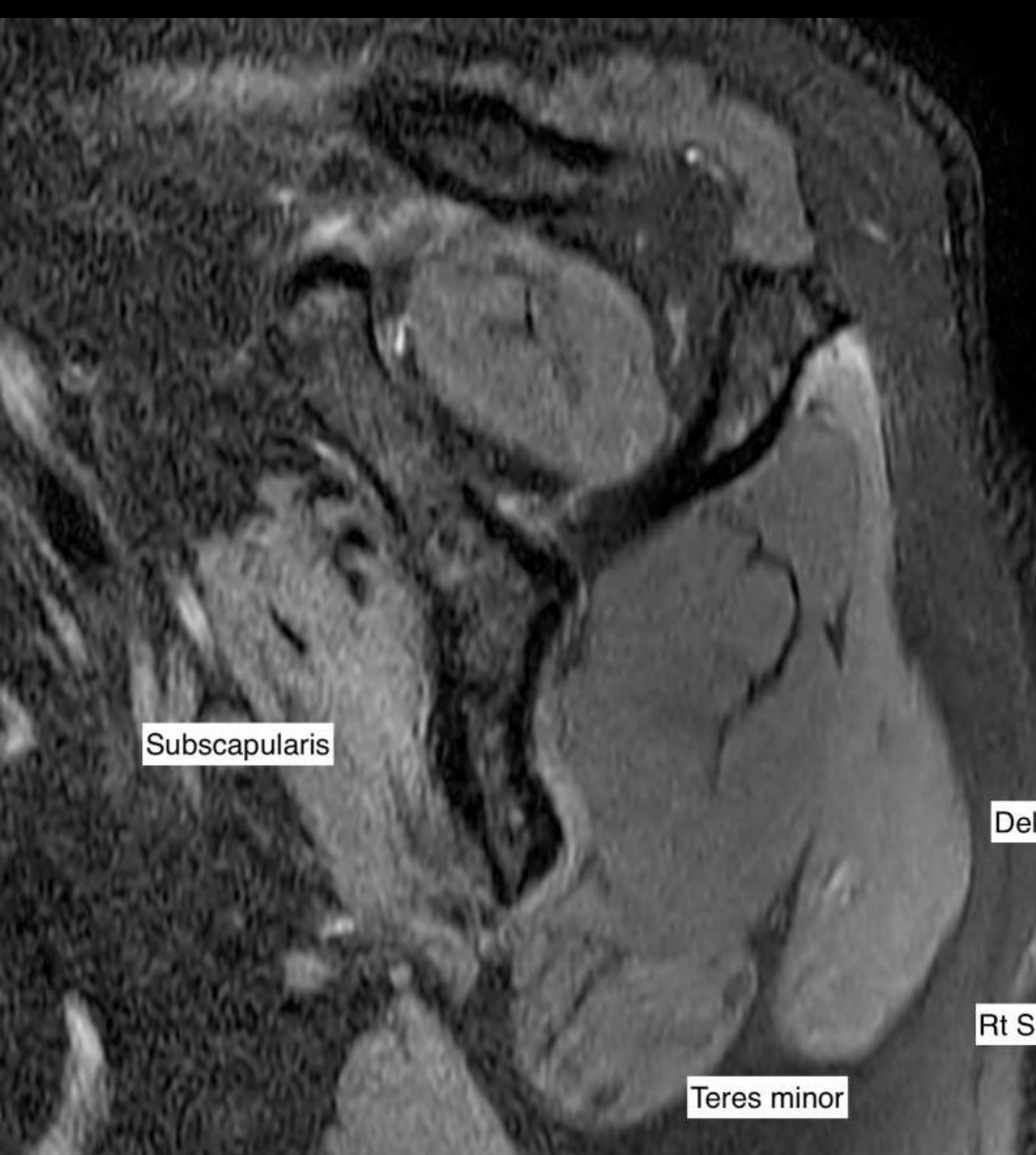
MICOD – 09/01/2024

Case contributor – Dr. Khushboo Pilania

MI-COD

MSS INDIA- Case Of the Day





Fatty atrophy and edema in subscapularis, teres
minor and deltoid
Likely due to denervation

Parsonage Turner Syndrome