

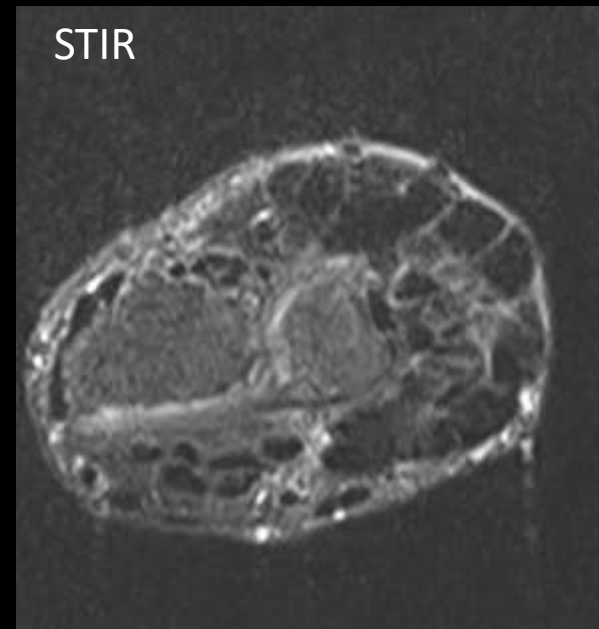
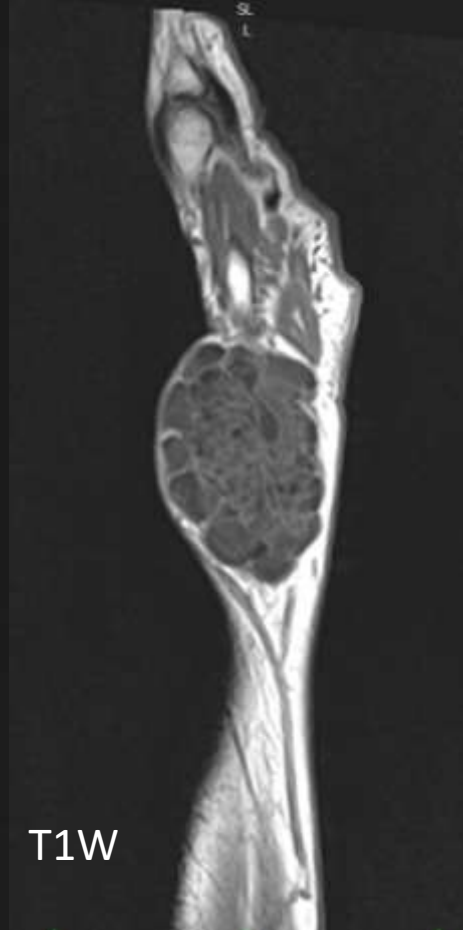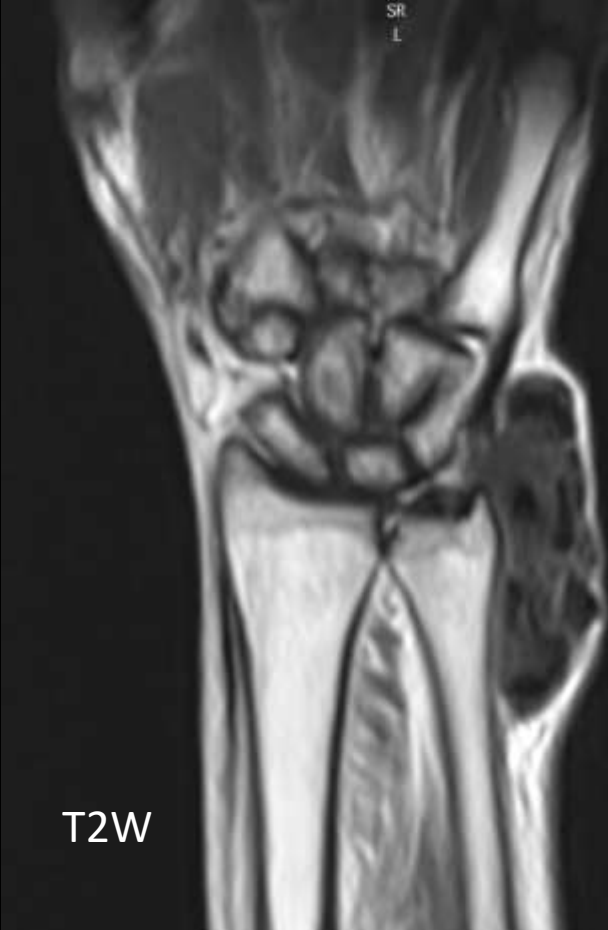
MICOD – 05/01/2024

Case contributor – Dr. Ankur Shah

MI-COD

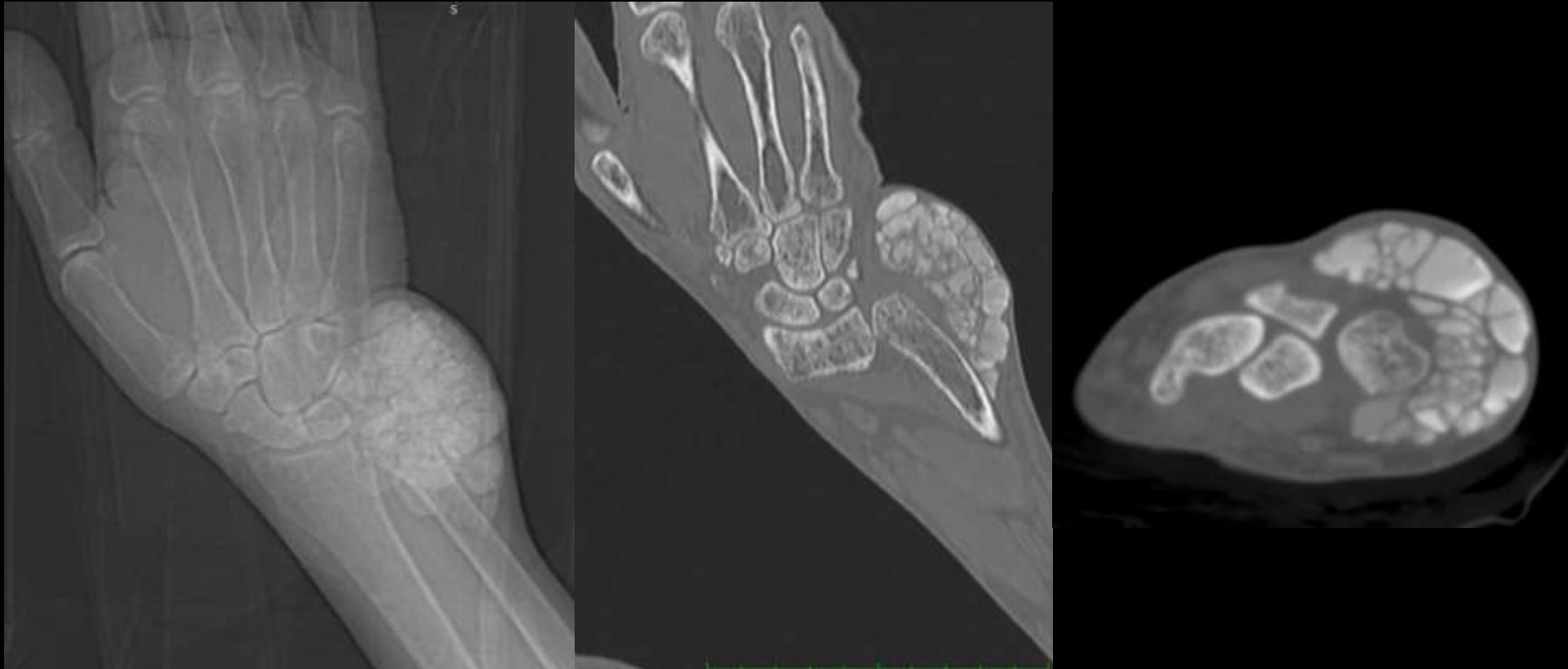
MSS INDIA- Case Of the Day





55 year male with swelling
No history of trauma
No family history of similar complaint
Patient is on Dialysis for Renal failure

Answer



Answer

- Calcinosis of chronic renal failure
- D/D – Tumoral calcinosis - A rare familial disorder with painless periarticular calcified mass