

MICOD – 04/01/2024

Case contributor – Dr. Shayeri Roy Choudhury

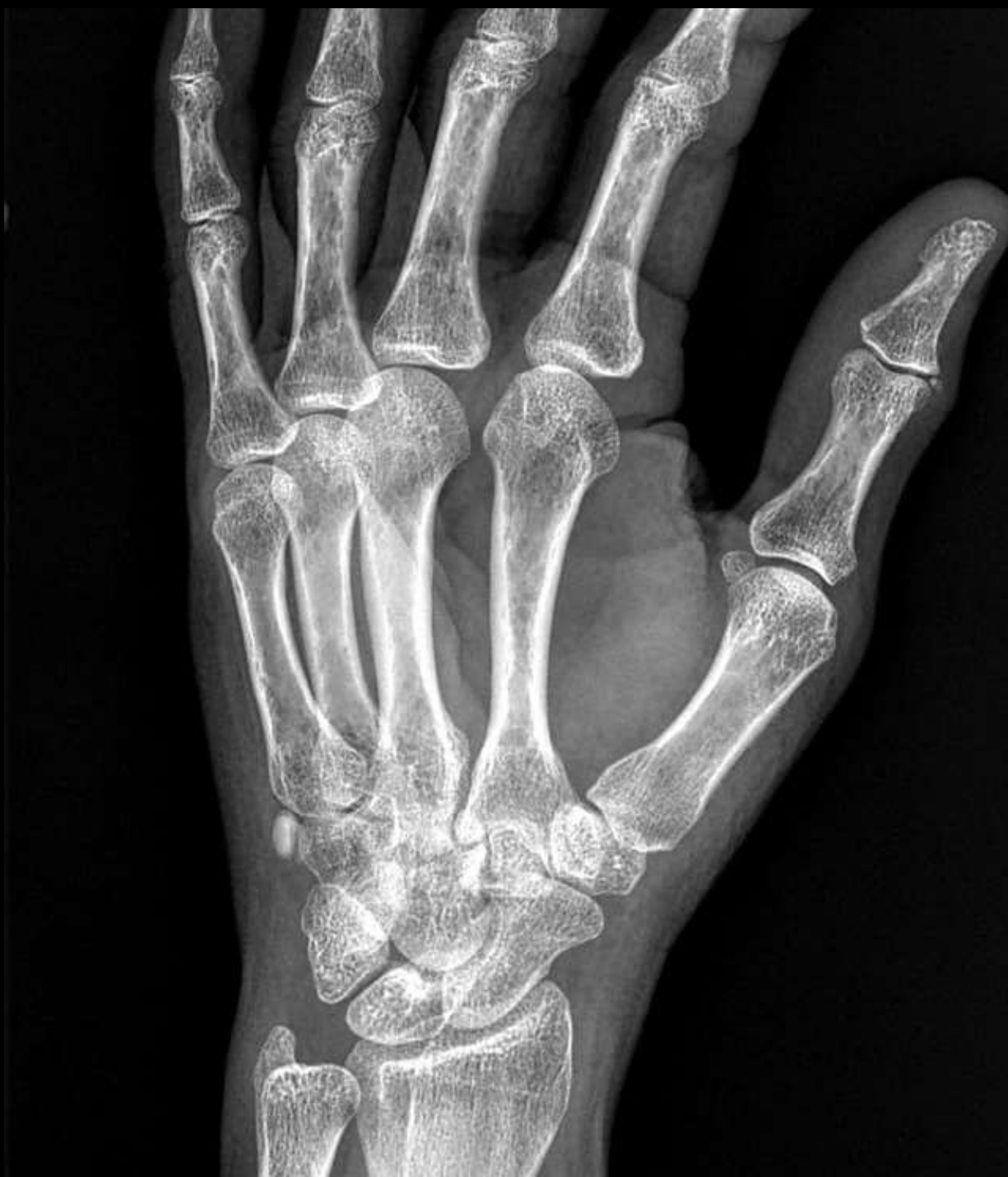# MI-COD

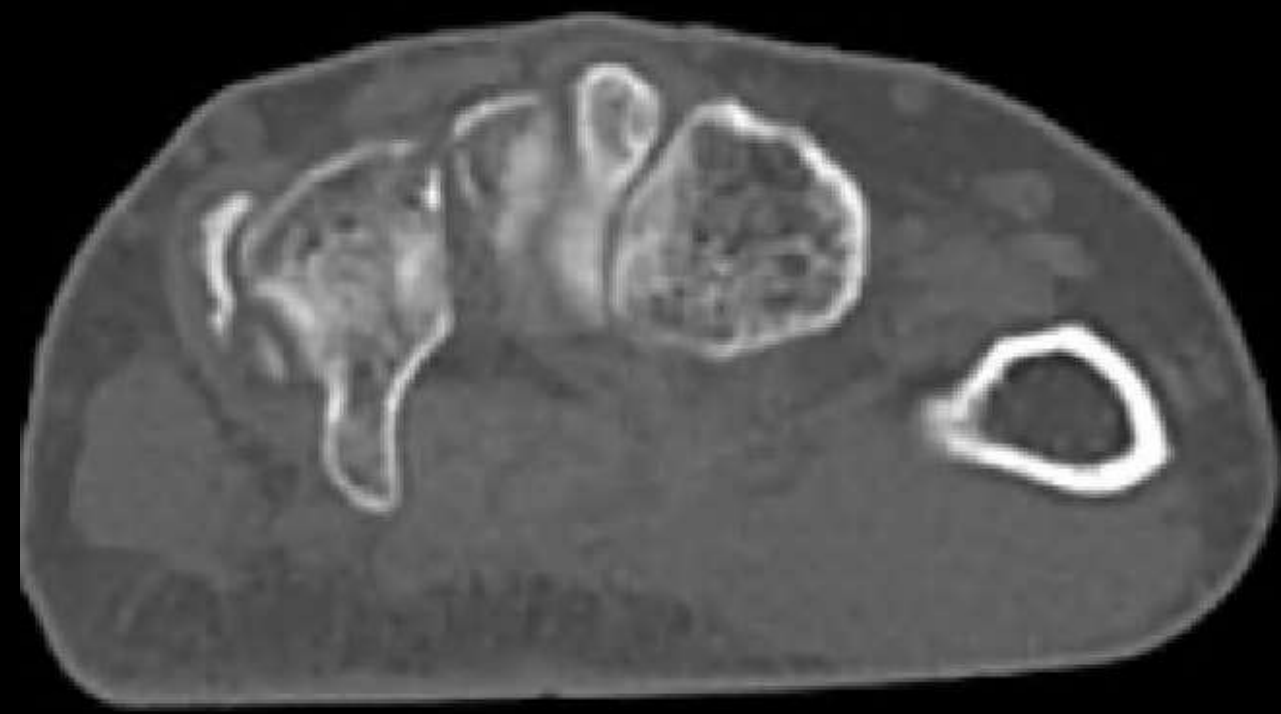
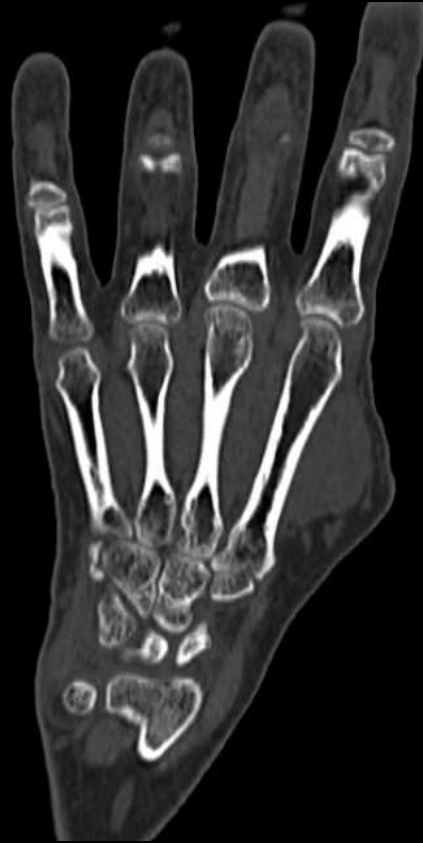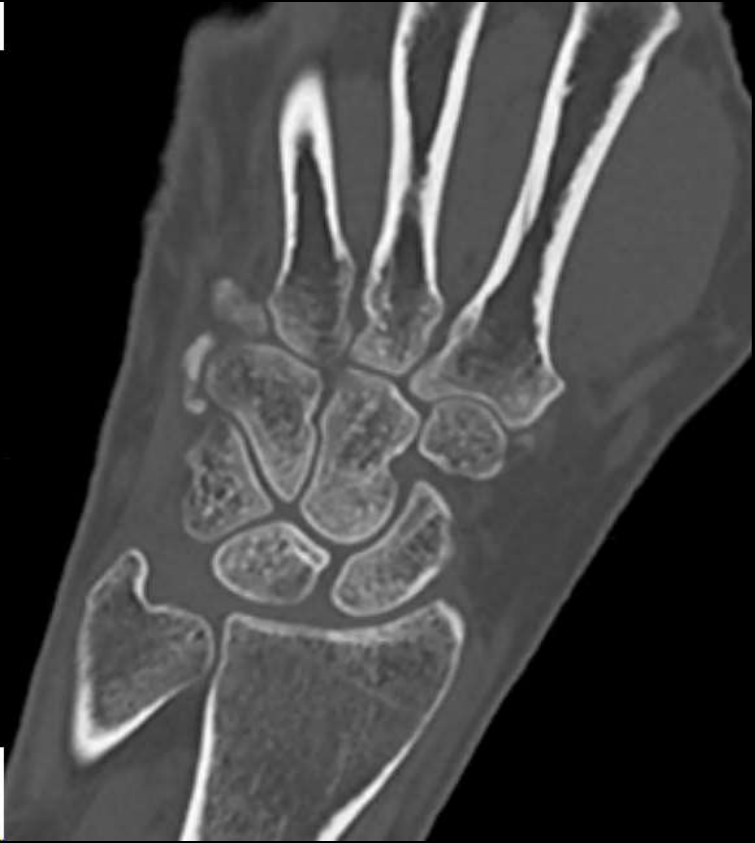MSS INDIA- Case Of the Day



# CLINICAL HISTORY

- 50 y/female
- 1 month history of pain along the ulnar aspect of palm
- No history of trauma





# Acute calcific periarthrititis

- A self limiting mono-articular peri-articular calcification
- Most commonly occurs in shoulder – HADD. Other joints like hip and knee are also involved
- Hand and wrist – less common, usually the tendon of flexor carpi ulnaris at its insertion may be involved, or the MCP joints.
- Clinically presents as painful swelling, redness and tenderness.
- Laboratory workup is normal
- Commonly in patients between 40-70 yrs of age, females more common (especially perimenopausal women; and in the hand and wrist)