

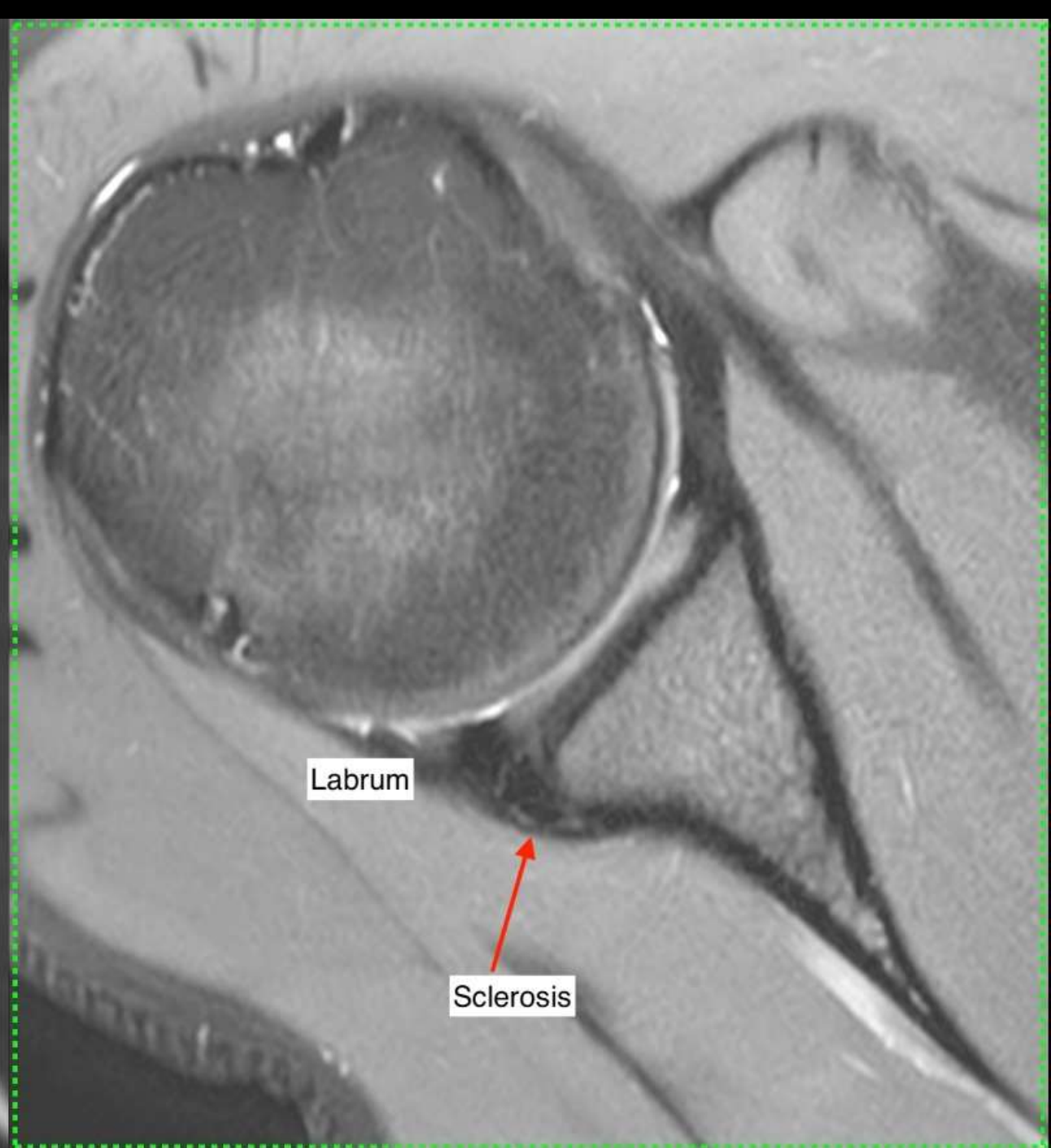
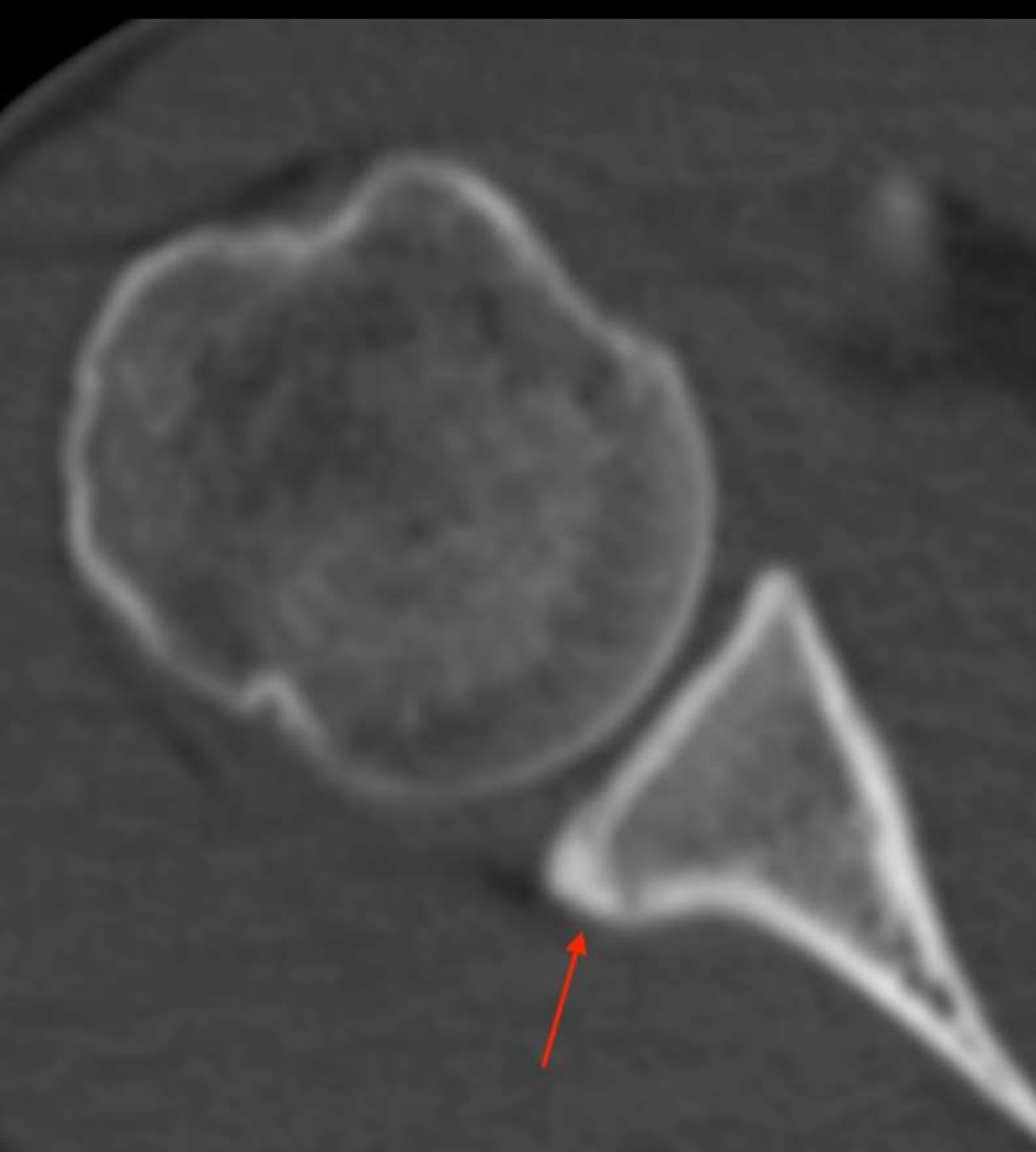
MICOD – 02/01/2024

Case contributor – Dr. Khushboo Pilania

# MI-COD

MSS INDIA- Case Of the Day





Posterior gleno-humeral instability

Rounding of posterior glenoid with sclerosis

Posteroinferior glenoid labral tear