

**MICOD 27.12.2023**  
**Contributor - Dr. Abhimanyu Kelkar**

**MI-COD**

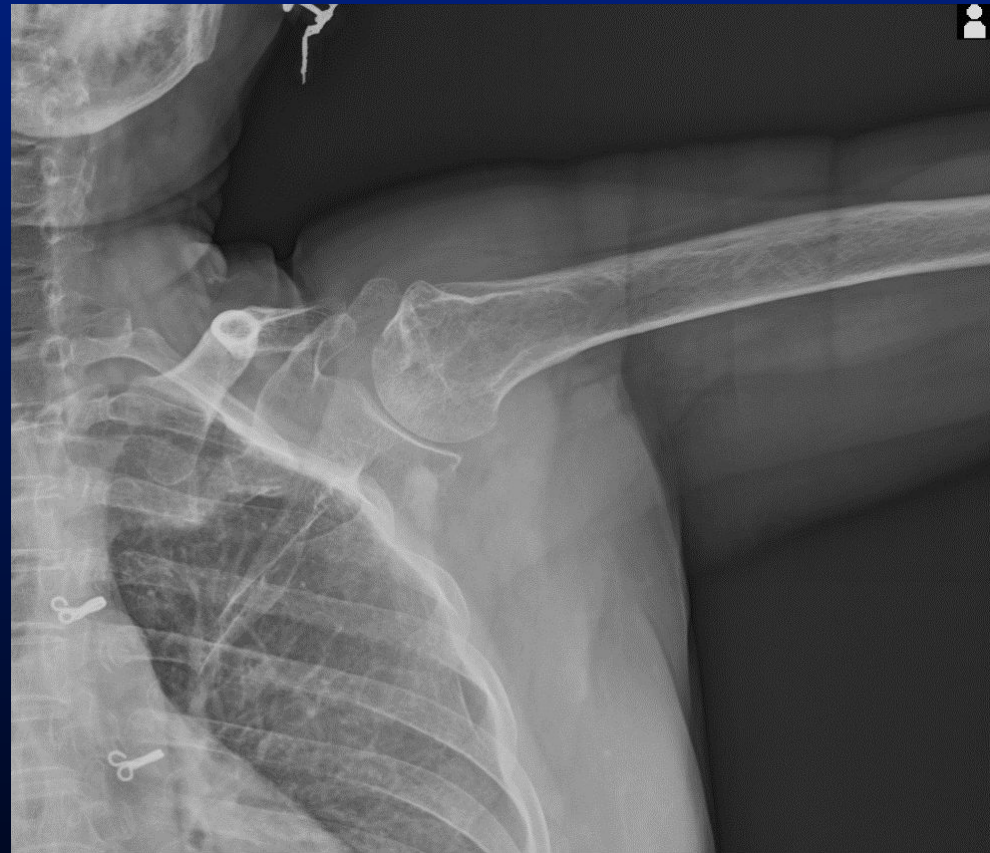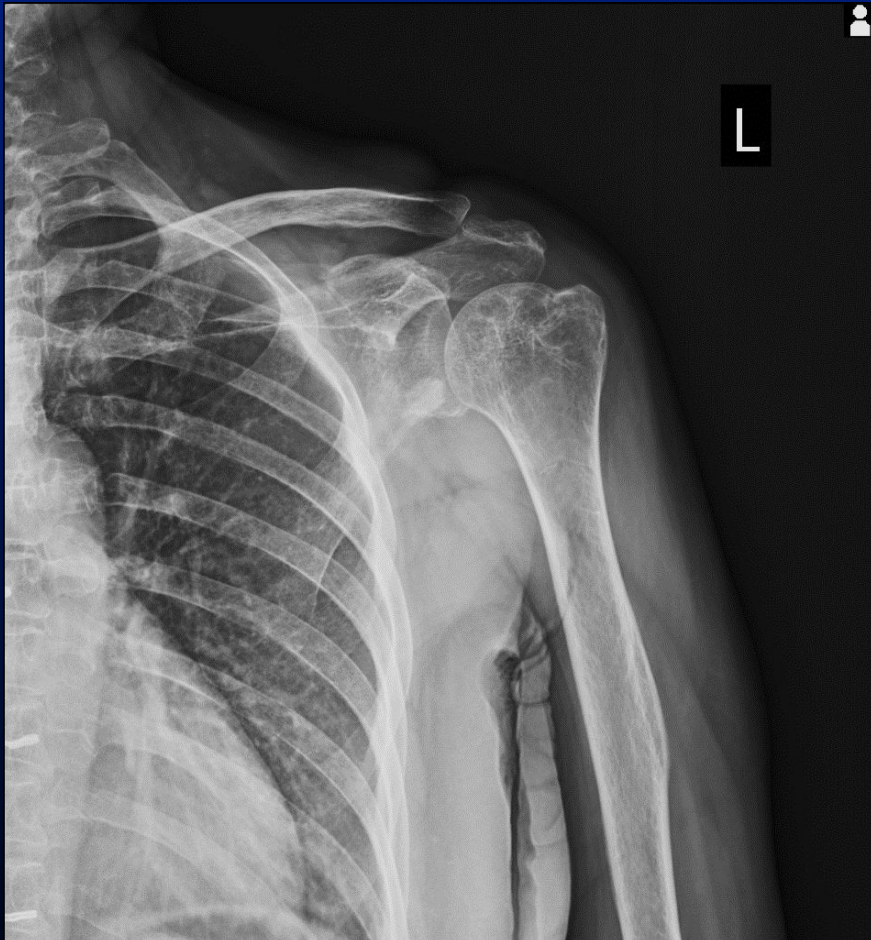
MSS INDIA- Case Of the Day



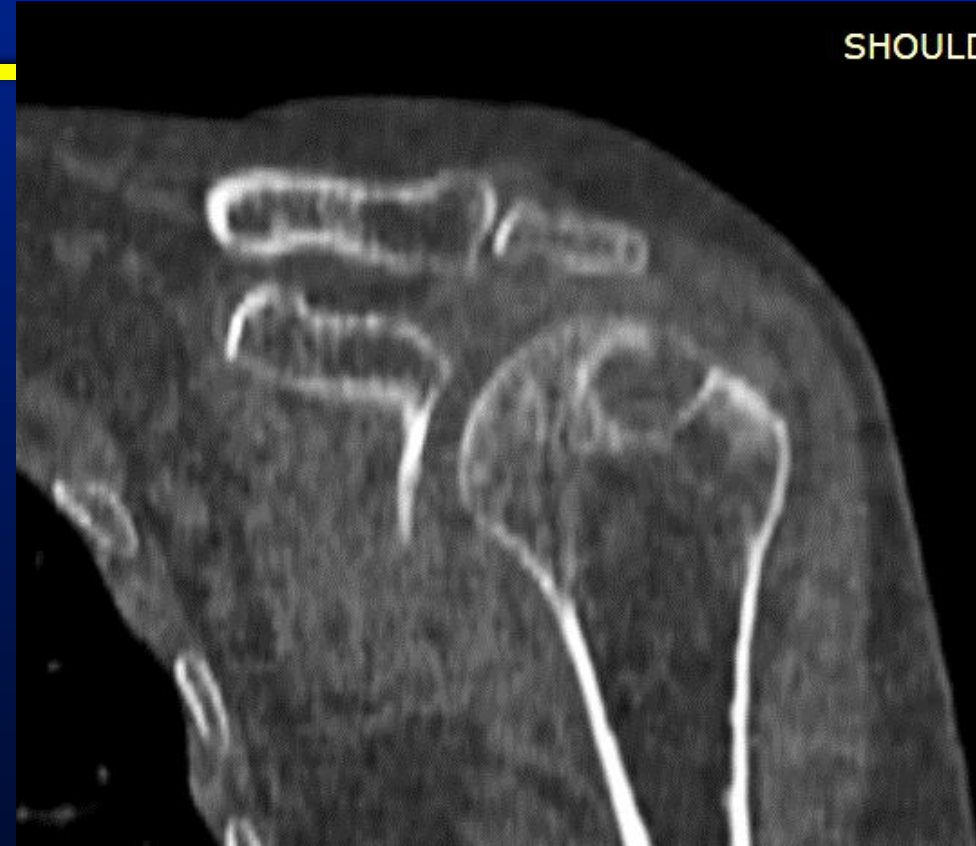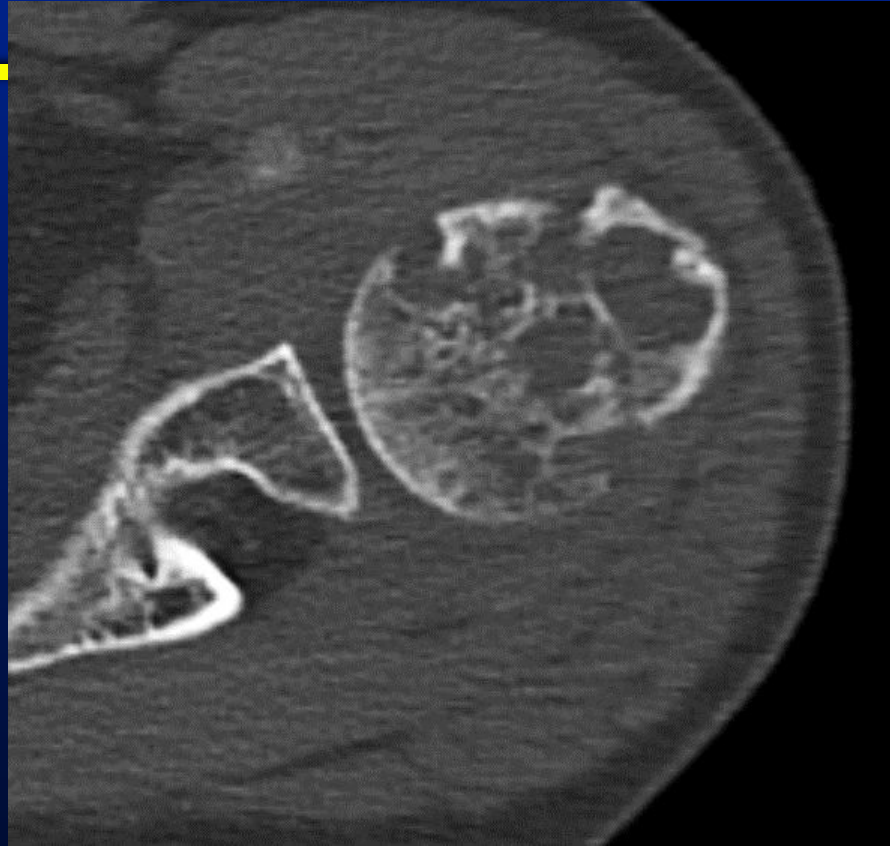---

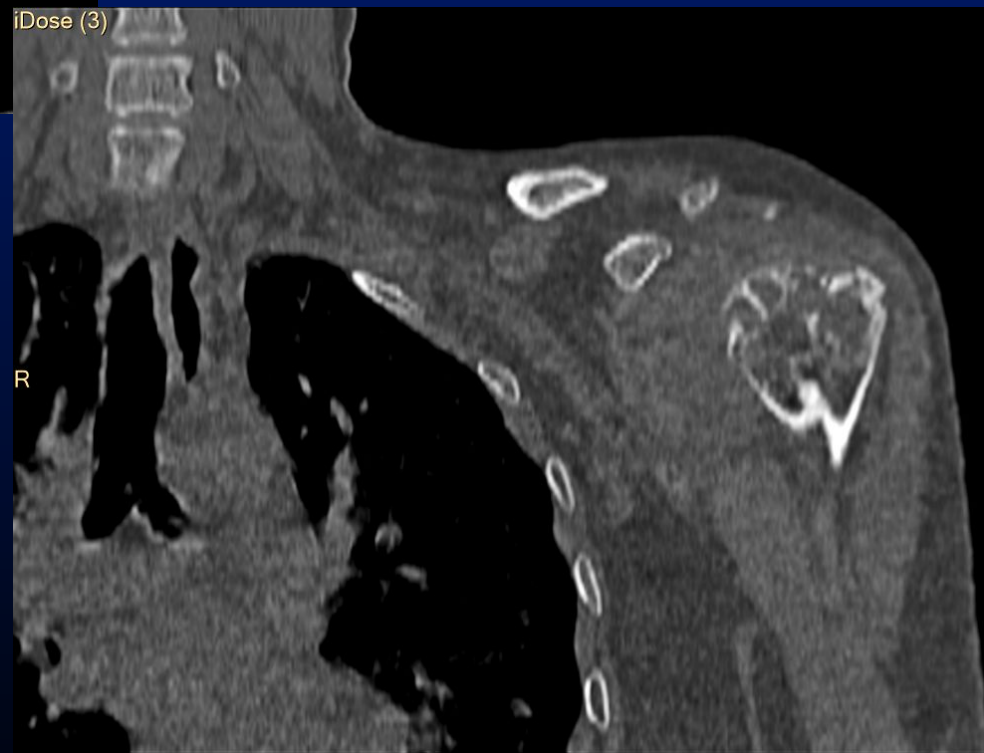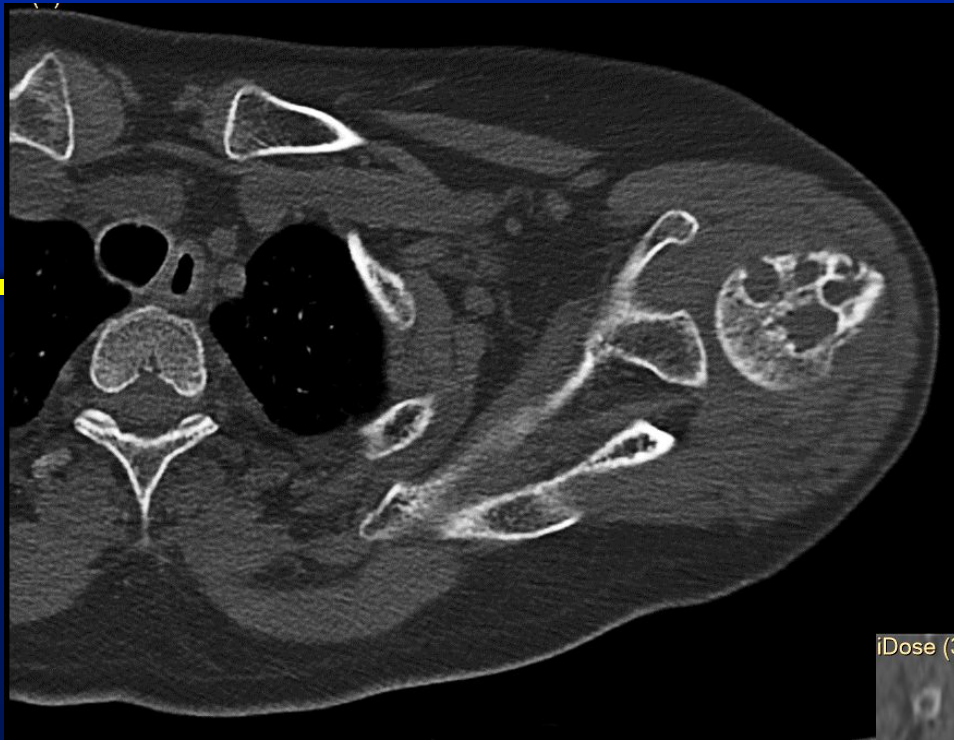58 yr old lady, shoulder pain and  
restriction of movements  
Clinically, Adhesive capsulitis

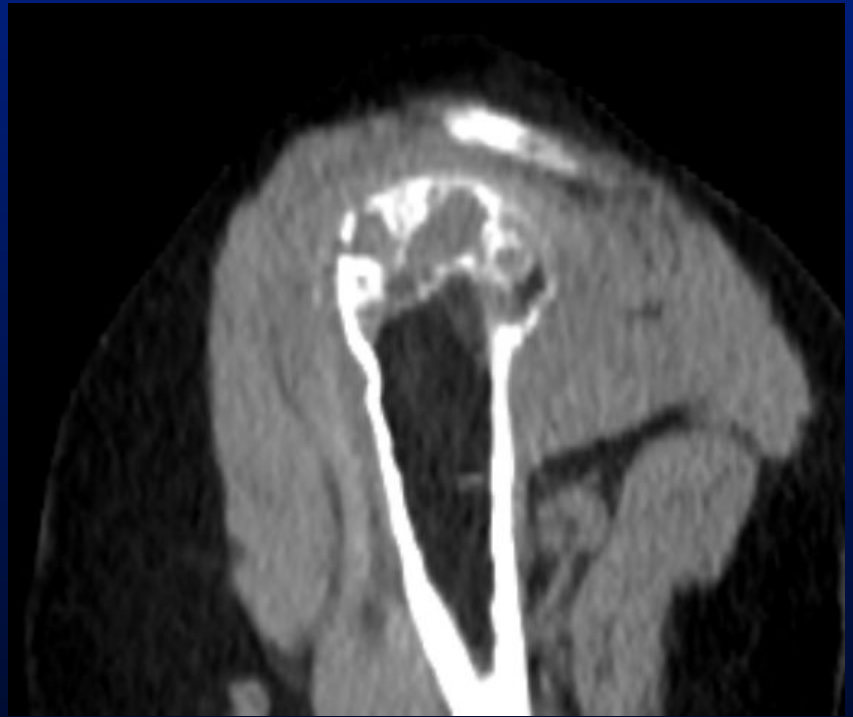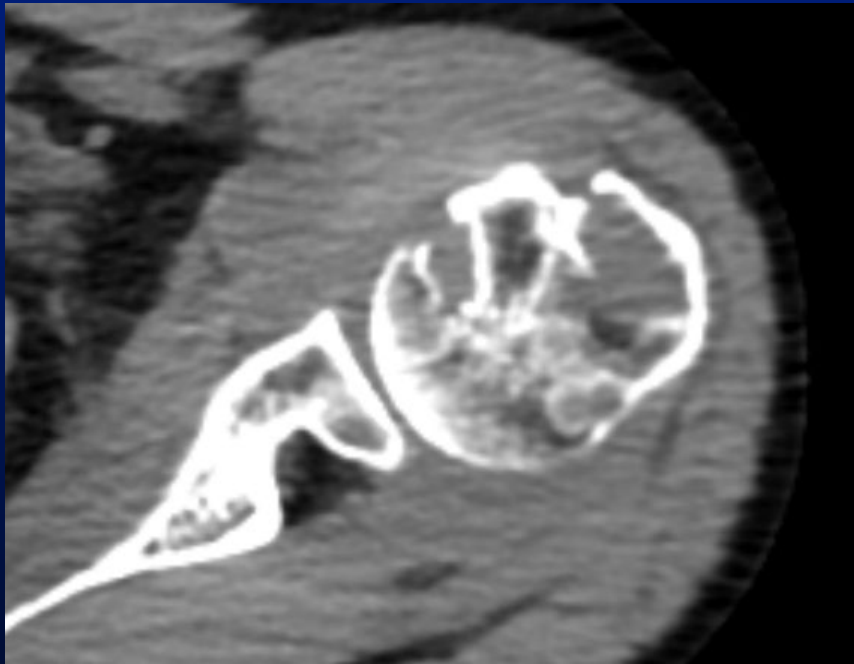
# Multiple lytic lesions in humeral head



# CT



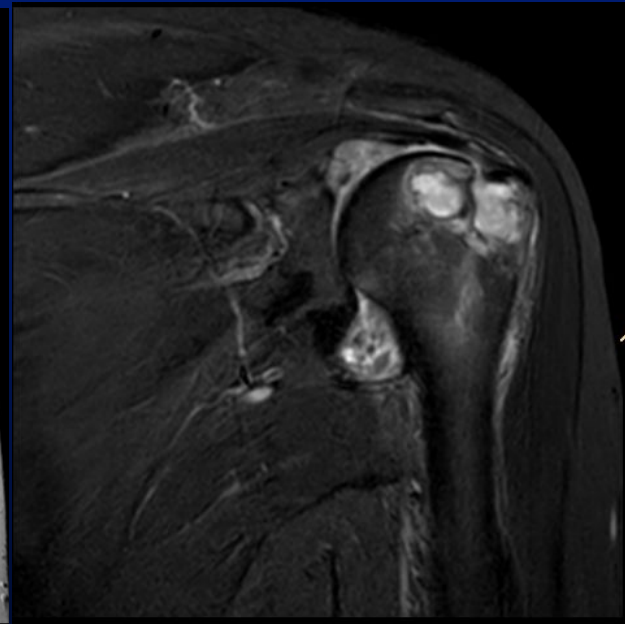
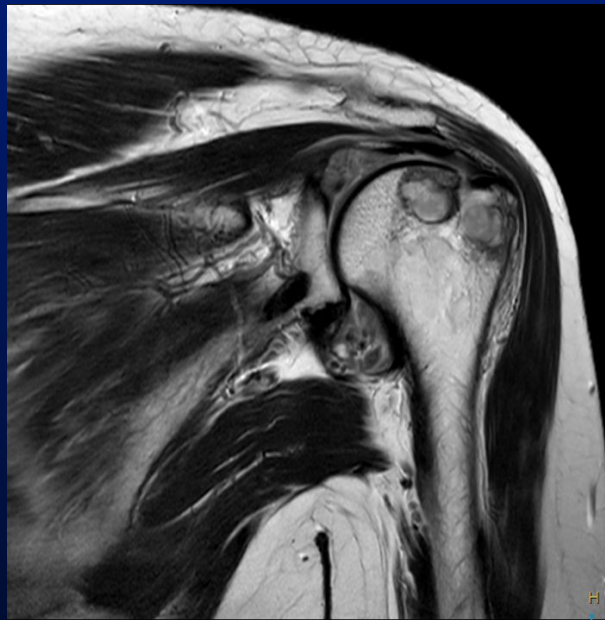
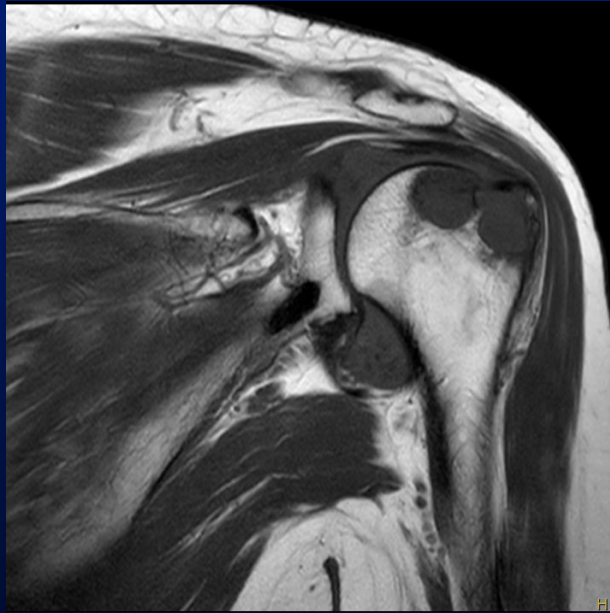


- 
- ❖ At this stage we can ask differentials and then show MRI pre and post contrast
  - ❖ We can also ask whether MRI would give additional information.

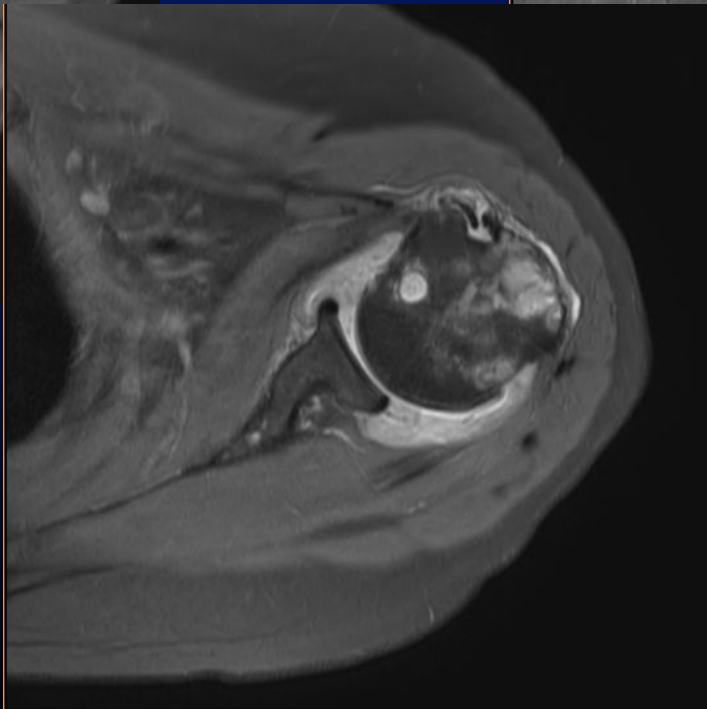
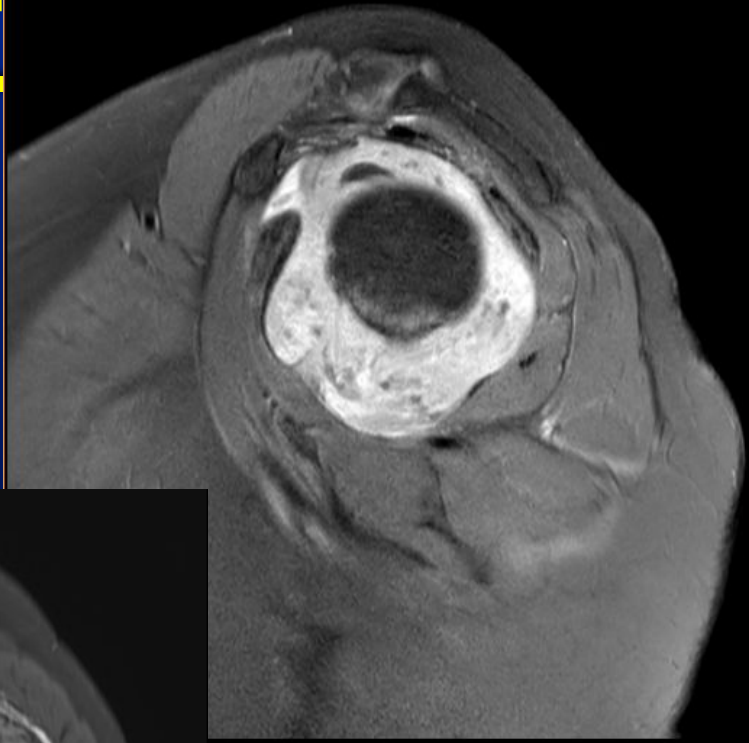
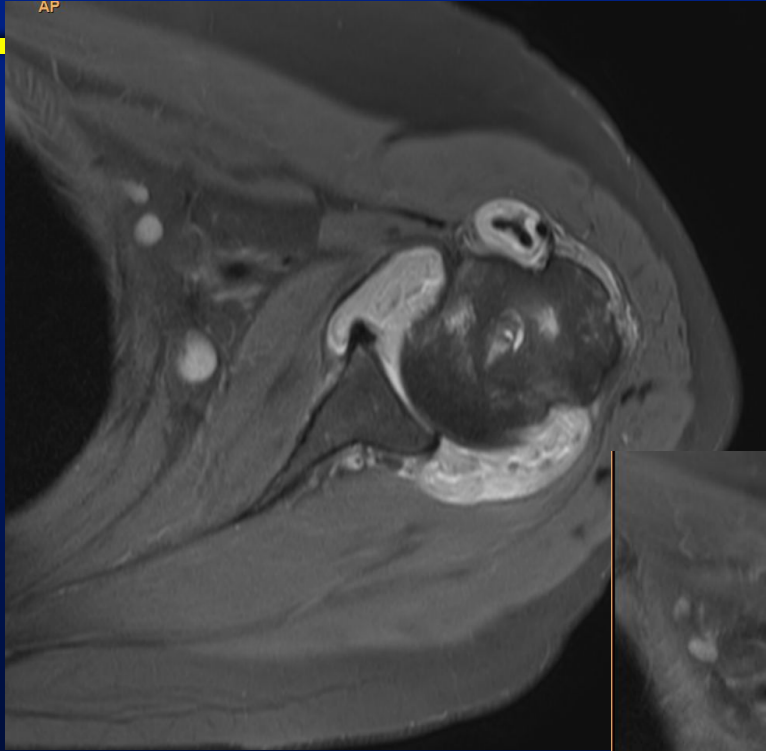
# T1, T2, STIR

---





# Post Gad



# Findings

---

- ❖ Severe synovitis
- ❖ Rice bodies
- ❖ Humeral sided erosions. Intact glenoid side.

On inquiry, patient agreed intermittent swelling of small joints of hand

---

Parameter	26/10/2023
ANTI CCP	POSITIVE
RA Factor	POSITIVE
CRP	15

Diagnosis-RA

# Teaching points

---

- ❖ Erosions too large for inflammatory synovitis.
- ❖ Involvement of only one side of the joint
- ❖ Can be mistaken for aggressive lesions like mets, myeloma