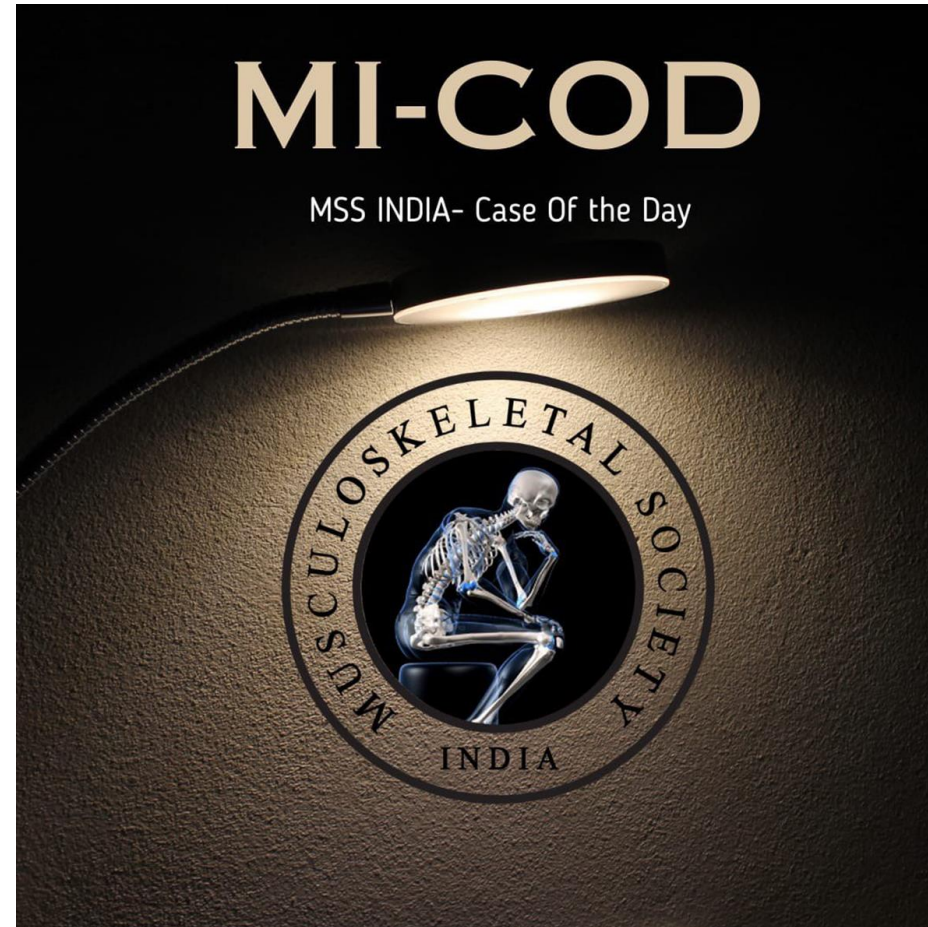
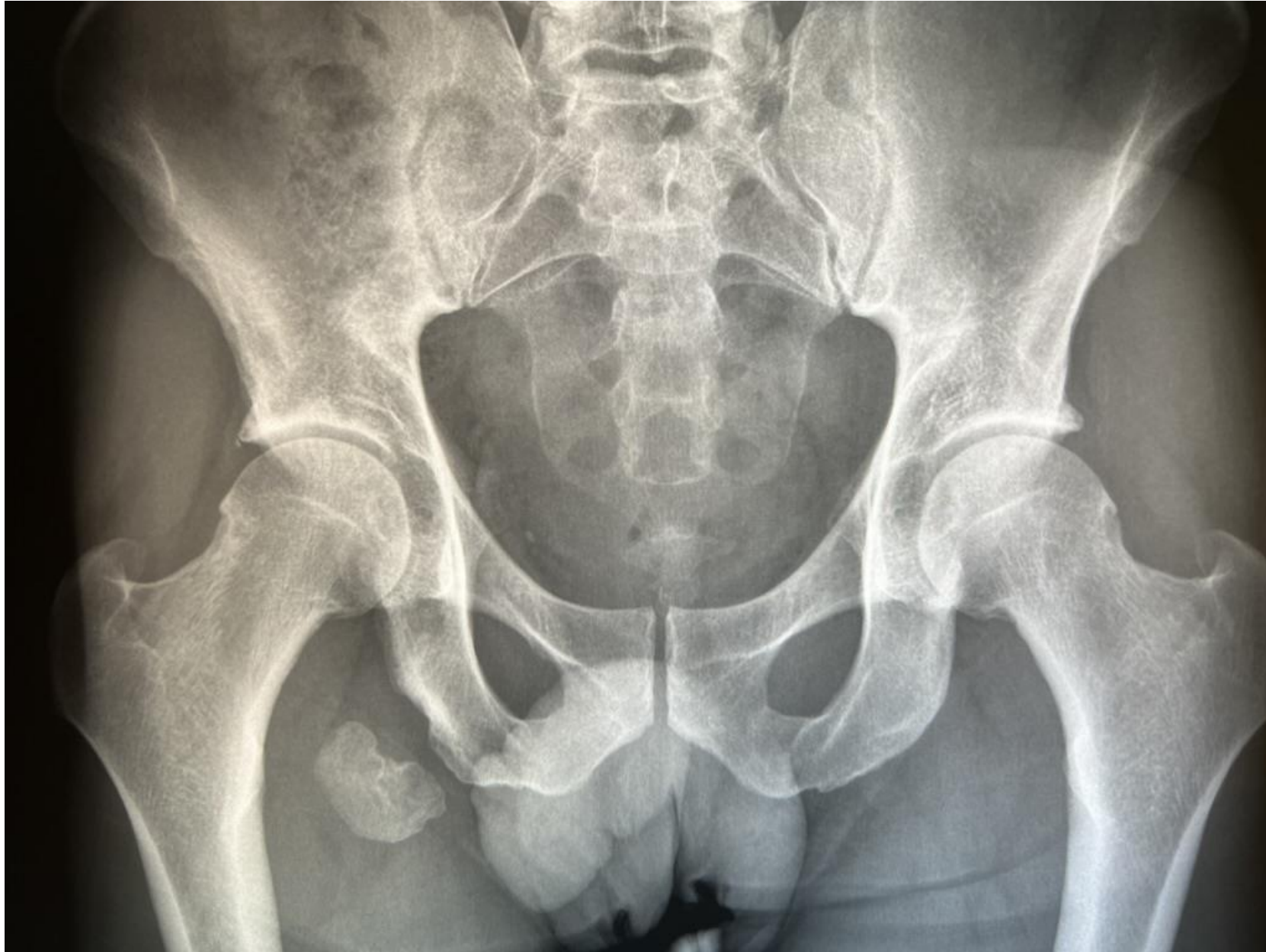

MICOD – 25.12.2023

Case contributor – Dr. Harun Gupta



35 yr M hip pain



35 yr M hip pain



# Answer

- Further history - Injury at age 15 and avulsion of right ischial tuberosity hamstrings origin

Above now seen as an ossific fragment separate and in course of healed hamstring fibres with residual changes.

Case also shows how the ossific fragments can grow over time !

Videos  
in  
Answer

